

Open comedones overlying granuloma annulare in a photoexposed area

Emilio Sudy¹, Francisco Urbina¹, Ximena Espinoza²

¹Unidad de Dermatología Occidente, Universidad de Chile, Chile and ²Vida Integra

A 57-year-old, fair-skinned female patient with lesions of granuloma annulare located on her forearms – with signs of actinic damage – is described. No response was observed after successive treatments with topical corticosteroids and oral pentoxifylline. Four years later, the patient developed open comedones on the rim of granuloma annulare lesions. The loss of elastic fibers seen in both granuloma annulare and solar elastosis is presumed to have induced the appearance of open comedones, because of a loss of supporting properties of the dermis inducing a distension of the infundibular canal of the sebaceous follicle, as seen in the

Solar or senile comedones are a relatively common finding among elderly patients (1) who have had prolonged exposure to solar radiation, inducing pilosebaceous ducts to become distended. In extreme cases, a condition called the *Favre–Racouchot* syndrome occurs, consisting of giant comedones, pilosebaceous cysts and a wrinkled, yellowish skin, especially around the eyes and cheeks.

On the other hand, granuloma annulare is a dermatosis of unknown origin characterized by localized and generalized forms of necrobiotic granulomas. A variant of granuloma annulare called actinic granuloma is an unspecific condition whose origin has been related to sun damage. Clinically, it consists of erythematous, annular lesions with raised margins, mainly located in sun-exposed areas.

To our knowledge, the association of open comedones overlying granuloma annulare has not been reported previously, and suggests a common pathogenic mechanism related to sunlight.

Clinical report

A 57-year-old white, fair-skinned woman presented with a 2-year history of progressive annular lesions located on both forearms. When first seen, multiple erythematous annular lesions 1–4 cm in diameter were observed on the dorsal aspect of her forearms, pre-

Favre–Racouchot disease and actinic comedonal plaque. Concomitantly, the patient developed insulin-dependent diabetes mellitus. Treatment with insulin resulted in the disappearance of open comedones and notably regression of lesions of granuloma annulare. Response to insulin therapy in our case supports the hypothesis that insulinopenia could participate in the development of granuloma annulare in some cases.

Key words: comedones; diabetes mellitus; granuloma annulare; solar elastosis.

dominantly over the right one. The individual lesion consisted of a rounded, erythematous plaque with raised margins, a clear center, and without signs of either atrophy or telangiectases. The skin of the extensor aspect of her forearms also showed signs of actinic damage, with a wrinkled, dry, yellowish appearance and mottled hyperpigmentation. She was followed up for 4 years, being initially treated with topical corticosteroids for 1 month and afterwards with pentoxifylline 400 mg twice daily for 3 months without clinical response to both therapies. Fasting glucose was normal. Four years later, the rim of her lesions showed a few open comedones, filled with black keratotic plugs (Fig. 1). No other acneiform lesions were detected and the rest of her physical examination was unremarkable. The comedones were exclusively detected on the erythematous active border of granuloma annulare. Exposure to chloracnogens was discarded. A skin biopsy of one of her lesions showed an area of necrobiosis surrounded by histiocytes and lymphocytes in the mid dermis, with some multinucleated giant cells. Adjacent to this area there was a dilated follicular infundibula filled with a compact mass of laminated keratinous material, corresponding to a comedo (Fig. 2). With orcein staining, a focal loss of elastic fibers was observed at the area of necrobiotic granuloma.

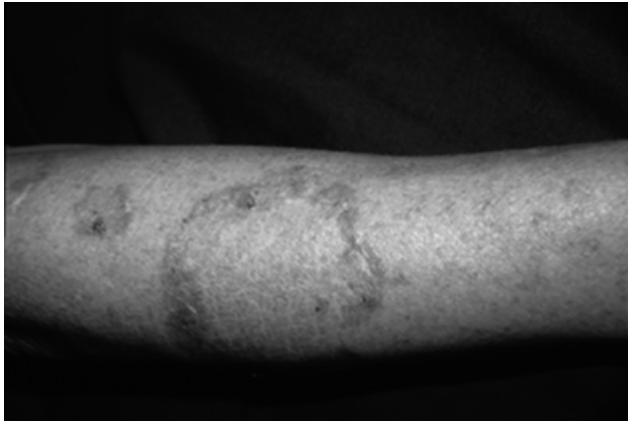


Fig. 1. Open comedones on the rim of granuloma annulare lesions. Signs of actinic damage on the forearm.

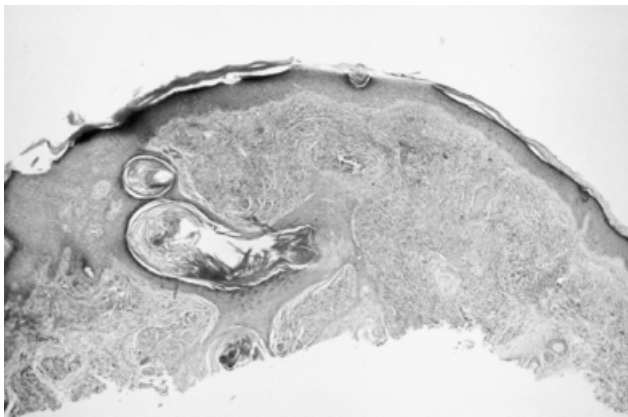


Fig. 2. Area of necrobiosis and a dilated follicular infundibula filled with laminated keratinous material.

At this time the patient developed insulin-dependant diabetes mellitus. The treatment of the diabetic state with insulin induced an amelioration and notable regression of her lesions of granuloma annulare, and the total disappearance of comedones, which previously had failed to respond to other therapies including topical corticosteroids and oral pentoxifylline.

Discussion

Ultraviolet-B irradiation causes marked hyperplasia of the sebaceous gland, with a possible increase in the sebum production (1). It also induces a degeneration of the elastic network, that is easily displaced by comedones that progressively grow without any stromal resistance (2). In the same way, similar changes are seen after irradiation therapy, and exposure to sunlight has also been implicated in the Favre–Racouchot syndrome (3). Among the histopathologic changes of granuloma annulare, the degeneration of collagen fibers and their replacement by mucin, together with diminished or even absent elastic fibers,

could explain the formation of comedones in our case because of the loss of supporting properties of the dermis inducing a distension of the infundibular canal of the sebaceous follicle. Although the forearms are sun-exposed areas, there are few descriptions of comedones on them. Another description of what has been considered an ectopic form of the Favre–Racouchot syndrome is the so-called actinic comedonal plaque (4). It consists of a localized plaque of skin-colored or bluish cystic papules and comedones appearing on sun-exposed areas of white, fair-skinned Caucasians, including the forehead and forearms. On the other hand, granuloma annulare can precede in various years the development of insulin-dependent diabetes mellitus, as in our case. The amelioration of lesions after insulin therapy in our patient would support the hypothesis that insulinopenia could participate in the development of lesions in some cases. Recently, low serum insulin values have been described in patients with granuloma annulare (5).

In summary, comedones are not only restricted to acne but can also appear in senile facial photodamaged skin. In our patient, the presence of granuloma annulare and open comedones could be explained by solar elastosis determined by chronic sun damage. One could also speculate that in some cases low insulin levels could participate in the origin of granuloma annulare, and precede the development of insulin-dependent diabetes mellitus.

References

1. Hedelund L. Favre-Racouchot disease provoked by UV-A1 and UV-B exposure. *Arch Dermatol* 2004; **140**: 129–131.
2. Izumi AK, Marples RR, Kligman AM. Senile (solar) comedones. *J Invest Dermatol* 1973; **61**: 46.
3. Breit S, Flaig MJ, Wolff H, Plewig G. Favre-Racouchot – like disease after radiation therapy. *J Am Acad Dermatol* 2003; **49**: 117–119.
4. John SM, Hamm H. Actinic comedonal plaque—a rare ectopic form of the Favre-Racouchot syndrome. *Clin Exp Dermatol* 1993; **18**: 256–258.
5. Kakourou T, Psychou F, Voutetakis A, Xaidara A, Stefanaki K, Dacou-Voutetakis C. Low serum insulin values in children with multiple lesions of granuloma annulare: a prospective study. *J EADV* 2005; **19**: 30–34.

Corresponding author:

Emilio Sudy

Cristóbal colón

5444 Dp 1408

Las Condes

Santiago de Chile

Chile

Tel: (56-2) 4745898

e-mail: emiliosudy@vtr.net