



# Gastric Stenosis After Laparoscopic Sleeve Gastrectomy in Morbidly Obese Patients

Ana María Burgos · Attila Csendes · Italo Braghetto

Published online: 21 April 2013  
© Springer Science+Business Media New York 2013

**Abstract** Laparoscopic sleeve gastrectomy (LSG) is an effective bariatric procedure. The objective of this study is to describe a series of patients who were subjected to LSG and then developed gastric stenosis, with an emphasis on their treatment and a discussion of the possible underlying mechanisms. From January 2006 to October 2012, 717 patients with morbid obesity underwent LSG in our institution. Out of 717 patients, 571 (79.6 %) were women. The mean age was 36.9 years with a BMI of 37.3 kg/m<sup>2</sup>. Five patients (0.69 %) developed gastric stenosis. Treatment of the stenosis was endoscopic dilatations; however, one patient required a conversion to laparoscopic Roux-en-Y gastric bypass. Stenosis after LSG is rare but requires early diagnosis and treatment.

**Keywords** Sleeve gastrectomy · Complication · Morbid obesity · Gastric stenosis · Stricture

## Introduction

Obesity is a growing medical and socioeconomic problem. Bariatric surgery is the only effective long-term treatment for morbid obesity [1]. Laparoscopic sleeve gastrectomy (LSG) has become an integral part of the surgical treatment of these patients, with well-defined indications, and it is increasingly being recognized as a valid stand-alone procedure for the surgical management of morbid obesity [2–4] due to the fact that LSG causes less morbidity than bypass. Some complications due to LSG procedure have recently been described [5, 6]. However, the occurrence of gastric

stenosis has been rarely published. Therefore, the purpose of the present study is to describe a series of patients who underwent LSG and who presented a gastric stenosis, describing their treatment and discussing possible underlying mechanisms.

## Materials and Methods

### Patients Studied

From January 2006 to October 2012, 717 patients with morbid obesity were included in a prospective protocol and underwent laparoscopic sleeve gastrectomy at the Department of Surgery, University Hospital, Santiago, Chile. Of them, five patients were diagnosed (0.69 %) with gastric stenosis.

The patients were eligible for bariatric surgery according to the National Institute of Health's criteria for bariatric surgery, which include patients with a body mass index (BMI) of 35 kg/m<sup>2</sup> and associated comorbidities or a BMI of 40 kg/m<sup>2</sup> and who have failed conservative management [7]. However, 16 % of patients had a BMI less than 35 kg/m<sup>2</sup> but with other severe comorbidities, such as osteoarticular problems, diabetes, or dyslipidemia. The exclusion criteria were the presence of severe esophagitis, Barrett's esophagus, hiatal hernia over 5 cm in length, as well as the presence of alcoholism, drug addiction, or psychological disorders.

A preoperative endoscopy was performed in all patients according to our protocol of preoperative work in obese patients who are candidates for surgical treatment [8, 9].

In all patients, an upper gastrointestinal radiologic procedure (UGI) using liquid sulfate barium was performed on the third postoperative day (POD). The anatomical

A. M. Burgos (✉) · A. Csendes · I. Braghetto  
Clinical Hospital University of Chile, Santiago, Chile  
e-mail: anamburgos@yahoo.com.mx

characteristics of the tubular stomach, the mean gastric capacity, the rate of emptying, the presence of strictures, and any leaks were carefully evaluated by the staff members of the Radiology Department.

### Surgical Procedure

The complete details of the procedure have been extensively described in previous publications [10, 11]. LSG is performed using five ports. During this intervention, the anesthesiologist introduces through the mouth a 37-F (French) bougie inside the gastric lumen up to the second portion of the duodenum in order to avoid any narrowing of the tubular stomach. We begin the division of the stomach 2–3 cm from the pylorus up to 1 cm from the His' angle using two 4.8-mm green staples and four to five 3.5-mm blue staples, leaving a small gastric tubular pouch of 60- to 80-ml capacity. In all patients, a methylene blue test was performed to test the impermeability of the stapler line.

At the beginning of this study, in the first patients, a 32-F bougie was used and the staple line was reinforced with a running absorbable suture (Byosin<sup>®</sup> 3–0) by the Thru & Thru technique. A drain was left in 75 % of the patients.

### Statistical Analysis

Data are expressed as mean±SD.

### Results

Of 717 patients who underwent LSG, 571 (79.6 %) were women and 146 (20.4 %) were men. The mean age was 36.9±11.5 years (range 16–65), with a mean initial BMI of 37.3±4.1 kg/m<sup>2</sup> (range 32–66).

Five patients (0.69 %) developed gastric stenosis. The patients were two women (40 %) and three men (60 %), with a mean age of 36.8±15.1 years (range 25 to 63). The mean BMI was 36.5±2.1 kg/m<sup>2</sup> (range 35–39.7). Several comorbidities were present in five patients as shown in Table 1. No mortality was reported during follow-up.

Table 2 describes the clinical course of each patient who had stenosis and the treatment received.

### Case Report

#### Patient 1

The first case was a 34-year-old female who underwent LSG using a 32-F Bougie, with continuous sutures done manually along the staple line in order to reinforce it. Her

postoperative stay was 5 days. On POD 7, she presented with nausea and vomiting and was able to tolerate only liquids. An UGI endoscopy showed stenosis at the incisura angularis (mesogastrium). She was re-admitted to the hospital on POD 13, and an endoscopic balloon dilatation was performed. On POD 22, she was discharged from the hospital asymptomatic.

#### Patient 2

The second case was a 63-year-old male. He underwent LSG with a 37-F bougie, with continuous sutures done manually along the staple line in order to reinforce it. During the immediate postoperative months, he had a favorable outcome, but on the seventh postoperative month he presented dysphagia to solid food. The UGI endoscopy revealed a mild stenosis at the incisura angularis. Endoscopic dilatation was performed with Savary bougie 48 F at that time. At 11 months postoperatively, another similar dilatation was performed. Thereafter, the patient had no further complaints.

#### Patient 3

The third case was a 28-year-old female. She underwent LSG with a bougie of 37 F. She was re-admitted because she presented dysphagia to liquids, nausea, vomiting, fever (39.4 ° C), a cough, headache, and body aches on POD 10.

The computed axial tomography of abdomen and pelvis showed a left subphrenic collection which was drained. An UGI series with barium showed a dilated upper part of the sleeve with an immediate narrow passage to the lower part, but which did not show any leak (Fig. 1); H1N1 influenza was diagnosed, with the infection confirmed by rapid diagnostic test and reverse transcription-polymerase chain reaction. After a hospital stay of 13 days, she was discharged but later continued with dysphagia to solid foods. Two months after surgery, an UGI endoscopy was performed, indicating difficulty due to the presence of a kinking point or tortuosity at the mid-sleeve. Dilatation by Savary bougie 45 was performed. She continued with three progressive dilatations using Savary dilators 45, 51, and 54 F up until the seventh month after surgery, with favorable evolution. She is asymptomatic now.

#### Patient 4

The fourth case was a 25-year-old male who underwent LSG with a bougie of 37 F. He underwent surgery again for presenting hemoperitoneum due to omental bleeding on the second postoperative day. Hemostasis and clot extraction with saline lavage was performed.

**Table 1** Demographic data of five patients with gastric stenosis after LSG

Parameters	Patient 1	Patient 2	Patient 3	Patient 4	Patient 5
Age (years)	34	63	28	25	34
Sex	Female	Male	Female	Male	Male
BMI (kg/m <sup>2</sup> )	38	35	35	35	39.7
Comorbidity	Hypercholesterolemia	Hypertension Insulin resistance	Insulin resistance Hepatic steatosis	Insulin resistance	Hypertension Dyslipidemia Hepatic steatosis

His postoperative stay was 7 days, but he was re-hospitalized on POD 21 due to continuous vomiting and dysphagia even for liquids. An UGI series with barium (Fig. 2) and an UGI endoscopy (Fig. 3) showed stenosis on the middle third portion of the sleeve. A dilatation with Savary bougie 36 F was performed. After this procedure, he was completely asymptomatic.

#### Patient 5

The fifth case was a 34-year-old male. He underwent LSG with a bougie of 37 F. On the first postoperative day, he presented with nausea, vomiting, and salivation. An UGI study was performed showing a filiform and delayed passage of contrast material. He was discharged from the hospital only intaking liquids. Subsequently, the patient continued vomiting and was re-admitted on POD 10, presenting dehydration, with blood tests showing a prerenal acute renal failure. The UGI endoscopy evidenced stenosis at the incisura angularis. There were two endoscopic dilatations with Savary bougies on POD 15 and POD 21, but his symptoms persisted. On POD 27, a conversion to laparoscopic Roux-en-Y gastric bypass without distal gastrectomy was performed, and he is now asymptomatic (Fig. 4).

#### Discussion

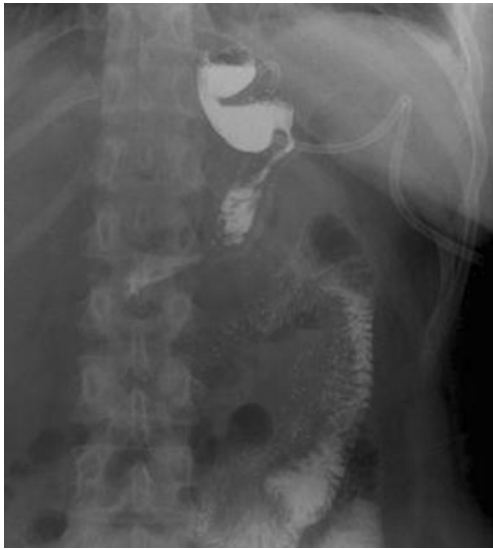LSG has recently emerged as a reproducible surgical technique effective for long-term weight loss stability with regression of most major associated comorbidities. The complication rate for LSG has been 2.9–15.3 %, with an overall reported mortality rate of 0.1–0.39 % according to reported studies [12]. Among the multiple complications which occur following a gastric sleeve, stenosis, or stricture are uncommon complications; however, when they occur, they can cause either obstruction of passage through the gastric lumen or delayed gastric emptying, adding significantly to morbidity. The reported incidence of stenosis ranges from 0.1 to 3.9 % [5, 13–17] (Table 3). In our series, the incidence was 0.69 %, which is similar to that reported in the literature.

This stenosis can result from an anatomical stricture of the gastric tube or gastric tube twisting. The twisting may occur by misalignment of the staples in the same plane or by adhesions in the gastric serosa later on. Another cause is the indentation of the incisura within the gastric lumen, which creates a flap valve producing a functional obstruction. The literature mentions that anatomic stenosis can be produced by sharp angulations of the stapler, reinforcing sutures

**Table 2** Clinical characteristics and treatment of five patients with gastric stenosis after LSG

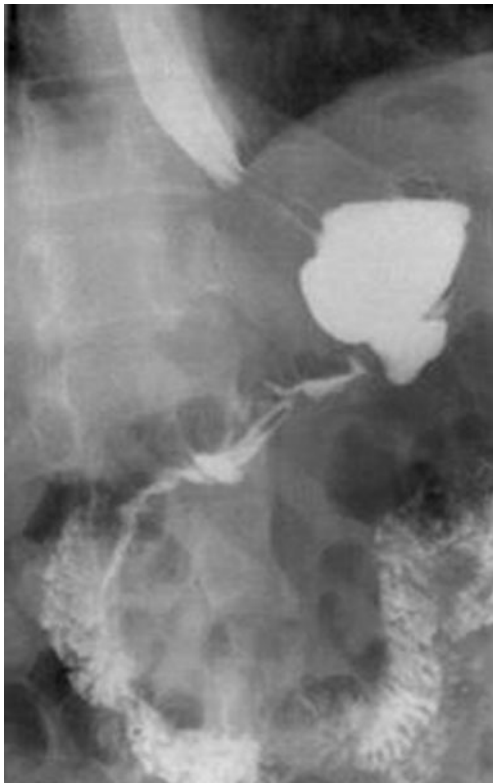
	Patient 1	Patient 2	Patient 3	Patient 4	Patient 5
Symptomatology	Difficulty in liquid food intake	Difficulty in solid food intake	Difficulty in liquid food intake	Difficulty in liquid food intake	Difficulty in liquid food intake
	Regurgitation	Regurgitation	Regurgitation	Regurgitation	Regurgitation
	Vomiting	–	Vomiting	Vomiting	Vomiting
	–	–	Salivation	–	Salivation
	–	–	–	–	Dehydration
	–	–	–	–	Acute renal failure
Location of stenosis at the gastric tube	Middle third	Middle third	Proximal third	Middle third	Middle third
Time between LSG and appearance of symptoms	7 days	7 months (210 days)	10 days	20 days	1 day
Treatment	1 endoscopic balloon dilatation	2 endoscopic bougie dilatations	4 endoscopic bougie dilatations	1 endoscopic bougie dilatation	Conversion to RYGBP

LSG laparoscopic sleeve gastrectomy, RYGBP Roux-en-Y gastric bypass

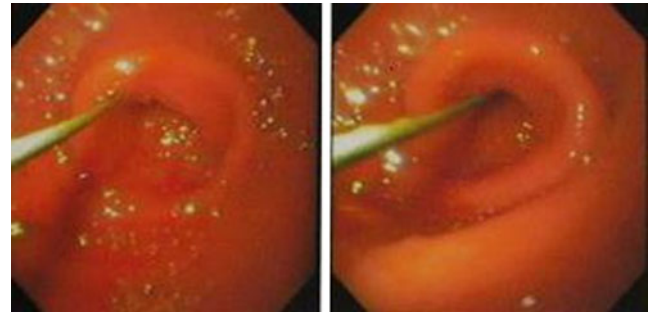


**Fig. 1** Barium upper gastrointestinal contrast study demonstrating a dilated upper part of the sleeve with an immediate narrow passage to the lower part

placed over the staple line, a bougie size that is too small, or hematomas and edema [14, 15]. In our series, in two of the five patients, the staple line had been oversewn, and a bougie 32 F was used only in one of them. We have not sutured, in any case, the omentum with a running suture.

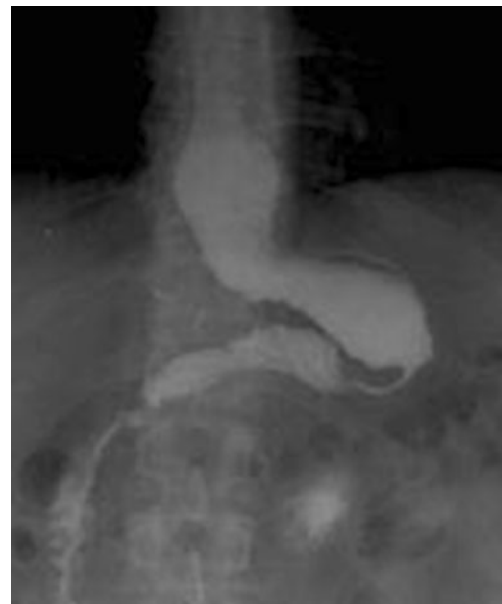

**Fig. 2** Stenosis at the incisura angularis after laparoscopic sleeve gastrectomy



**Fig. 3** Endoscopic view of severe gastric stenosis with a guide wire being placed across the stenosis

Symptoms of stenosis are difficulty in the passage of food through the gastric lumen, with regurgitation of retained food, vomiting, persistent nausea, and even high-grade dysphagia manifested by sialorrhea. These symptoms must be differentiated from gastroesophageal reflux symptoms such as regurgitation and heartburn. Braghetto et al. suggested that LSG modifies the anatomy of the esophagogastric junction and produces an important decrease in lower esophageal sphincter pressure, which, in turn, can cause the appearance of reflux symptoms and esophagitis after the operation due to a partial resection of the sling fibers during gastrectomy [18, 19]. On the other hand, few authors believe that LSG has a beneficial effect on reflux [20, 21]. Further systematic literature reviews about the impact of LSG on gastroesophageal reflux disease report evidence that does not consolidate to a consensus [22]. We believe that it is important to differentiate regurgitation in a patient with gastroesophageal reflux, produced or related to



**Fig. 4** A 34-year-old man with stenosis 24 days after LSG. Two endoscopic dilatations were carried out and laparoscopic RYGBP was performed afterwards

**Table 3** Incidence of gastric stenosis after LSG in reported series

Author (year)	Number of patients	Stenosis rate (%)
Boza et al. (2012) [13]	1,000	0.1
Lalor et al. (2008) [14]	164	0.7
Frezza et al. (2009) [5]	53	0.7
Lacy et al. (2010) [15]	294	1.0
Mui et al. (2008) [16]	49	2.0
Cottam et al. (2009) [17]	126	3.9
Present series (2013)	717	0.7

the technique itself from LSG, with the regurgitation due to a difficulty in the passage or stenosis at the gastric lumen. Keidar et al. [23], in their study, described the presence of gastroesophageal reflux in patients presenting a combination of a dilated upper part of the sleeve with a relative narrowing of the mid-stomach, concluding that since LSG is a novel technique, the knowledge regarding the influence of the operation on the gastroesophageal function is scarce.

Clinical presentation of stenosis is variable and depends on the time of appearance of the obstruction after the operation; however, symptoms are mostly the same (Table 2). In our five patients with stenosis, regurgitation was present in all of them, as well as the difficulty to intake solid food; most of them also had difficulty intaking fluids. In one patient, a severe degree of stenosis led to dehydration and acute renal failure. In our patients, the stenosis was located in the middle third of the gastric tube, at the level of the incisura angularis. The time between the operation and the appearance of symptoms of stenosis may be very variable. Stenosis may occur early, within days, or stenosis may manifest later on, after weeks or months. In our five patients, this time period corresponded from 1 day to 7 months after surgery. We observed that when symptoms appeared early on, they were more varied and severe.

Postoperative radiological evaluation by UGI is important for the diagnosis and management of stenosis following LSG [24]. The contrast swallow studies of all five patients were significant for a wide, dilated fundus with a relatively narrow proximal or mid-stomach, but without complete obstruction. An endoscopy is generally the best alternative to identify the characteristics of a stenosis and to treat the problem simultaneously. The stenosis can be treated by using an endoscopic balloon or bougie dilatation in a single or multiple sessions, as was the case in four of our patients who underwent the dilatation. The use of stents has also been described, but their application has been limited because they are designed primarily for esophageal use. Eubanks et al. [25] reported the use of endoscopic silicone-covered stents to treat strictures. In a 7-day period of stenting, six patients had a success rate of 83 %. They consider that the stent improved the chance of the stricture

to be corrected compared to dilatation alone. The stent allows oral feeding immediately, but the primary morbidity is stent migration.

Regarding surgical treatment, the best possible operation is probably conversion to Roux-en-Y gastric bypass [12]. In our report, we describe one case which required reoperation to correct the obstruction of the passage of food through the gastric lumen. In this patient, stenosis was resolved through laparoscopic gastric bypass, sectioning the stomach proximal to the stricture. Other surgical procedures have also been reported. Sudan et al. [26] described the strictureplasty performed in two patients; the stricture was incised along the longitudinal axis, incorporating the entire length of the stricture. The incision was then closed in the transverse axis in a single layer with permanent suture, resulting in a wider lumen, using the principles of the Heineke–Miculicz technique. Dapri et al. [27] have reported another surgical procedure for long stenosis—laparoscopic seromyotomy. Considering the cited data, it is very important to carefully follow the technical aspects in order to prevent this complication. Stenosis may be avoided by keeping a safe distance between the incisura angularis and the edge where the staples are applied. The same is true for the staple line when it is reinforced by oversewing.

The alteration of the pouch architecture may produce, in addition to kinking, twisting of the tube with a functional obstruction. An excess volume of stomach from the back wall may twist the sleeve as the stapler is applied, leaving an uneven line of staples. We avoid this alteration, keeping the staple line straight by resecting symmetrically the anterior and posterior walls of the stomach. An incomplete release of the posterior gastric fundus or preservation of part of the fundus in an effort to avoid injury of the esophagogastric junction may lead to an enlarged proximal gastric pouch.

In relation to the careful and complete release of gastric adhesions, Zundel et al. [28] mentioned this issue, noting that when sectioning the adhesions between the stomach and the posterior peritoneum over the pancreas, it is frequent to expose the branches of the left gastric artery and if any of these are cut, the blood supply that remains after the gastrectomy would be compromised. This could cause ischemic patches and, in the long run, strictures.

## Conclusion

Stenosis after laparoscopic sleeve gastrectomy is rare but requires early diagnosis and treatment. The first line of treatment for a stenosis is endoscopic dilatation using the Savary bougie, which is an effective, safe, and durable method for managing stenosis after LSG. Operative treatment with conversion to RYGBP is a feasible option in the management of this complication.

**Conflict of Interest** The authors have no conflict of interest.

## References

- Brolin RE. Update: NIH consensus conference. Gastrointestinal surgery for severe obesity. *Nutrition*. 1996;12:403–4.
- Sjostrom L, Lindroos A, Peltonen M, et al. Lifestyle, diabetes, and cardio-vascular risk factors 10 years after bariatric surgery. *N Engl J Med*. 2004;351:2683–93 [PubMed].
- Buchwald H, Avidor Y, Braunwald E, et al. Bariatric surgery. A systemic review and meta-analysis. *JAMA*. 2004;292:1724–37 [PubMed].
- Sjostrom L, Narbro K, Sjostrom CD, et al. Swedish obese subjects study. Effects of bariatric surgery on mortality in Swedish obese subjects. *N Engl J Med*. 2007;357:741–52 [PubMed].
- Frezza E, Womiak S, Gee L. Complications after laparoscopic sleeve gastrectomy for morbid obesity. *Obes Surg*. 2009;19:684–7 [PubMed].
- Fuks D, Dumont F, Bema P. Case report—complex management of a postoperative bronchogastric fistula after laparoscopic sleeve gastrectomy. *Obes Surg*. 2009;19:261–4 [PubMed].
- NIH Consensus Statement. Gastrointestinal surgery for severe obesity. 1991;279:1–20
- Csendes A, Burdiles P, Papapietro K, et al. Results of gastric bypass plus resection of the distal excluded gastric segment in patients with morbid obesity. *J Gastrointest Surg*. 2005;9:121–31.
- Csendes A, Burgos AM, Smok G, et al. Endoscopic and histologic findings of the foregut in 426 patients with morbid obesity. *Obes Surg*. 2007;17:28–34.
- Burgos AM, Braghetto I, Csendes A, et al. Gastric leak after laparoscopic sleeve gastrectomy for obesity. *Obes Surg*. 2009;19:1672–7.
- Csendes A, Braghetto I, León P, Burgos AM. Management of leaks after laparoscopic sleeve gastrectomy in patients with obesity. *J Gastrointest Surg*. 2010;14:1343–8.
- Bellorin O, Lieb J, Szomstein S, et al. Laparoscopic conversion of sleeve gastrectomy to Roux-en-Y gastric bypass for acute gastric outlet obstruction after laparoscopic sleeve gastrectomy for morbid obesity. *Surg Obes Relat Dis*. 2010;6:566–8.
- Boza C, Salinas J, Salgado N, et al. Laparoscopic sleeve gastrectomy as a stand-alone procedure for morbid obesity: eeport of 1,000 cases and 3-year follow-up. *Obes Surg*. 2012;22:866–71.
- Lalor P, Tucker O, Szomstein S, et al. Complications after laparoscopic sleeve gastrectomy. *Surg Obes Relat Dis*. 2008;4:33–8.
- Lacy A, Ibarzabal A, Pando E, et al. Revisional surgery after sleeve gastrectomy. *Surg Laparosc Endosc Percutan Tech*. 2010;20:351–6.
- Mui WL, Ng EK, Tsung BY, et al. Laparoscopic sleeve gastrectomy in ethnic obese Chinese. *Obes Surg*. 2008;18:1571–4.
- Cottam D, Qureshi FG, Mattar SG, et al. Laparoscopic sleeve gastrectomy as an initial weight loss procedure for high-risk patients with morbid obesity. *Surg Endosc*. 2006;20:859–63.
- Braghetto I, Lanzarini E, Korn O, et al. Manometric changes of the lower esophageal sphincter after sleeve gastrectomy in obese patients. *Obes Surg*. 2010;20:357–62.
- Braghetto I, Csendes A, Korn O, et al. Gastroesophageal reflux disease after sleeve gastrectomy. *Surg Laparosc Endosc Percutan Tech*. 2010;20:148–53.
- Santoro S. Technical aspects in sleeve gastrectomy. *Obes Surg*. 2007;17:1534–5.
- Petersen W, Meile T, Kuper M, et al. Functional Importance of laparoscopic sleeve gastrectomy for the lower esophageal sphincter in patients with morbid obesity. *Obes Surg*. 2012;22:360–6.
- Chiu S, Birch D, Shi X, et al. Effect of sleeve gastrectomy on gastroesophageal reflux disease: a systematic review. *Surg Obes Rel Dis*. 2011;7:510–5.
- Keidar A, Appelbaum L, Schweiger C, et al. Dilated upper sleeve can be associated with severe postoperative gastroesophageal dysmotility and reflux. *Obes Surg*. 2010;21:140–7.
- Triantafyllidis G, Lazoura O, Sioka E, et al. Anatomy and complications following laparoscopic sleeve gastrectomy: radiological evaluation and imaging pitfalls. *Obes Surg*. 2011;21:473–8.
- Eubanks S, Edwards C, Fearing N, et al. Use of endoscopic stents to treat anastomotic complications after bariatric surgery. *J Am Coll Surg*. 2008;206:935–9.
- Sudan R, Kasotakis G, Betof A, et al. Sleeve gastrectomy strictures: technique for robotic-assisted strictuureplasty. *Surg Obes Relat Dis*. 2010;6:434–6.
- Dapri G, Cadière G, Himpens J. Laparoscopic seromyotomy for long stenosis after sleeve gastrectomy with or without duodenal switch. *Obes Surg*. 2009;19:495–9.
- Zundel N, Hernández J, Galvao Neto M, et al. Strictures after laparoscopic sleeve gastrectomy. *Surg Laparosc Endosc Percutan Tech*. 2010;20:154–8.