Pediatric Dermatology Vol. 33 No. 4 e260–e264, 2016

Ultrasound Diagnosis and Staging in Pediatric Hidradenitis Suppurativa

Abstract: Hidradenitis suppurativa (HS) can affect children, and ultrasound has been proven to be useful in diagnosis and staging. The sonographic characteristics of HS in children have not been reported. We studied color Doppler ultrasound images of children (≤15 years old; *n* = 12) with clinically and sonographically positive criteria for HS. Sonographic scoring of hidradenitis suppurativa (SOS-HS) was used to stage the cases sonographically. Subclinical pseudocysts were found in 92% of the cases, fluid collections in 83%, and fistulous tracts in 58%. Retained hair tracts in the fluid collections and fistulous tracts were present in 100% of patients; 67% of cases were SOS-HS stage II. In 92% of cases, management was modified after the ultrasound examination. In conclusion, ultrasound can be a reliable and safe imaging tool to support diagnosis and staging and may help in the noninvasive monitoring of treatment in children.

Hidradenitis suppurativa (HS), a chronic inflammatory disease that affects the terminal follicle and presents with recurrent nodules and abscesses usually in the intertriginous regions (1), can occasionally affect children, most commonly during puberty (2). Two percent to 7.7% of patients have a clinical early onset of the disease (3,4), although HS is more common in young adults, especially women in the second or third decade of life (1). Because quality of life is poor with this disease (5), and management of children is reported to be more complicated (2), pediatric HS should be diagnosed and staged early.

The presence of HS in children has been linked to hormonal factors such as a hyperandrogenemic state or premature adrenarche (6), but the specific cause of HS remains to be determined. Current theories propose occlusion or dysfunction of the follicular unit components at the terminal hairs that may secondarily affect the apocrine glands (2,7).

Ultrasound is a nonradiating, safe imaging technique that has proven useful for supporting the diagnosis of HS using sonographic scoring of hidradenitis suppurativa (SOS-HS) to stage the disease by defining sonographic diagnostic criteria (8,9).

Ultrasound staging using the SOS-HS scoring system has been reported to modify management of adult patients significantly in 82% of cases, including the use of different medical treatments and a change from medical to surgical management in 24% (9).

Ultrasound studies have been focused on adult HS, which is the most common. The anatomic sonographic characteristics of HS in children have not been described.

The aim of this study was to review the sonographic characteristics of HS in children (≤15 years old).

METHODS

We retrospectively studied color Doppler ultrasound images of 12 children (9 girls, 3 boys; average age 12 ± 4 years [range 1–15 years]) sequentially referred by dermatologists with a diagnosis of HS from January 2014 to July 2015.

All cases included in this study were clinically and sonographically positive for HS (9) and the ultrasound examination took place in the axillary and groin regions and other clinically affected areas.

Pseudocysts, fluid collections, and fistulous tracts were noted and counted and the presence or absence of hair tracts within the fluid collections and fistulous tracts was determined.

The ultrasound criteria for each type of lesion (pseudocyst, fluid collection, fistula, retained hair tracts) were defined according to previously reported definitions (9).

A radiologist with more than 15 years of experience in dermatologic ultrasound performed all of the examinations and staged the disease using the SOS-HS scoring system (Table 1) (9). In all cases, Logic E9 XD Clear color Doppler ultrasound equipment (General Electric Health Systems, Milwaukee, WI) with variable-frequency probes and upper frequencies of 16 and 18 MHz was used. The imaging technique used to examine the children followed the principles described for studying localized lesions of the skin on sonography (10) and diagnosing and staging HS (9).

Lesional skin was sonographically compared with normal perilesional skin or the contralateral nonaffected region.

The Institutional Review Board (Clinica Servet) approved the study and waived the need for signed informed consent from patients. All ultrasound examinations were performed under the Helsinki principles of medical ethics.

DOI: 10.1111/pde.12895

TABLE 1. *Sonographic Scoring of Hidradenitis Suppurativa (SOS-HS)*

Stage I. Single fluid collection and/or dermal changes* affecting a single body segment (either one side or bilateral), without fistulous tracts.
Stage II. Two to four fluid collections and/or a single fistulous tract with dermal changes, affecting up to two body segments (either one side or bilateral).
Stage III. Five or more fluid collections and/or two or more fistulous tracts with dermal changes, and/or involvement of three or more body segments (either one side or bilateral).
Extracted from Wortsman et al (11).

*Dermal changes include hypoechoic or anechoic pseudocystic nodules, widening of the hair follicles, and/or alterations in the dermal thickness or echogenicity.

RESULTS

According to sonographic criteria, the cases showed involvement of the groin region in 83% (n = 10) of cases and the axillary region in 50% (n = 6). Additional involvement of the scrotal and perineal regions was observed in 17% (n = 2) of cases.

Subclinical lesions were present in all cases (pseudocysts in 92% [n = 11], fluid collections in 83% [n = 10], fistulous tracts in 58% [n = 7]).

A connection to the widened base of the hair follicles was observed in all of the fluid collections and fistulous tracts, and the fluid collections and fistulous tracts involved the dermis and upper hypodermis. Greater vascularity with low-velocity (≤15 cm/sec) arterial and venous vessels was found in the periphery of the fluid collections and fistulous tracts. Small fragments of hair tracts (≤1 cm) within the fluid collections and fistulous tracts were detected in 100% of cases.

Sixty-seven percent (n = 8) of cases were SOS-HS stage II, 25% (n = 3) were SOS-HS stage I, and 8% (n = 1) were SOS-HS stage III.

The characteristics of these children with HS are shown in Table 2.

The youngest and most severe case was a boy age 1 year and 7 months with axillary involvement (SOS-HS stage III). Neither hormonal laboratory tests (serum androstenedione, 17-OH progesterone, sex hormone–binding globulin, dehydroepiandrosterone sulfate, thyroid-stimulating hormone, free thyroxine, follicle-stimulating hormone, luteinizing hormone) nor genetic factors were positive in this case. This child was born with a nevus comedonicus that later developed clinical hidradenitis lesions. He had five subclinical dermal and hypodermal fluid collections in the left axillary region, which had the worst scores in the group (Figs. 1–3; Videos S1 and S2). A concomitant epidermal cyst was found in the axillary region of another boy.

There was a modification of medical treatment in 92% (11/12) of these children after the ultrasound examination that consisted of the addition of an antibiotic (mostly clindamycin), change in dosage, or use of another therapeutic scheme (mostly from flucloxacillin or cefadroxil to clindamycin). None of these cases switched to biologic or surgical management.

DISCUSSION

Regardless of age, anatomic involvement in children with HS seems to follow the same sonographic pattern as in adults, but early diagnosis and staging in these cases could be even more critical.

Ultrasound may support the differential diagnosis of folliculitis or other causes of solid or cystic cutaneous nodules (10,11). This is relevant considering that the diagnosis of HS in children might be underestimated according to some reports (2).

The frequent involvement of the groin and the predominance of girls is similar to the clinical

TABLE 2. *Main Characteristics of Children with Hidradenitis Suppurativa (HS)*

Cases	Sex	Age, years	Axillary	Groin	Other	Fluid collections, n	Fistulas, n	Hair tracts	Pseudocysts	Sonographic scoring of HS Stage
1	Female	14	–	+	–	3	0	+	+	II
2	Female	10	+	+	–	1	1	+	+	II
3	Female	15	+	+	–	3	1	+	+	II
4	Female	14	–	+	–	3	1	+	+	II
5	Female	14	–	+	–	1	0	+	+	I
6	Female	15	–	+	–	0	1	+	–	II
7	Male	14	+	+	–	3	1	+	+	II
8	Female	14	–	+	–	0	1	+	+	II
9	Female	10	–	+	Perineum	3	1	+	+	II
10	Male	1	+	–	–	5	0	+	+	III
11	Female	11	+	–	–	1	0	+	+	I
12	Male	7	+	+	Scrotum	2	0	+	+	I

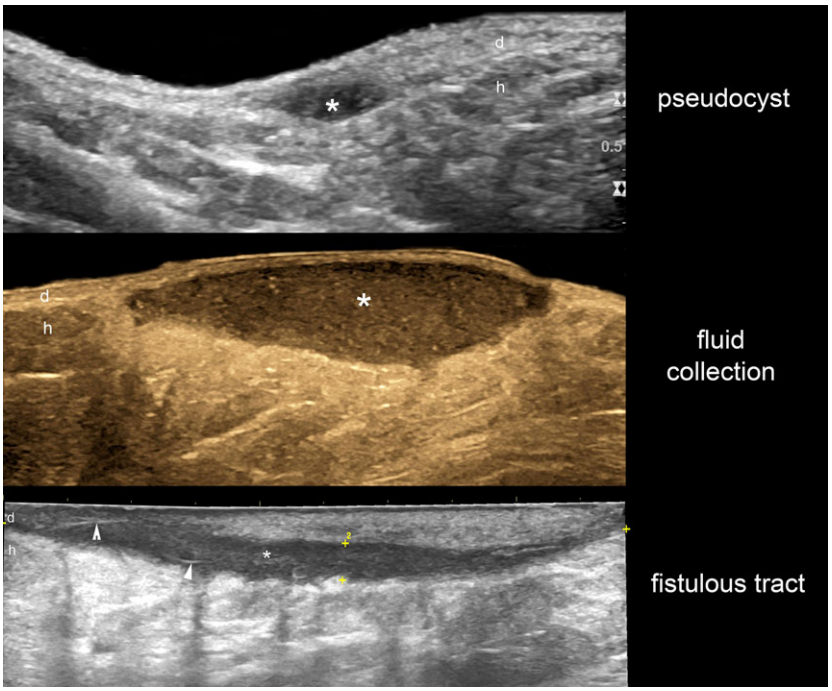

Figure 1. Sonographic main type of lesions (*pseudocyst, fluid collection, fistulous tract) in pediatric hidradenitis suppurativa. d, dermis; h, hypodermis. Arrowheads mark retained small hair tract fragments within the fistulous tracts.

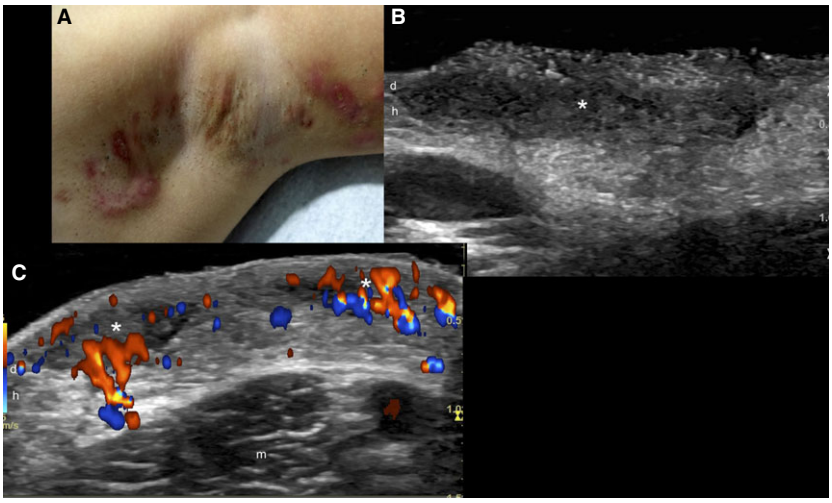

Figure 2. A boy, age 1 year and 7 months, with nevus comedonicus and hidradenitis suppurativa in the left axillary region. (**A**) Clinical photograph. (**B**) Ultrasound (grey scale, transverse view) shows hypoechoic fluid collection (*) that involves dermis and hypodermis. (**C**) Color Doppler ultrasound (transverse view) shows hypervascularity in the periphery of two adjacent hypoechoic fluid collections (*) affecting the dermis (d) and hypodermis (h).

descriptions of children with HS in the literature (2). The large number of subclinical lesions such as pseudocysts, fluid collections, and fistulous tracts is comparable with that described in previous publications on the sonographic characteristics of HS in adulthood (9).

The clinical reports mention clinical Hurley stage I as the most common stage in children with HS (12); in contrast, we found that most of the patients were in SOS-HS stage II. This might be because of the presence of subclinical lesions that cannot be reliably discriminated by palpation only. Thus a clinically

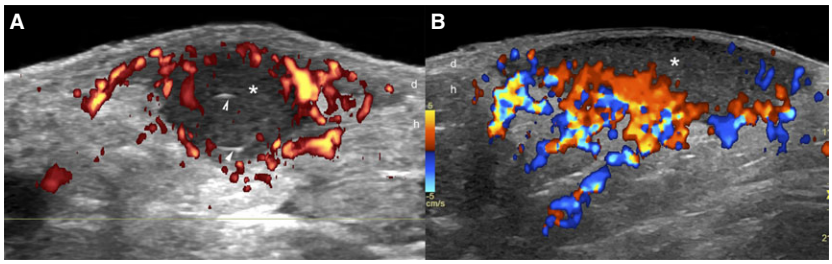

Figure 3. (**A** and **B**) Fluid collections in pediatric hidradenitis suppurativa. Color Doppler ultrasound shows variable degrees of hypervascularity in the periphery of the hypoechoic fluid collections (*). Small hyperechoic linear fragments of hair tracts (arrowheads) are shown in (A). d, dermis; h, hypodermis.

palpable nodule may correspond to a fluid collection, a fistula, a pseudocyst, or scarring tissue, and the best way to discriminate between these seems to be ultrasound imaging.

Among the causes proposed for early onset of the disease are a hyperandrogenemic state, premature adrenarche, and genetic factors (1,8,13), although we did not find an association with those.

Our series included a child 1 year and 7 months old who, as far as we know, seems to be the case diagnosed at the earliest age with clinically and sonographically positive HS criteria in the indexed literature. The development of HS lesions in this case showed a severe grade (SOS-HS stage III), in agreement with his underlying pathology. HS complicating nevus comedonicus has been reported in an infant and has been found to be related to major mechanical stress on the hair follicles in this condition (14).

All of the cases had retained hair tracts within the fluid collections and fistulous tracts, which is a higher proportion than in a previous ultrasound study of HS in an adult population, which reported this finding in 80% of the cases (15). This may be related to the pathogenesis of the disease and could affect the severity of this disabling condition. Nevertheless, in children, these hair tract fragments tend to be smaller (≤1 cm) than the maximum size of those found in adults (3 cm) (15). The latter finding may be related to the young age and hormonal development of the patients.

Modification of management after ultrasound examination in up to 92% of children is of paramount importance and is greater than the change in management reported in adults (82%) (9).

Given the wide range of anatomic information that ultrasound provides, it may also allow treatment to be monitored noninvasively (16). This could be even more critical at early ages, considering that neither therapeutic trials nor management guidelines have been published in pediatric HS.

CONCLUSION

Ultrasound can reliably and noninvasively support the diagnosis and staging of HS in children. This may support earlier, more precise management of these cases.

Supporting Information

Additional supporting information may be found in the online version of this article:

Video S1. Color Doppler ultrasound shows a small hypoechoic fluid collection affecting the dermis and hypodermis in the right groin. A small hyperechoic linear fragment of hair tract within the collection and slightly increased blood flow in the periphery are also noted.

Video S2. Hypoechoic fistulous tract running through the dermis and hypodermis in the right groin.

REFERENCES

1. Jemec GB. Clinical practice. Hidradenitis suppurativa. N Engl J Med 2012;366:158–164.
2. Bettoli V, Ricci M, Zauli S et al. Hidradenitis suppurativa-acne inversa: a relevant dermatosis in paediatric patients. Br J Dermatol 2015;173:1328–1330.
3. Vasquez BG, Alikhan A, Weaver AL et al. Incidence of hidradenitis suppurativa and associated factors: a population-based study of Olmsted County, Minnesota. J Invest Dermatol 2013;133:97–103.
4. Palmer RA, Keefe M. Early-onset hidradenitis suppurativa. Clin Exp Dermatol 2001;26:501–503.
5. Esmann S, Jemec GB. Psychosocial impact of hidradenitis suppurativa: a qualitative study. Acta Derm Venereol 2011;91:328–332.
6. Lewis F, Messenger AG, Wales JKH. Hidradenitis suppurativa as a presenting feature of premature adrenarche. Br J Dermatol 1993;129:447–448.
7. Wang SC, Wang SC, Sibbald RG et al. Hidradenitis suppurativa: a frequently missed diagnosis, part 1: a review of pathogenesis, associations, and clinical features. Adv Skin Wound Care 2015;28:325–332.

8. Wortsman X, Jemec GB. Real-time compound imaging ultrasound of hidradenitis suppurativa. Dermatol Surg 2007;33:1340–1342.
9. Wortsman X, Moreno C, Soto R et al. Ultrasound in-depth characterization and staging of hidradenitis suppurativa. Dermatol Surg 2013;39:1835–1842.
10. Wortsman X, Wortsman J. Clinical usefulness of variable frequency ultrasound in localized lesions of the skin. J Am Acad Dermatol 2010;62:247–256.
11. Wortsman X, Wortsman J, Matsuoka L et al. Sonography in pathologies of scalp and hair. Br J Radiol 2012;85:647–655.
12. Scheinfeld N. Hidradenitis suppurativa in prepubescent and pubescent children. Clin Dermatol 2015;33:316–319.
13. Danby FW. Current concepts in the management of hidradenitis suppurativa in children. Curr Opin Pediatr 2015;26:466–472.
14. Dufour DN, Bryld LE, Jemec GB. Hidradenitis suppurativa complicating naevus comedonicus: the possible influence of mechanical stress on the development of hidradenitis suppurativa. Dermatology 2010;220:323–325.
15. Wortsman X, Wortsman J. Ultrasound detection of retained hair tracts in hidradenitis suppurativa. Dermatol Surg 2015;41:867–869.
16. Wortsman X. Imaging of hidradenitis suppurativa. Dermatol Clin 2016;34:59–68.

Ximena Wortsman, M.D.*,†
Carolyn Rodriguez, M.D.‡
Carolina Lobos, M.D.§
Gonzalo Eguiguren, M.D.§
Maria Teresa Molina, M.D.¶
Departments of *Radiology and †Dermatology, Institute for Diagnostic Imaging and Research of the Skin and Soft Tissues, Clinica Servet, Faculty of Medicine, University of Chile, Santiago, Chile, ‡Department of Dermatology, Centro Referencia Cordillera and Clinica Orlandi, Santiago, Chile, §Department of Dermatology, Clinica Las Condes, Santiago, Chile, ¶Department of Dermatology, Hospital Clinico Universidad de Chile, Faculty of Medicine, University of Chile, Santiago, Chile

Address correspondence to Ximena Wortsman, M.D., Lo Fontecilla 201, 734, Las Condes, Santiago, Chile, or e-mail: xworts@yahoo.com.