

CASE REPORT

Barber-Say syndrome: further delineation of the clinical spectrum

Fanny M. Cortés, Ledia A. Troncoso, Angélica R. Alliende and Bianca L. Curotto

Abstract

We report on a 14-year-old girl who presented a multiple congenital anomaly pattern: ablepharon, hypertelorism, telecanthus, macrostomia, helix agenesis of both ears, redundant thick skin and severe hirsutism, the 5th reported case of Barber-Say syndrome. Our patient had almost the same phenotype as that of the patient cited by Martínez Santana *et al.* (*Am. J. Med. Genet.* 47: 20-23, 1993) including the same until then undescribed dermatoglyphic pattern.

INTRODUCTION

In 1982, Barber *et al.* reported on a 3.5-year-old girl, with a “new” syndrome characterized by ectropion, macrostomia, abnormal skin, severe hypertrichosis, and growth retardation. A second case was reported by David *et al.* in 1991, with almost the same phenotype, a third case by Martínez Santana *et al.* (1993), and finally Mazzanti *et al.* (1998) reported the fourth known case, with the same malformation pattern. Here we report an additional case with exactly the same multiple congenital anomaly pattern.

CASE REPORT

The patient, last of eight otherwise healthy siblings (four boys, four girls), presently 14 years old, was born at term, after the eighth pregnancy of healthy, nonconsanguineous parents (father and mother were 41 and 42 years old, respectively), with no relevant family history. Pregnancy and delivery were normal, with weight of 3400 g, and 50 cm in length at birth. Striking dysmorphic features were immediately noted: ablepharon, hypertelorism, telecanthus, macrostomia, helix agenesis of both ears, redundant thick skin and severe hirsutism especially of the back. No other visceral abnormalities were observed during the neonatal period.

Evaluated at the age of 13 (Figure 1A,B), the patient showed normal mental development. Her anthropometric measurements were: height, 147.5 cm (10th percentile); weight, 37.4 kg (15th percentile), and head circumference, 52.2 cm (40th percentile). Her principal facial features were: aged appearance, ablepharon, ectropion, sparse eyebrows and eyelashes, hypertelorism, telecanthus, bulbous nose with anteverted nares, macrostomia with thin lips, prognathism, abnormally and low set small ears with a prominent antihelix, neither tragus nor lobule, and abnormal

external auditory canals which were narrow and tortuous. She had redundant frontal skin and dark thick hair. She had severe hirsutism especially of forehead, neck and back. The thoracic skin was atrophic with hypoplastic nipples. Dermatoglyphic pattern was unusual because no figures except for horizontal ridges in all 10 fingers were present. The rest of the physical examination was within normal limits. Laboratory tests performed included: urine and blood amino acid screening, mucopolysaccharide screening, T3, T4 and TSH, and complete skeletal roentgenograms. All were within normal limits. The banded karyotype was 46,XX.

The patient had normal menses, with menarche at the age of 12. Mental development and neurologic evaluation were completely normal.

DISCUSSION

This study presents the 5th reported case of Barber-Say syndrome. Our patient had almost the same phenotype as that reported by Martínez Santana *et al.* (1993) including the same until then undescribed dermatoglyphic pattern. Our patient, as the oldest of the five found until now (Table I), provides an opportunity to study phenotype evolution of this disorder with aging, keeping in mind that sexual development was completely normal.

As our patient is the eighth child of healthy nonconsanguineous parents and has seven healthy siblings, and based on the nearly identical phenotype described in all reported patients, we assume that this is not a developmental disorder but a genetic condition. Recently, Dinulos and Pagon (1999) reported for the first time a mother to son transmission of this condition, supporting the hypothesis of autosomal dominant inheritance.

While differential diagnosis of this disorder should include ablepharon-macrostomia syndrome (McCarthy and

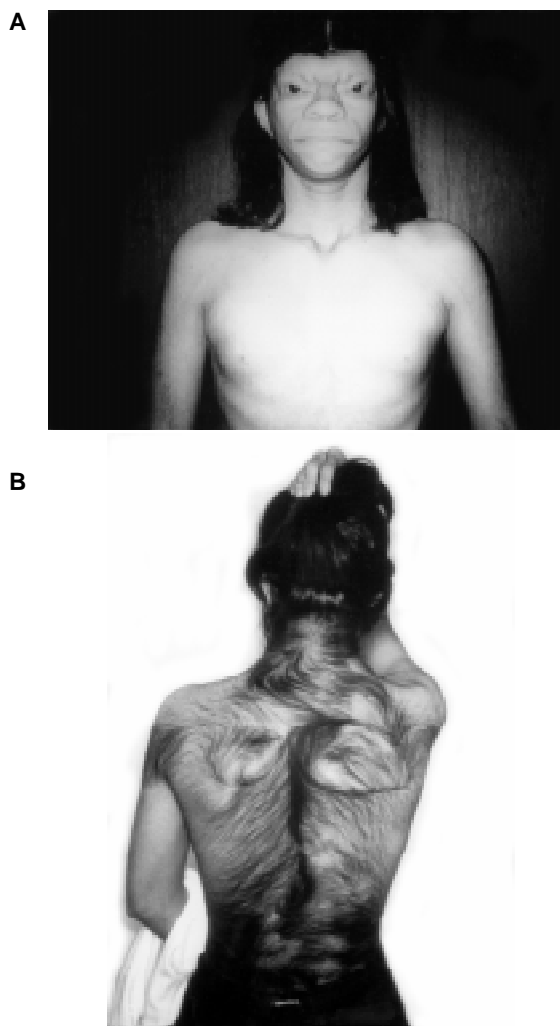


Figure 1 - **A**: Frontal view of the patient at age 14; **B**: dorsal view of the patient at age 14.

West, 1977; Hornblass and Reifler, 1985, Cesarino *et al.*, 1988), the final diagnosis of Barber-Say in our patient is based on normal development combined with severe hirsutism, not found in the former syndrome. A comparison was made with patients described with associated ablepharon-macrostomia (Table II). Recently, Mazzanti *et al.* (1998) suggested that Barber-Say and ablepharon-macrostomia syndromes derive from a defective regulation of the same gene.

Both diseases have an apparent sex bias, because in Barber-Say syndrome four of the five patients reported are females and in ablepharon-macrostomia syndrome all patients described are males, but we do not have a clear explanation for this.

The impressive compromise of ectodermal structures in our patient prompted us to consider this disorder an ectodermal dysplasia, as did Martínez Santana *et al.* (1993) in their paper; unfortunately, our patient and her family refused a skin biopsy.

RESUMO

Apresentamos uma paciente de 14 anos, de sexo feminino, portadora de um quadro de múltiplas anomalias congênicas: hipertelorismo, telecanto, macrostomia, agenesia da hélice em ambos os pavilhões auriculares, pele grossa e redundante e hirsutismo severo, que corresponde ao 5º caso reportado de síndrome de Barber-Say. Esta paciente tem praticamente o mesmo fenótipo que a paciente descrita por Martínez Santana *et al.* (*Am. J. Med. Genet.* 47: 20-23, 1992), incluindo o mesmo padrão dermatoglífico que não havia sido descrito até então.

REFERENCES

Barber, N., Say, B., Bell, R.F. and Merveille, O.C. (1982). Macrostomia, ectropion, atrophic skin, hypertrichosis, and growth retardation.

Table I - Comparison among similar previously described patients and the present case.

Physical findings at birth	Barber <i>et al.</i> (1982)	David <i>et al.</i> (1991)	Martínez-Santana <i>et al.</i> (1993)	Mazzanti <i>et al.</i> (1998)	Present case	Summary
Sex	F	M	F	F	F	1M/4F
Continental affiliation	E	E	E	E	E	5E
Birth weight (g)	2720 (P15)	2550 (P5)	2900 (P25)	2200 (P5)	3400 (P65)	
Birth length (cm)	?	48.5	49	48	50	
Head circumference (cm)	?	34	34	33	?	
Bilateral ectropion	+	+	+	+	+	5/5
Telecanthus	+	+	+	+	+	5/5
Broad bulbous nose	+	+	+	+	+	5/5
Hypoplastic nasal alae	+	+	+	+	+	5/5
Macrostomia	+	+	+	+	+	5/5
Generalized laxity of the skin	+	+	+	+	+	5/5
Generalized hypertrichosis	+	+	+	+	+	5/5
Abnormal pinnae	+	+	+	+	+	5/5
Tortuous ear canal	+	+	+	+	+	5/5
Other malformations	-	-	-	-	-	0/5
Father's age (years)	?	34	27	?	41	
Mother's age (years)	21	35	21	?	42	
Consanguinity	-	-	+	-	-	1/5
Family recurrence	-	-	-	-	-	0/5

E: European-derived affiliation.

Table II - Differential diagnosis with Ablepharon-Macrostomia syndromes.

Findings	Patients					Summary
	McCarthy and West (1977)	Hornblaus and Reifler (1985)	Cesarino <i>et al.</i> (1988)	Our patient		
No. of families	1	1	1	1	1	
Sex	M	M	M	M	F	4M/1F
Age (years)	6	2	1	4	14	
Parental consanguinity	(-)	(-)	(-)	(-)	(-)	
Hair						
Absent or sparse eyebrows and lashes	(+)	(+)	(+)	(+)	(+)	5/5
No hair at birth; late development of sparse thin hair	(+)	(+)	(-)	(-)	(-)	2/5
Total absence of lanugo	(-)?	(-)?	(+)	(-)	(-)	1/5
Generalized hypertrichosis; back, neck and forehead	(-)	(-)	(-)	(+)	(+)	2/5
Craniofacial anomalies						
Ablepharon	(+)	(+)	(+)	(+)	(-)	4/5
Ocular hypertelorism/telecanthus	(+)	(+)	(+)	(+)	(+)	5/5
Corneal opacity	(-)	(-)	(+)	(+)	(-)	2/5
Nystagmus	(-)	(-)	(+)	(-)	(-)	2/5
Bilateral ectropion	(-)	(-)	(-)	(-)	(+)	1/5
Bilateral entropion	(-)	(-)	(-)	(+)	(-)	1/5
Macrostomia	(+)	(+)	(+)	(+)	(+)	5/5
Abnormally shaped ears	(+)	(+)	(+)	(+)	(+)	5/5
Abnormally shaped nose	(+)	(+)	(+)	(+)	(+)	5/5
Tortuous and small external auditory canals	(-)	(-)	?	?	(+)	2/3
Flattened malar eminence	(+)	(+)	?	?	(-)	2/3
Underdeveloped mandible (slightly)	?	?	?	(+)	(+)	2/2
Thin lips	(+)	(-)?	(-)	(+)	(-)	2/5
Skin						
Laxity/redundance	(+)	(+)	(+)	(+)	(+)	5/5
Dry and coarse	(+)	(+)	(-)	(-)	(-)	2/5
Aplasia/hypoplasia of nipples	(+)	(+)	(-)	(-)	(+)	3/5
Fissures (at birth)	(-)?	(-)?	(-)?	(+)	(-)?	1/5
Webbing between proximal phalanges of fingers	(+)	(-)	(-)	(-)	(-)	1/5
Tight skin over interphalangeal joints of fingers	(+)	(+)	(-)	(-)	(-)	2/5
Neurologic and developmental status						
Short stature	(-)?	(-)?	?	(+)	(+)	2/4
Mental retardation	(+)	(-)	(+)?	(+)	(-)	3/5
Neurologic impairment	(+)	(-)	(+)	(+)	(-)	3/5
Genitalia						
Ambiguous	(+)	(+)	(+)	(-)	(-)	3/5
Oral cavity						
Small teeth	(+)	(-)	(-)	(-)	(-)	1/5
Natal teeth	(-)	(-)	(-)	(+)	(-)	1/5
High-arched palate	(-)	(-)	(+)	(-)	(-)	1/5
Trunk						
Flat or upward-pointing umbilicus	(+)	(-)	(-)	(-)	(-)	1/5
Ventral hernia/omphalocele	(-)	(-)	(+)	(-)	(-)	1/5
Karyotype	46,XY	46,XY	46,XY	46,XY	46,XX	
Family recurrence	(-)	(-)	(-)	(-)	(-)	0/5

Syndrome Ident. 8: 6-9.

Cesarino, E.J., Pinheiro, M., Freire-Maia, N. and Meira-Silva, M.C. (1988).

Lid agenesis-macrostomia-psychomotor retardation-forehead hypertrichosis - a new syndrome? *Am. J. Med. Genet.* 31: 299-304.

David, A., Gordeeff, A., Badoual, J. and Delaire, J. (1991). Macrostomia, ectropion, atrophic skin, hypertrichosis: another observation. *Am. J. Med. Genet.* 39: 112-115.

Dinulos, M.B. and Pagon, R. (1999). Autosomal dominant inheritance of Barber-Say syndrome. *Am. J. Med. Genet.* 86: 54-56.

Hornblaus, A. and Reifler, D.M. (1985). Ablepharon macrostomia syndrome. *Am. J. Ophthalmol.* 99: 552-556.

Martínez Santana, S., Perez Alvarez, F., Frias, J.L. and Martínez-Frias, M.L. (1993). Hypertrichosis, atrophic skin, ectropion, and macrostomia (Barber-Say syndrome): report of a new case. *Am. J. Med. Genet.* 47: 20-23.

Mazzanti, L., Bergamaschi, R., Neri, I., Perri, A., Patrizi, A., Cacciari, E. and Forabosco, A. (1998). Barber-Say syndrome: Report of a new case. *Am. J. Med. Genet.* 78: 188-191.

McCarthy, G.T. and West, C.M. (1977). Ablepharon macrostomia syndrome. *Dev. Med. Child Neurol.* 19: 659-672.

(Received October 13, 1999)

