

# Laparoscopic Resectional Gastric Bypass in Patients with Morbid Obesity: Experience on 112 Consecutive Patients

Italo Braghetto · Attila Csendes · Owen Korn ·  
Luis Gutierrez · Luis Brunet · Enrique Lanzarini ·  
Maher Mushle · Héctor Valladares · Jorge Rojas

Received: 11 August 2010 / Accepted: 22 October 2010 / Published online: 9 November 2010  
© 2010 The Society for Surgery of the Alimentary Tract

## Abstract

**Introduction** Gastric bypass, without gastric resection of the distal excluded stomach, is the surgical treatment more frequently performed for morbid obesity. Several postoperative complications related to the “in situ” distal stomach have been described, and few cases of undetected gastric carcinoma located in this segment of stomach have been published. In this paper, we present our early postoperative results in patients submitted to laparoscopic gastric bypass with resection of distal stomach in patients with morbid obesity.

**Methods** One hundred twelve consecutive patients were included in this study. The mean body weight was  $112.15 \pm 5.1$  (range 78–145), and BMI was  $40.5 \pm 6.9$  kg/m<sup>2</sup> (32.9–50.3). Patients were submitted to resectional gastric bypass by laparoscopic approach. The operative time was  $133.7 \pm 29.1$  min (range 120–240).

**Results** Postoperative complications occurred in 12 patients (10.7%) without any mortality. Early complications were observed in 11 patients while one patient presented a late complication, four patients were re-hospitalized, three of them without operation and other four of them were re-operated due to early (three patients) or late complication (one patient). One hundred patients (89.2%) were discharged at fourth postoperative day, seven patients remained in hospital between 5 and 10 days, and four patients after the tenth day due to complications. Leaks were observed in three patients. The histological study of the resected specimen was normal in only 8.9%.

**Conclusions** Laparoscopic resectional gastric bypass presents very similar results compared to classic gastric bypass, without significant increase of morbidity, mortality, early and late postoperative results, and therefore, it is an option for the surgical treatment of morbid obesity in countries with high risk of gastric carcinoma.

**Keywords** Gastric resection · Bypass · Laparoscopy

## Introduction

Gastric bypass, without resection of the distal excluded stomach, is the surgical treatment more frequently performed for morbid obesity. The results of this procedure have been

extensively reported and discussed on the literature.<sup>1–3</sup> Several postoperative complications related to the in situ distal stomach have been described, and few cases of undetected gastric carcinoma located in this segment of stomach have been published.<sup>4–10</sup> In addition, in Chile, Japan, Korea, and Colombia, countries which present high rate of gastric cancer,<sup>11–13</sup> it is valid to postulate bariatric surgery with resection of the distal stomach. The criticism to this operation is that it could represent a more prolonged operation and could be associated with increased rate of postoperative complications.

In this paper, we present our early postoperative results in patients submitted to laparoscopic gastric bypass with resection of distal stomach in patients with morbid obesity.

I. Braghetto (✉) · A. Csendes · O. Korn · L. Gutierrez ·  
L. Brunet · E. Lanzarini · M. Mushle · H. Valladares · J. Rojas  
Department of Surgery, Faculty of Medicine, University of Chile,  
Santos Dumont 999,  
Santiago, Chile  
e-mail: ibraghet@redclinicauchile.cl

## Patients and Methods

One hundred twelve consecutive patients were included in this study, 80 women and 32 men with a mean age of  $39.4 \pm 10.7$  years. All patients had completed the protocol of preoperative evaluation including blood and metabolic tests, upper gastrointestinal endoscopy, abdominal ultrasound, nutritional and psychological visit in order to agree the surgical indication. The mean body weight was  $112.15 \pm 5.1$  kg (range 78–145), and BMI was  $40.5 \pm 6.9$  kg/m<sup>2</sup> (32.9–50.3). Sixteen patients had BMI less the 35 and corresponded to patients with esophagitis with Barrett's esophagus or diabetes type 2, and one patient with antral GIST. Fifty-eight patients had BMI between 35 and 39.9, and 38 patients had BMI more than 40 kg/m<sup>2</sup>, all of them with associated co-morbidities. Table 1 shows the clinical characteristics and associated co-morbidities diagnosed preoperatively. All patients gave their informed consent for resectional gastric bypass.

## Surgical Technique

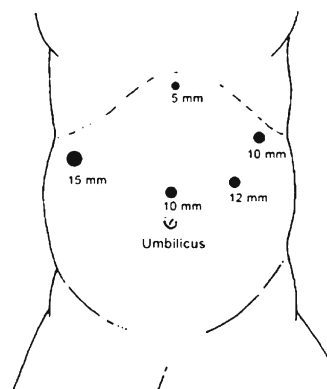
After a small learning curve period, we adopted the Brazilian technique for laparoscopic gastric bypass,<sup>14</sup> introducing the addition of resection of the distal segment of stomach. The patient is placed in French position

(with legs in abduction position). Pneumoperitoneum with Veress needle was working at 15 mmHg of intra-abdominal pressure and placement of 5 trocars for liver retraction, optic system, assistant, and surgeon instruments (Fig. 1). When the greater curvature is exposed using a Ligasure® device (Covidien, Cincinnati, USA), the gastroepiploic gastric branches are divided starting from 2 cm beyond the pylorus until the His angle, cutting the short gastric and posterior fundic vessels in a similar way when performing sleeve gastrectomy. Division of the adhesions of the posterior antral wall to the anterior pancreatic face and exposing the posterior wall of the duodenal bulb is performed. The gastrohepatic ligament is opened at the avascular membrane, and identification and division of the right gastric artery with Ligasure®, (Covidien, Mansfield, MA, USA) is performed. Division of the duodenum with a Duet-Endogia blue cartridge (Covidien, Mansfield, MA, USA) was introduced by the 15 mm port located at the right quadrant. Division of the fatty tissue, vessels, and Latarjet nerve of the lesser curvature exposed in this fashion the gastric wall just in front of the cardiobulbar vessels, 3 cm below the cardia. Then, a 45-mm Endogia device 4.8 mm stapler (blue cartridge) is introduced by the same port located at the right quadrant in order to start the division of the stomach 3 cm below the cardia. Gastric transection is completed with 2–3 additional 60 mm blue cartridge Endogia addressed up to the His angle in order to perform the gastric pouch guided by gastric tube 36French introduced by the anesthesiologist, leaving a gastric pouch

**Table 1** Patients' demographic characteristic and co-morbidities

BMI	Mean, $40.5 \pm 6.9$ kg/m <sup>2</sup> (range, 32.9–50.3)
<35	<i>n</i> =16
35.1–39.9	<i>n</i> =58
>40	<i>n</i> =38
Co-morbidities	
Diabetes	30
Fatty liver	26
Esophagitis without Barrett	24
Hypercholesterolemia	28
Hyperinsulinism	22
Barrett's esophagus	18 (with esophageal ulcer 2)
Arterial hypertension	18
Hiatal hernia	3
Asthma	1
Knee arthrosis	2
Infertility	1
Hypothyroidism	4
Cholelithiasis	6
Obstructive sleep apnea syndrome	1
Varicose veins	2
Failed sleeve	3
Failed lap band	2

- 5mm Sub-xiphoid for liver retraction
- 15mm upper right quadrant for left hand operator
- 10mm supra-umbilical for optical system
- 12mm upper left quadrant for hand operator and assistant
- 10mm left sub-costal for hand operator or assistant



**Fig. 1** Trocars site distribution: 5 mm subxiphoid for liver retraction, 15 mm upper right quadrant for left hand operator, 10 mm supra-umbilical for optical system, 12 mm upper left quadrant for hand operator and assistant, 10 mm left sub-costal for hand operator or assistant

of 60 ml capacity, measured by the instillation of methylene blue through the tube. The great omentum is retracted in order to localize the Treitz angle and identification of the biliary loop which is elevated to the gastric stump in order to approximate it and to perform gastrojejunostomy with 45 mm blue or white cartridge Endogia. Reinforcement of the stapler line and closure of the orifice of the entrance of the instrument is done with Monocril® 000 sutures (Ethicon, Cincinnati, USA). Afterwards, we perform latero-lateral jejunojunal anastomosis, 170 cm distally, with white cartridge 45 mm endogia in the same fashion. In order to exclude any leak of the suture line, we temporarily block the flux to the jejunum with a long intestinal forceps and the anesthesiologist introduces 60 to 80 ml of methylene blue. Finally, we divided the biliary loop, 2 cm from the gastrojejunostomy, in order to complete the Roux-en-Y gastrojejunostomy (Fig. 2). A drain is placed close to the gastrojejunostomy and duodenal stump was exteriorized by the right quadrant port.

#### Postoperative Care

After the operation, patients were sent to a surgical intermediate care unit, and they stayed there for 1 day, being then discharged to the regular room. During the 3 days, patients receive intravenous therapy, and at third or fourth postoperative day, patients were submitted to radiological evaluation with barium sulfate in order to evaluate the anatomy of the gastric pouch, to exclude leaks, anastomotic strictures, or bowel obstruction.

Patients were followed-up monthly during the first 6 months by surgeons and nutriologist in order to evaluate

the body weight decrease, nutritional indications, and vitamin supplement. After this, patients are controlled each 6 months.

In this paper, we analyze the operative time, early and late postoperative evolution, histological findings of the resected stomach, early postoperative complications, and follow-up regarding the loss of weight and BMI decrease during the first year after operation.

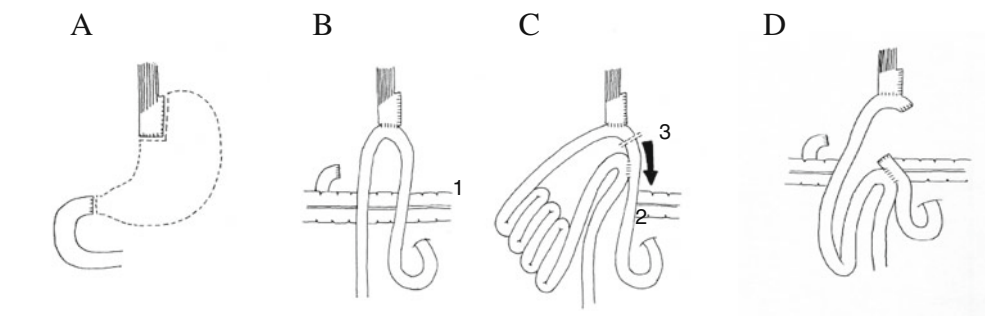
#### Results

Table 2 shows the early evolution after the operation. The operative time was  $133.7 \pm 29.1$  min (range 120–240). The more prolonged operations correspond to patients with adhesions of the posterior gastric wall and anterior pancreatic surface probably due to previous healed gastric ulcer (one patient), bleeding of the dissection of gastrohepatic ligament (three patients), and difficulties in performing the jejunojunoanastomosis (two patients). No patients needed intraoperative transfusion. After the operation, patients received intravenous glucosaline solution with electrolytes, antibiotic prophylaxis for 12 h (Cefazolin®, 1 g/8 h), antithrombotic prophylaxis (Fragmin® 5,000 Us/c/day), early kinesic respiratory and body exercises, prokinetics, and pain management with ketoprofen and morphine PCA (patient-controlled analgesia) in demand.

At third postoperative day, all patients were controlled radiologically with barium sulfate swallow. In patients without complication, the intra-abdominal drain was retired at fourth postoperative day. After this, patients start with oral intake with semisolid foods for 2 weeks. One patient had to be converted to open surgery (0.9%) due to kinking

**Fig. 2** Operation steps and anastomosis performance. **a** Line of gastric division and resection. **b** 1=gastrojejunal anastomosis. **c** 2=jejunojuno anastomosis. 3=jejunal division below gastrojejunal anastomosis. **d** Final aspect of resectional gastric bypass

- A Line of gastric division and resection
- B 1 = gastrojejunal anastomosis
- C 2 = jejunojuno anastomosis  
3 = Jejunal division below gastrojejunal anastomosis
- D Final aspect of resectional gastric bypass



**Table 2** Operative and early postoperative evolution

Operative time (min)	133.7±29.1 (120–240)
Gastric capacity (ml)	38.4±14.1 (20–85)
Hospital stay (days)	5.8±0.97 (4–45)
Conversion	1 patient (kinked jejunojejunostomy)
Complications	12 patients
Re-operation	4 patients
	3 early
	1 hemoperitoneum trocar site+intestinal injury
	1 bowel obstruction
	1 early leak of duodenal stump
	1 late
	1 late leak of duodenal stump
Re-hospitalization	4 patients
	1 sub-phrenic abscess
	1 pneumonia
	1 spleen injury
	1 late duodenal stump leak (2 months later)
Mortality (30 days)	0

of the jejunojejunoanastomosis. Postoperative complications occurred in 12 patients (10.7%) without any mortality. Early complications were observed in 11 patients while one patient presented a late complication (late duodenal stump leak). Four patients were re-hospitalized, three of them without re-operation and one for re-exploration due to sub-hepatic abscess secondary to duodenal stump leak. Four patients were re-operated, three early after the operation and one due to late complication (2 months after the operation). The majority of patients were discharged at fourth postoperative day, but the mean hospital stay was 5.8±0.97 days (range 4–45) (Table 2).

Leaks were observed in three patients, two early leaks and one patient presented sub-hepatic abscess 2 months after the operation due to a minimal duodenal stump leak. The early leaks were minimal and localized in 1 patient at the gastric pouch suture line which appeared at third postoperative day and in 1 patient at the duodenal stump diagnosed very early at the first postoperative day. The first one was treated conservatively with suction through the drain which was left in situ until no bile or gastric juice flux was observed and radiological control confirmed the leak closure. The second one was re-operated 24 h after the initial operation for suture and reinforcement of the stapled line by laparoscopic route. Patient with late duodenal stump leak was re-operated in order to drain the abscess and suture the orifice of the leak. The evolution of this patient with sub-phrenic abscess was successful once it was drained percutaneously, and fever and blood tests were normalized. This patient remained for 45 days hospitalized. Patients with intraluminal bleeding of the stapled suture line were successfully treated endoscopically with epinephrine submucosal injection and discharged between at sixth and eighth days. Patient with hemoperitoneum due to trocar bleeding was re-operated at 12 h after the operation by laparoscopy for peritoneal clean and hemostasis but after this a bowel perforation was suspected and he was re-operated again and remained in intensive care unit for 19 days and definitively discharged from the hospital at the 22nd day (Table 3).

One hundred patients (89.2%) were discharged at fourth postoperative day, seven patients remained in hospital between 5 and 10 days, and four patients after the tenth day due to complications. Among patients re-hospitalized, the first one, in order to drain percutaneously a left sub-phrenic abscess under tomographic visualization, also received complementary antibiotic treatment (metronidazole and cefuroxime) with complete clinical and tomographic resolution. The second one was re-hospitalized in

**Table 3** Hospital stay and complications

	Patients (n=112)	Type of complication (n=12)	Hospital stay (days)
Less than 4 days	100	No	
5 to 10 days	7	2 bleeding suture line	7
		2 atelectasis	4
		1 pneumonia	9
		1 duodenal stump leak	8
		1 intestinal obstruction	8
More than 10 days	4	1 spleen injury	11
		1 hemoperitoneum	25
		1 gastric suture leak	
		1 sub-phrenic abscess	12
<sup>a</sup> Patient discharged at 4 postoperative day, re-hospitalized 2 months later during 45 days	1 <sup>a</sup>	1 sub-hepatic abscess	
		Duodenal stump leak	45 <sup>a</sup>

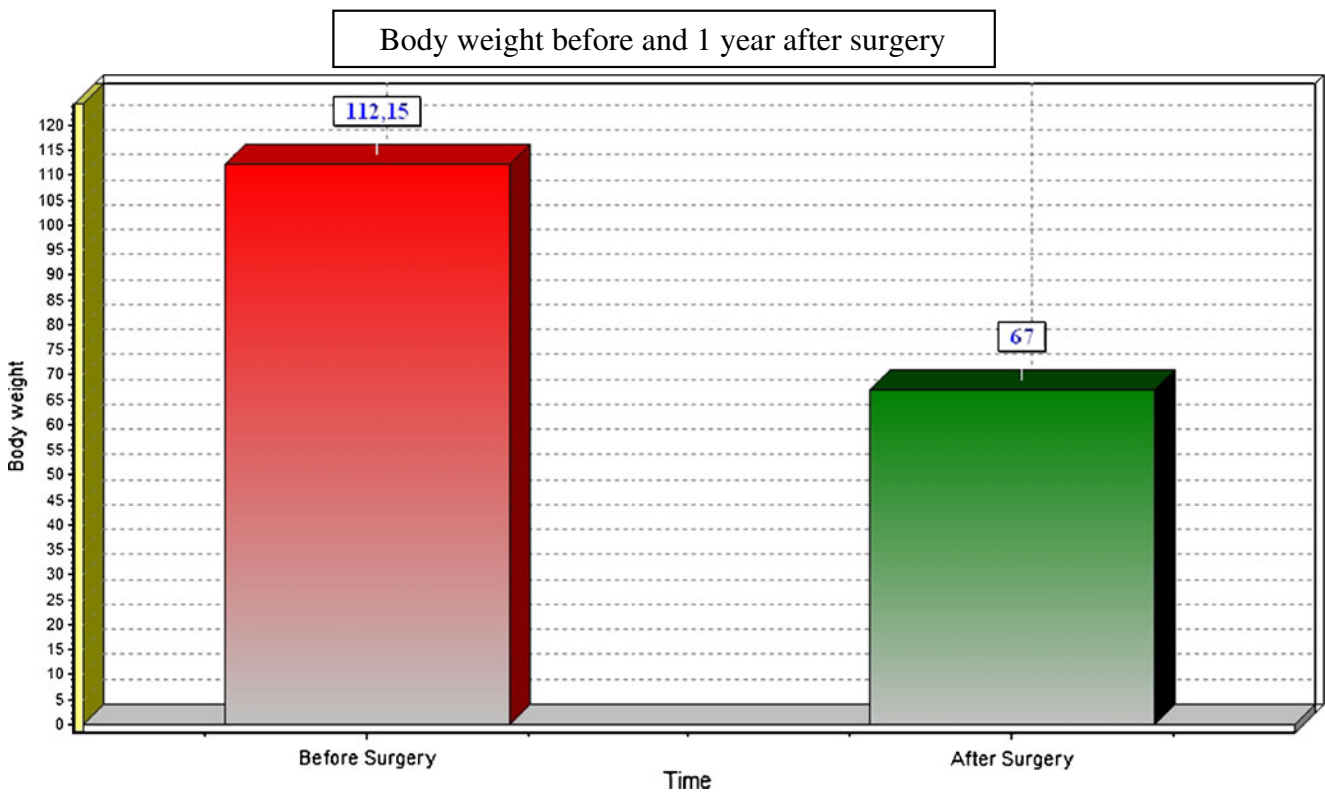
**Table 4** Postoperative complication and management. (*n*=12)

Complication	Number	Management
Early	11	
Leaks	2	1 Drainage and suction 1 Laparoscopic duodenal stump closure
Sub-phrenic abscess	1	Puncture
Atelectasis	2	Kinesic
Pneumonia	1	Kinesic, antibiotics
Intragastric bleeding (suture line)	2	Endoscopic injection
Hemoperitoneum	2	1 Re-operation trocar hemostasia+Intestinal suture 1 Spleen embolization
Bowel obstruction	1	Laparoscopic distorsion
Late	1	Open drain and duodenal suture 45 days

order to proceed to angiographic embolization of a branch of the spleen artery to stop a bleeding secondary to spleen injury during the operation; the third one presented fever at 21st postoperative day due to pneumonia, which was treated with antibiotics and kinesic therapy, and the fourth was re-operated by open approach in order to drain a late sub-hepatic abscess due to a minimal late duodenal leak 2 months later. Among the other three re-operated patients, the first one was due to early duodenal fistula at first postoperative day in order to perform closure of the leak

and reinforcement of the stapler suture, the second one was due to 12 mm of paraumbilical trocar bleeding with hemoperitoneum, and the third one was due to intestinal obstruction due to adhesion near to the jejunojunostomy. The details of the complications observed and the management indicated are shown in Table 4.

The late evolution regarding body weight is presented in Fig. 3. The body weight decreased from  $112.15 \pm 15.1$  kg (range 78–145) to  $67.09 \pm 10.2$  kg at 1 year after surgery. At the first month, the weight loss was  $12.9 \pm 3.1$  kg, at the



**Fig. 3** Late evolution of body weight after surgery

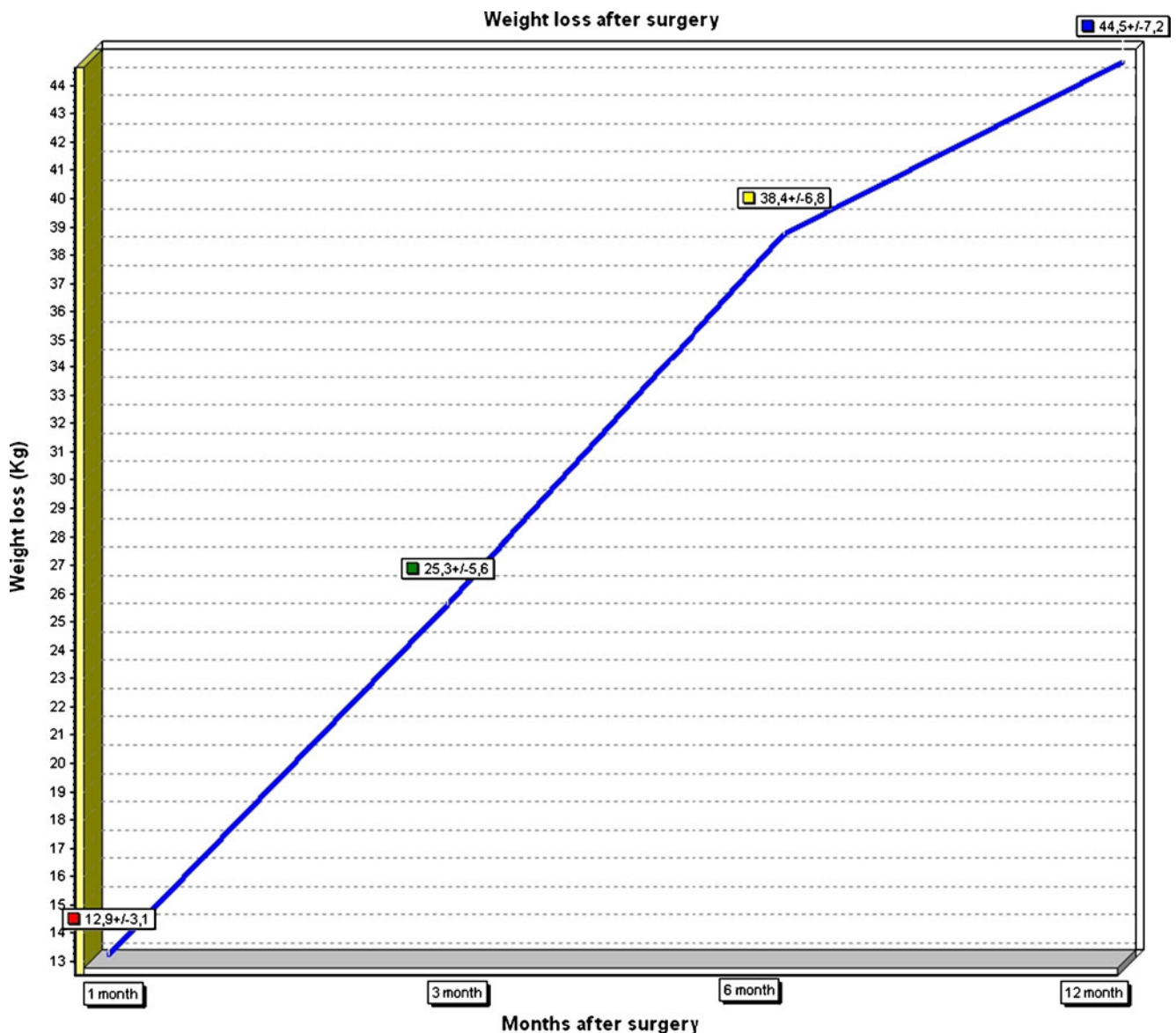


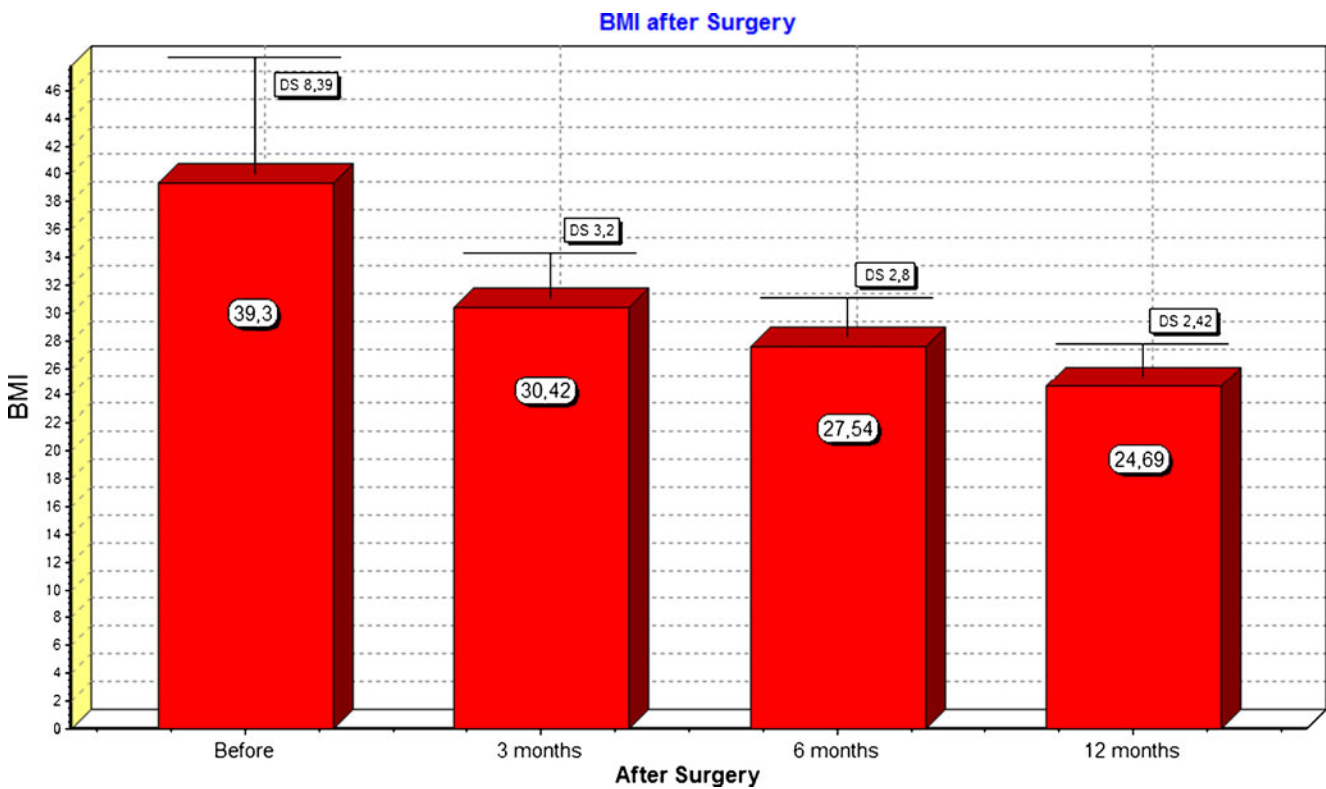
Fig. 4 Body weight loss after 1, 3, 6 and 12 months after surgery

third month, it was  $25.3 \pm 5.6$  kg, at the sixth month, it was  $38.4 \pm 6.8$  kg, and at 1 year after surgery, it was  $44.5 \pm 7.2$  kg (Fig. 4). Body mass index (BMI) reduction is presented in Fig. 5, which decreased from  $40.5 \pm (32.9-50.3)$  to  $30.4 \pm 3.2$  at the third month to  $27.54 \pm 2.8$  at the sixth month and to  $24.69 \pm 2.4$  1 year after surgery.

The results of the histological study of the resected specimen is shown in Table 5. Normal mucosa was found in ten patients (8.9%). The other 102 patients (91%) had different type of histological chronic gastritis. Concomitant findings were found in 34 patients (30.3%). Presence of *Helicobacter pylori*, despite its preoperative eradication, was found in five patients.

## Discussion

The incidence rate of gastric cancer in the last decade in Chile is 27/100,000 inhabitants, but in the southern provinces, this incidence reaches to 29.2/100,000 inhabitants. Countries such as USA and Western Europe have low rates of gastric cancer, showing a decrease in the last decade, while in other countries with high rate of gastric cancer, such as Japan, Korea, and Latin America countries (Chile, Argentina, Brazil, Colombia, and Mexico), minimal changes have been reported in the last years.<sup>11-13</sup> For this reason, we and other Asian authors have postulated surgical procedure for morbid obesity which involve resection of the



**Fig. 5** Body mass index (BMI) reduction after the operation

stomach.<sup>5,15</sup> In our institution, the surgery more frequently performed in the last decade was resectional gastric bypass by open approach. Csendes et al.<sup>5</sup> published the results and the arguments concerning why gastric resection of distal stomach is a valid procedure in Chile and other countries with high incidence of gastric cancer. Kasama et al. propose to perform sleeve gastrectomy plus duodeno-jejunal bypass

for morbid obese patients in Asia.<sup>15</sup> In the last 3 years, we started to perform gastric bypass with resection of the distal segment of stomach in patients with moderate obesity with Barrett's esophagus or diabetes associated or in patients with proper morbid obesity. Most surgeons can criticize our strategy; however, the results obtained have been very successful. Regarding the technical point of view, resection of the stomach creates a large space below the proximal gastric stump which facilitates enormously the performance of gastrojejunal anastomosis.

The first conclusion of this paper is that gastric resection of distal stomach during gastric bypass does not increase morbidity or postoperative mortality. After a short period of learning curve, the duration of the operation is only

**Table 5** Histological findings in the resected stomach *n*=112

	Number	Percent
Normal	10	8.9
Gastritis		
Atrophic	11	9.8
Lymphoid	15	13.4
Follicular	33	29.4
Interstitial	38	33.9
Erosive hemorrhagic	5	4.4
Concomitant findings:		
Intestinal metaplasia	19	8.9
Lymphoid nodular hyperplasia	5	4.4
Polyps	5	4.4
Dysplasia	4	3.5
GIST	1	0.9
<i>Helicobacter pylori</i> +	5 <sup>a</sup>	4.4

<sup>a</sup> Despite preoperative eradication

**Table 6** Main early postoperative complications after gastric bypass: literature review (9,930 patients in 21 selected series)

Complications	Mean (range)
Leaks	4.2% (0.6–6.6)
Bowel obstruction	2.4% (0.4–5.5)
GI bleeding	1.9% (0.3–3.7)
Stomal stricture	3.3% (0.5–6.6)
Pneumonia	0.14% (0.06–0.4)
Pulmonary embolism	0.4% (0–0.8%)
Mortality	0.5% (0–1.1%)

15–20 min more prolonged compared to non-resectional gastric bypass by laparoscopic approach (LGBP). The operative time reported for non-resectional LGBP ranges from 91 to 277 min.<sup>16–19</sup> For open resectional gastric bypass, the duration of the operation ranged between 2 and 3 h.<sup>5</sup> The results obtained in this study regarding postoperative complications are no different to the reported results published by Csendes et al. for open resectional gastric bypass.<sup>5</sup>

Our conversion rate is similar to the reported results in patients submitted to LGBP. The mean conversion rate for classic gastric bypass is 2.2% (range 0–3.0%) according to several selected papers analyzed.<sup>4,19</sup>

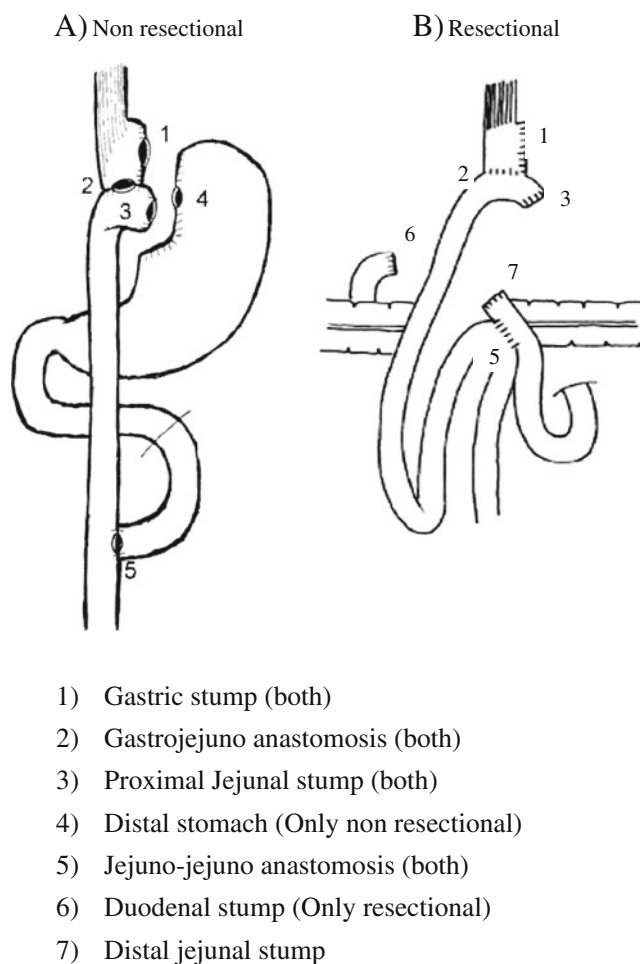
Regarding early postoperative morbidity, no increased complications due to resection of the distal stomach have been observed. Although there may be some patients with duodenal stump leak, which is managed medically by drainage, this complication is equivalent to complications when leaving the stomach in situ such as leaks from residual excluded stomach, bleeding from stomach and duodenum, and mostly producing gastro-gastric fistulas in 1% to 8% of the cases. Therefore, resection of the excluded stomach has several benefits. Besides, the early complications after laparoscopic Roux-en-Y gastric bypass without resection for distal stomach range between 3.3% and 15%.<sup>4,18–21</sup> After open and more recently, after laparoscopic non-resectional gastric bypass, several complications related to the in situ gastric remnant have been described. Bleeding from erosive gastritis or peptic ulcers (1–4%), gastro-gastric fistulas (6%), and perforated gastric ulcers with intra-abdominal abscess have been reported and discussed in the literature. In Table 6, we showed a summary of the reported complications after gastric bypass considering the more recent reports.<sup>4,18–22</sup> Nyugen et al. reported recently 21.6% of complication after gastric bypass.<sup>4,18</sup> The early complications include anastomotic leaks, bleeding, venous thromboembolism, anastomotic strictures being so frequent as 36% after hand-sewn anastomosis and being so critical that need dilatation in 10% of cases.<sup>21–24</sup> Maclean and others reported anastomotic ulcer reaching 16%, and more recently, in the last IFSO European Chapter Congress, similar results were reported.<sup>2,6,7,25–36</sup> In the present series, there are very few complications.

Anastomotic leaks are related to the learning curve but it occurs in 1–3% of patients even in experienced clinical centers.<sup>4,25,37</sup> Csendes et al.<sup>28</sup> published the experience in 557 patients submitted to open resectional gastric bypass. In this study, 12 patients (2.1%) developed an anastomotic leak at the gastrojejunostomy. All were managed medically, with antibiotics if necessary, enteral or parenteral feeding and frequent control by imaging procedures. One of the 12 (8%) patients died, 32 days after surgery from septic shock,

without any abdominal collection secondary to the leak. The potential sites of leaks after surgery comparing gastric bypass with or without gastric resection are almost the same (Figs. 5 and 6). Duodenal stump leak is the additional site of leak after resectional gastric bypass, but it is very rare and easily treated by drainage if it is diagnosed early.

Gastrointestinal bleeding ranged between 0.26% and 3.7%.<sup>29,30,35</sup> Pulmonary embolism is a rare complication because of the prophylactic treatment with anticoagulant early after surgery; however, it represents the main cause of postoperative mortality.<sup>4,26,30</sup>

The mean hospital stay ranged from 1.6 to 4.0 days, excluding the patients who were converted to open surgery.<sup>4,19,26</sup> In the present experience, we have observed no increase of hospital stay, and cases more than 4 days correspond to few cases with postoperative complications.



**Fig. 6** Possible sites of leaks comparing non-resectional with resectional gastric bypass. **a** Non-resectional. **b** Resectional. 1 Gastric stump (both), 2 gastrojejunostomy (both), 3 proximal jejunal stump (both), 4 distal stomach (only non-resectional), 5 jejunostomy (both), 6 duodenal stump (only resectional), 7 distal jejunal stump



Postoperative mortality ranged between 0% and 1.5%. However, data from Washington state register and Medicare systems reported 30-day mortality rate reaching to 2.0%. On the contrary, data from academic centers reports low postoperative mortality after bariatric surgery.<sup>4,19,38,39</sup> Morbidity and mortality are very low in our experience and exactly similar to the classic Roux-en-Y gastric bypass.

If we compare these data, we can conclude that resectional laparoscopic Roux-en-Y gastric bypass does not increase operative time, hospital stay, morbidity, and postoperative mortality.

Endoscopic/histologic findings or risk of gastric cancer in gastric segment have been studied and discussed in the literature. Kuga et al.<sup>40</sup> endoscopically studied the main gastric chamber after gastric bypass without resection. Only 25.7% of patients presented normal mucosa, 74.3% had erythematous or erosive/hemorrhagic gastritis or atrophic gastritis. We observed almost the same findings studying histologically the resected specimen of distal stomach. Therefore, an important proportion of morbidly obese patients have pathologic gastric mucosa at moment of surgery. The controversy on the appearance of gastric cancer mainly refers to countries with a high incidence of gastric cancer (Asian and Latino-American countries). In countries with a very low incidence of gastric cancer, such as USA (six times less than Chile) obviously, it is not an important topic for discussion. In our department, we have found three cases of early gastric cancer during the preoperative evaluation by endoscopy, which is included in our study protocol for obese patients candidates to surgical treatment, and one patient was re-operated after sleeve gastrectomy and submitted to total gastrectomy because in the histological examination of the resected stomach, in situ gastric cancer in the line of resection was found.

Besides, few cases of gastric cancer cases have been published.<sup>41–48</sup> However, it is probably that other cases have not been reported. An experimental study suggested that Roux-en-Y gastric bypass reduces the risk of development of gastric cancer due to the lack of contact of with carcinogens' lower bile reflux and fewer bacterial in the proximal gastric pouch. However, this mechanism is not applied to the in situ distal segment because presence of chronic bile reflux, antral intestinal metaplasia (12%), bacterial overgrowth, and carcinogens could promote the development of gastric cancer in this segment, which is difficult to detect until the tumor has advanced disease.<sup>49,50</sup>

Other point of discussion is the necessity of late reconnection of gastric bypass performing re-gastrogastroanastomosis due to complications or later sequelae of malnutrition or vitamins deficiencies.<sup>51</sup> We have never observed the necessity of reconnection of gastric transit due to this situation in more than 1,500 open or laparoscopic gastric bypass performed in our department. On the contrary, at the late

follow-up, patients tend to regain weight. Therefore, it is not an argument to consider for leaving the distal stomach in situ for these eventual late complications.

We agree with all the arguments discussed by Csendes et al. in his previous report<sup>5</sup> in order to suggest gastric resection in these patients in order to avoid all these complications mentioned above.

The potential increase in cost is nil because the procedure is quite similar and we use only one additional blue cartridge in order to close the duodenal stump.

Finally, we believe that laparoscopic resectional gastric bypass presents very similar results concerning the operative performance of the procedure, without significant increase of morbidity, mortality, early and late postoperative results, and therefore, it is an option for the surgical treatment of morbid obesity in countries with high risk of gastric carcinoma.

## References

1. Nguyen NT., Goldman C., Rosenquist CJ., Arango A, Cole CJ, Lee SJ, Wolfe BM. Laparoscopic versus open gastric by pass: a randomized study of outcomes quality of life and cost. *Ann. Surg.* 2001; 234: 279–291
2. Schauer PHR., Ikaramudin S., Gourasch W., Outcomes after laparoscopic Roux-en-Y for morbid obesity. *Ann. Surg.* 2000; 10:233–39
3. De Maria EJ., Sugeran HJ., Kellum JM., et las. Results of 281 consecutive total laparoscopic Roux-en-Y gastric bypasses to treat morbid obesity. *Ann. Surg.* 2002; 235:640–5, discussion 5–7
4. Podnos Y., Jimenez JC., Wilson SE., Stevens CM., Nguyen NT. Complications after laparoscopic gastric bypass. *Arch. Surg.* 2003; 138:957–61
5. Csendes A., Burdiles P., Papapietro K., Diaz JC., Maluenda F., Burgos AM., Rojas J. Results of gastric Bypass plus resection of the distal excluded gastric segment in patients with morbid obesity. *J. Gastrointest. Surg.* 2005;9:121–31
6. Schauer PhR. Open and laparoscopic surgical modalities for the management of obesity. *J. Gastrointest. Surg.* 2003; 7: 468–75
7. Bohdjalian A., Langer FB., Kranner A., Shakeri-Leidenmihler S., Zacher LJ., Prager G. Circular vs Linear stapled gastrojejunostomy in laparoscopic Roux-en-Y gastric bypass. *Obes. Surg* 2010;20:440–446
8. De Roover A., Detry O., Desaive C., Maweja S., Coimbra C., Honoré P., Meurisse M. Risk of upper gastrointestinal cancer after bariatric operations. *Obes. Surg* 2006;16:1656–61
9. Corsini DA., Simonetti CAM., Moreira G. Cancer in the excluded stomach 4 years after gastric bypass. *Obes. Surg* 2006;16:932–4
10. Escalona A., Guzman S., Ibañez L., Meneses L., Huete A., Solar A. Gastric cancer after Roux-en-Y gastric bypass. *Obes Surg* 2005;17:423–27
11. Heise K., Bertran E., Andia ME., Ferreccio C. Incidence and survival of stomach cancer in a high risk population of Chile. *World J. Gastroenterol.* 2009;15:1854–62
12. Bertuccio P., Chatenoud L., Levi F., Praud D., Feraly J., Negri E., Malvezzi M., La Vecchia C. Recent pattern in gastric cancer: a global overview. *Intl J. Cancer* 2009;125:666–73
13. Calderon ME., Csendes A., Ospina C., Lara A., Hodgson F. Evolucion del cáncer gástrico en 30 años. 1975–2005. *Rev Chil. Cir.* 2007;59:366–69

14. Ettinger JE., Ramos AC., Azaro E, Galvão-Neto MP, Mello CA., Galvão MS., Amaral PC. Staplerless laparoscopic gastric bypass: a new option in bariatric surgery. *Obes Surg.* 2006;16:638–45
15. Kasama K., Tagaya N., Kanehira E., Oshiro T., Seki Y., Kinouchi M., Umezawa A., Negishi Y, Kurokawa Y. Laparoscopic Sleeve Gastrectomy with Duodenojejunal Bypass: Technique and Preliminary Results. *Obes Surg.* 2009;19:1341–5
16. Savik TT., Taha O., Aasheim ET., Engstram M., Kristinsson J., Bjarkman S., Schou CF., Lanroth H., Mala T., Olbers T. Randomized clinical trial of laparoscopic gastric bypass versus laparoscopic duodenal switch for superobesity. *Br J Surg.* 2010;97:160–6
17. Weber M., Maller MK., Bucher T., Wildi S., Dindo D., Horber F., Hauser R., Clavien PA. Laparoscopic gastric bypass is superior to laparoscopic gastric banding for treatment of morbid obesity. *Ann Surg.* 2004;240:975–82; discussion 982–3.
18. Nyugen NT., Slone JA., Nyugen XM., Hartman JS., Hoyt DB. A prospective randomized trial of laparoscopic gastric bypass versus laparoscopic Adjustable Gastric Banding for the treatment of morbid obesity: outcomes, quality of life and costs. *Ann. Surg.* 2009; 250:631–641
19. Schauer PhR., Ikramuddin S. Laparoscopic surgery for morbid obesity. *Surg Clin N.A.* 2001;81: 1145–79
20. Puzifferri N., Austrheim-Smith IT., Wolfe BM., Wilson SE., Nguyen NT. Three-year follow-up of a prospective randomized trial comparing laparoscopic versus open gastric bypass. *Ann Surg.* 2006;243:181–8
21. Ruiz de Adana JC., Hernández Matas A., Hernández Bartolomeo M., Manzanedo Romero I, Leon Ledesma R., Valle Rubio A., López Herrero J., Limones Esteban M. Risk of gastrojejunal anastomotic stricture with multifilament and monofilament sutures after hand-sewn laparoscopic gastric bypass: a prospective cohort study. *Obes Surg.* 2009;19:1274–7
22. Bell BJ, Bour ES., Scott JD., Cobb WS., Carbonell AM. Management of complications after laparoscopic Roux-en-Y gastric bypass. *Minerva Chir.* 2009;64:265–76
23. Szomstein S., Kaidar-Person O., Naberezny K., Cruz-Correa M., Rosenthal R. Correlation of radiographic and endoscopic evaluation of gastrojejunal anastomosis after Roux-en-Y gastric bypass. *Surg. Obes. Relat. Dis.* 2006;2:617–21
24. Csendes. A., Burgos AM., Burdiles P. Incidence of anastomotic strictures after gastric bypass: a prospective consecutive routine endoscopic study 1 month and 17 months after surgery in 441 patients with morbid obesity. *Obes. Surg.* 2009;19:269–73
25. Maclean LD., Rhode BM., Nohr CW. Late outcome of isolated gastric bypass. *Ann Surg* 2000;231:524–28
26. Nguyen NT., Wilson SE. Complications of antiobesity surgery. *Nat. Clin. Pract Gastroenterol &hepatol.* 2007;4:138–147
27. Silecchia GF., Boru CE., Rossi M., Anselmino M., Morino M., Toppino M., Gaspari A., Gentileschi P., Tacchino R., Basso N. The use of fibrin sealant to prevent major complications following laparoscopic gastric bypass: results of a multicenter, randomized trial. *Surg. Endosc.* 2008; 22:2492–97
28. Csendes A., Burdiles P., Burgos AM., Maluenda F., Diaz JC. Conservative management of anastomotic leaks after 557 open gastric bypasses. *Obes Surg.* 2005;15:1252–6
29. Moczi E., Lattuada E., Zappa MA., Antonini I., Andreoli F., Badiali S., Roviario G. Failure of gastric bypass following several gastrointestinal hemorrhages. *Obes. Surg* 2010;20: 523–25
30. Nguyen NT., Longoria M., Chalifax., S., Wilson SE. Gastrointestinal hemorrhage after laparoscopic gastric bypass. *Obes. Surg* 2004;14:1308–12
31. Champion JK., Hunt T., DeLisle N. Laparoscopic banded gastroplasty and Roux-en-Y gastric bypass in morbid obesity. *Obes Surg* 1999;9:123
32. Cucchi SG., Pories WJ., Morgan EJ. Gastro-gastro fistulas: a complication of divided gastric bypass surgery. *Ann. Surg.* 1995;221:387–91
33. Csendes. A., Burgos AM., Altuve J., Bonacic S. Incidence of marginal ulcer 1 month and 1–2 years after gastric bypass: a prospective consecutive endoscopic evaluation of 442 patients with morbid obesity. *Obes. Surg.* 2009;19:135–38
34. Defoort B., Dillemans B., Mulier J., Cabooter M. Marginal Ulcer after Roux-en Y gastric Bypass. *Obes. Surg.* 2008; 18: 432–185 (Abst 11)
35. Braley SC., Nguyen NT., Wolfe BM. Late gastrointestinal hemorrhage after gastric bypass. *Obes. Surg.* 2002;12:404–7
36. Dillemans B., Defoort B., Mulier J. Laparoscopic management of a gastro-gastric fistula after laparoscopic Roux-en-Y gastric bypass. *Obes. Surg* 2008;18: 432–485. (Abst112)
37. Kellum JM, DeMaria EJ, Sugerman HJ. The surgical treatment of morbid obesity. *Curr Probl Surg.* 1998;35:791–858
38. Flum DR., Salem L., Elrod JA., Dellinger EP., Cheadle A., Chan L. Early mortality among Medicare beneficiaries undergoing bariatric surgical procedures. *JAMA* 2005;294:1903–8
39. Nguyen NT. Silver M, Robinson M, Needleman B, Hartley G, Cooney R, Catalano R, Dostal J, Sama D, Blankenship J, Burg K, Stemmer E, Wilson SE. Results of a national audit of bariatric surgery performed at academic centers: a 2004 University Healthsystem Consortium benchmarking project. *Arch Surg.* 2006; 141:445–9; discussion 449–50
40. Kuga R, Safatle-Ribeiro AV, Faintuch J, Ishida RK, Furuya CK Jr, Garrido AB Jr, Ceconello I, Ishioka S, Sakai P. Endoscopic findings in the excluded stomach after Roux-en-Y gastric bypass surgery. *Arch Surg.* 2007;142:942–6
41. Rajjman I., Strother V., Donegan W. Gastric cancer after gastric bypass for obesity. *J. Clin. Gastroenterol.* 1991;13:191–4
42. Lord RV., Edwards P., Coleman M. Gastric cancer in the bypassed segment after operation for morbid obesity. *Aust N.Z. J. Surg.* 1997;67:580
43. Inoue H., Rubino F., Shimada y., Lindner V., Inoue M., Riegel Ph., Marescaux J. Risk of gastric cancer after Roux-en-Y gastric bypass. *Arch Surg.* 2007;142:947–53
44. De Roover A., Detry O., de Leval L., Coimbra C., Desaive C., Honore P., Meurise M. Report of two cases of gastric cancer after bariatric surgery: lymphoma of the bypassed stomach after Roux-en-Y gastric bypass and gastrointestinal stromal tumor (GIST) after vertical banded gastroplasty. *Obes, surg* 2006;16:928–931
45. Khitin L., Roses RE., Birkett Dh. Cancer in the gastric remnant after gastric bypass.: a case report. *Curr Surg.* 2003;60:521–23
46. Babor R., Booth M., Adenocarcinoma of the gastric pouch 26 years after loop gastric bypass. *Obes. Surg* 2006;16:935–8
47. Flickinger EG, Sinar DR., Pories WJ., Sloss RR, Park HK, Gibson JH. The bypassed stomach. *Am. J. Surg* 1985;149:151–6
48. Saflate-Ribeiro AV., Ribeiro U Jr., Reynolds JC. Gastric stump cancer: what is the risk? *Dig Dis.* 1998;16:159–68
49. Sundbom M., Hedenström H., Gustavsson S. Duodenogastric bile reflux after gastric bypass: A cholescintigraphic study. *Dig Dis Sciences* 2002;47:1891–1896
50. Chao Zh., Zhan Kui Liu Pei-Wu Yu. Effects of bile reflux and intragastric microflora changes on lesions of remnant gastric mucosa after gastric operation. *World J. Gastroent* 2004;10:1537–39
51. Bestman R., Valk J., De Clerck S., Hendrickh L. Laparoscopic reversal of gastric Bypass. *Obes. Surg* 2008;18: 432–485. (Abst115)