



SURGICAL TECHNIQUE

Laparoscopic radical cystectomy with extracorporeal creation of a ‘‘Y’’ shaped orthotopic ileal neobladder using non-reabsorbable mechanical suture (Fontana)[☆]

O.A. Castillo^{a,b,c,*}, R. Campos^a, I. Vidal^a, A. Fonerón^a, G. Rubio^a, E. Landerer^{a,b}, R. Gómez^a

^a Departamento de Urología, Clínica Indisa, Santiago, Chile

^b Facultad de Medicina, Universidad Andrés Bello, Santiago, Chile

^c Facultad de Medicina, Universidad de Chile, Santiago, Chile

Received 24 September 2010; accepted 4 November 2010

Available online 6 August 2011

KEYWORDS

Orthotopic
neobladder;
Radical cystectomy;
Vesical cancer

Abstract

Introduction: We describe the technique and present the preliminary results of the laparoscopic radical cystectomy technique with the extracorporeal creation of a ‘‘Y’’ shaped ileal orthotopic neobladder using non-absorbable mechanical suture (Fontana).

Materials and method: We describe the technique step by step and present a series of 15 patients who underwent this surgery between November 2005 and August 2009, with special emphasis on the duration of the surgery, urinary diversion time, intraoperative and postoperative complications, daytime and night time continence and the frequency of postoperative micturition.

Results: The mean follow-up of the series was 24 months (6–32). The mean duration of surgery was 280 (range 210–345) min and the mean urinary diversion time was 54.5 (range 40–75) min. There were no intraoperative complications and the average hospitalization time was 7 (range 5–15) days. During the follow-up, there were 5 late postoperative complications, 2 cases of urinary infection with good response to antibiotic treatment and 3 uretero-neovesical anastomosis strictures, which were treated with percutaneous balloon dilation, with a good functional result. No lithiasis was found in the neobladder. Complete daytime continence was obtained in 13/14 patients (92.9%) and complete nighttime continence in 6/14 (42.9%). One patient (6.7%) required clean intermittent self-catheterization as the patient did not micturate spontaneously.

Conclusions: The creation of a ‘‘Y’’ shaped ileal orthotopic neobladder using non-absorbable mechanical suture is a feasible, fast and safe technique and it provides promising functional results. Further follow-up is required to determine its long-term results.

© 2010 AEU. Published by Elsevier España, S.L. All rights reserved.

[☆] Please cite this article as: Castillo OA, et al. Cistectomía radical laparoscópica con confección extracorpórea de neovejiga ortotópica ileal en forma de ‘‘Y’’ usando sutura mecánica no reabsorbible (Fontana). Actas Urol Esp. 2011;35:296–301.

* Corresponding author.

E-mail address: octavio.castillo@indisa.cl (O.A. Castillo).

PALABRAS CLAVE

Neovejiga ortotópica;
Cistectomía radical;
Cáncer vesical

Cistectomía radical laparoscópica con confección extracorpórea de neovejiga ortotópica ileal en forma de "Y" usando sutura mecánica no reabsorbible (Fontana)

Resumen

Introducción: se describe la técnica y se presentan los resultados preliminares de la técnica de cistectomía radical laparoscópica con confección extracorpórea de neovejiga ortotópica ileal en forma de "Y", usando una sutura mecánica no reabsorbible (Fontana).

Material y método: se describe paso a paso la técnica y se presenta una serie de 15 pacientes sometidos a esta cirugía entre noviembre de 2005 y agosto de 2009, con especial énfasis en el tiempo de cirugía, tiempo de derivación urinaria y la frecuencia miccional postoperatoria.

Resultados: la mediana de seguimiento de la serie es de 24 meses (6-32). El tiempo quirúrgico medio fue 280 (rango: 210-345) minutos y el tiempo medio de la derivación urinaria fue 54,5 (rango: 40-75) minutos. No se presentaron complicaciones intraoperatorias y el tiempo promedio de hospitalización fue de 7 días (rango: 5-15). Durante el seguimiento se presentaron 5 complicaciones postoperatorias tardías, dos cuadros de infección urinaria con buena respuesta al tratamiento antibiótico y tres estenosis de la anastomosis uretero-neovesical, que se han manejado con una dilatación percutánea con balón con un buen resultado funcional. No se han encontrado litiasis en la neovejiga. Se obtuvo continencia diurna completa en 13 de 14 pacientes (92,9%) y nocturna completa en 6 de 14 (42,9%). Un paciente (6,7%) precisa autosondaje limpio intermitente por no presentar una micción espontánea.

Conclusiones: la neovejiga ortotópica ileal en forma de "Y" usando una sutura mecánica no reabsorbible es una técnica factible, rápida, segura y que permite resultados funcionales prometedores. Se necesita mayor seguimiento para determinar sus resultados a largo plazo.

© 2010 AEU. Publicado por Elsevier España, S.L. Todos los derechos reservados.

Introduction

Radical cystectomy currently continues to be the standard treatment for organ-confined muscle-invasive bladder cancer¹. Since the beginning of this surgery, the challenge has been to be able to perform urinary diversion with low surgical and post-surgical morbidity and to protect the upper urinary tract. There is currently no argument on whether the urinary diversion of choice should be an orthotopic neobladder, as it offers better quality of life than non-orthotopic and non-continent reservoirs.

From when Bricker described his ileal conduit urinary diversion² at the beginning of the decade of the 1950s, this simple and reproducible technique became the most widely used diversion in relation to which other types of diversions had to be compared. In the late 1970s, Camey and Le Duc³ described the first experience with the use of an orthotopic neobladder (Camey I), performed with a non-detubularized segment and, therefore, with peristaltic activity, which did not achieve good functional results. It was not until 1988 when Hautmann et al.⁴ described the execution of an orthotopic detubularized ileal and low-pressure reservoir, with good functional results with daytime continence rates above 90%. In 1989, Studer et al.⁵ described a new technique using a long, afferent and isoperistaltic ileal segment for the construction of a neobladder, with good functional results. This technique has become one of the most used today.

In 1990, Camey⁶ described a modification (Camey II) of his original technique, detubularizing the ileal segment and eliminating its peristaltic activity, thus improving its functional results. Since then, different variations and techniques have been described for performing this type of

urinary diversion in order to reduce operating time, reduce postoperative complications and improve the quality of life of these patients.

Fontana et al.⁷ recently published a new technique for creating an extracorporeal "Y" shaped orthotopic neobladder in an "easy, fast and reliable" manner, using non-reabsorbable mechanical sutures in less surgical time, with an acceptable incidence of complications and with good functional outcome. The aim of this paper is to describe the surgical technique step by step and to present the preliminary results of our series of patients that underwent laparoscopic radical cystectomy with extracorporeal creation of a "Y" shaped orthotopic ileal neobladder using non-reabsorbable mechanical sutures.

Materials and methods

Between January 2000 and August 2009, a total of 97 patients had laparoscopic lymphadenectomy and radical cystectomy at our institution, all performed by a single surgeon (OAC). Between November 2005 and August 2009, an extracorporeal orthotopic neobladder was created in 35 of these patients and a "Y" shaped orthotopic ileal neobladder was created in 15 of them using non-reabsorbable mechanical sutures.

The surgical indication was transitional cell carcinoma of the bladder with muscle invasion (T2a classification according to TNM 2002) in 13 patients (86.7%) and high-grade non-muscle-invasive bladder tumor (T1-G3), which recurred after several transurethral resections of the bladder and complementary treatment with BCG and mitomycin

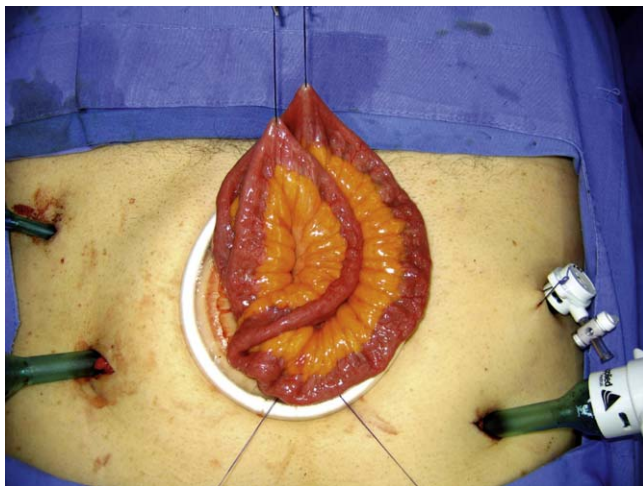


Fig. 1 Segment of ileum exteriorized through 6 cm midline incision.

in two patients (13.3%). All patients were examined with computerized axial tomography (CAT scan) of the chest, abdomen and pelvis, showing a preoperative classification of NOMO.

Only patients with good renal function, who had no severe co-morbidity and could fend for themselves, were considered for the construction of an orthotopic neobladder.

Surgical technique

Radical cystectomy and lymphadenectomy are performed laparoscopically, in accordance with the technique previously published by the author⁸. Upon completion of the cystectomy, an 8 cm infraumbilical incision is made through which to remove the bladder and the prostate. An Alexis separator (Applied Medical[®]) is placed through the same incision. Subsequently, a 40 cm segment of terminal ileum is exteriorized and isolated, at approximately 25 cm from the ileocecal valve (Fig. 1). Intestinal continuity is restored by applying Monocryl 5.0 (Ethicon[®]) continuous sutures in two planes.

The isolated intestinal segment is laid out in a ‘‘Y’’ shape, with two 15 cm central segments and two 5 cm chimneys. The two central segments are placed parallel and their antimesenteric edge is detubularized using a linear mechanical non-reabsorbable suture (Ethicon[®]) stapler inserted through an opening made in the lowest part of the neobladder (Fig. 2).

Subsequently, with both ureters sectioned and released up to the level of the iliac vessels, both chimneys are spatulated on their anterior side and anastomosed to the posterior side by means of Vicryl 5.0 (Ethicon[®]) sutures. The ureteral catheters placed previously on both chimneys are exteriorized through the neobladder wall, and then both ends of the chimneys are closed with 5.0 Vicryl running sutures. This done, the reservoir is once again placed inside the abdominal cavity and the incision through which the specimen was extracted is closed and the pneumoperitoneum is restored (Fig. 3).

The surgery is completed by performing laparoscopic urethro-neobladder anastomosis by applying 3.0 polyglactin

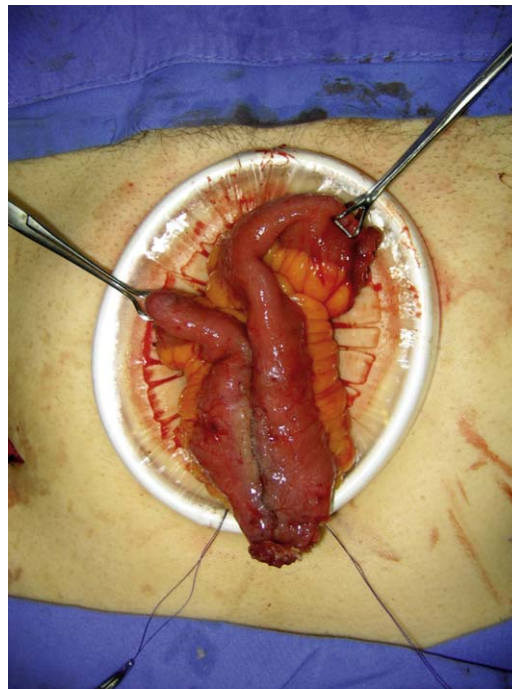

Fig. 2 Neobladder shape after placement of two to three lines of staples.

suture with a UR-6 needle, placing 6–8 separated sutures to achieve impermeable anastomosis. Subsequently, a 22 Fr Foley catheter is placed and the ureteral catheters and taps are exteriorized through the trocar incisions. The ureteral catheter is kept for 14 days. Postoperative follow-up consisted of regular monitoring of postoperative electrolytes, urinalysis and renal function, monthly cystoscopy, chest radiography, abdominopelvic CT and bone scan every 6 months post-surgery (Fig. 4).

The following parameters were considered for this article: the time of surgery, time of urinary diversion, intra-operative and postoperative complications, continence and

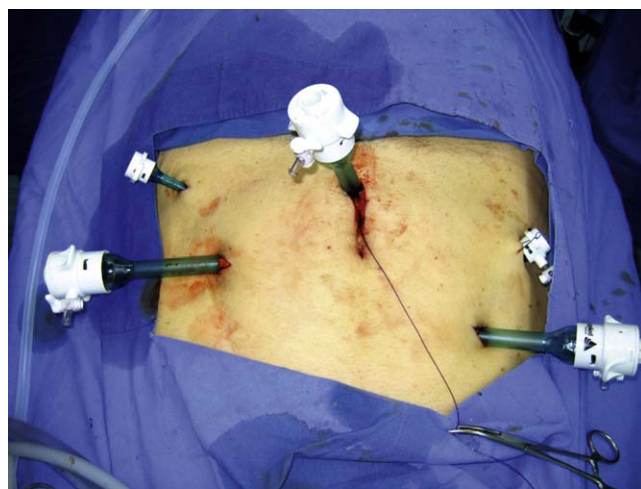


Fig. 3 Appearance of the surgical incision and of the trocars prior to laparoscopic neovesicourethral anastomosis.

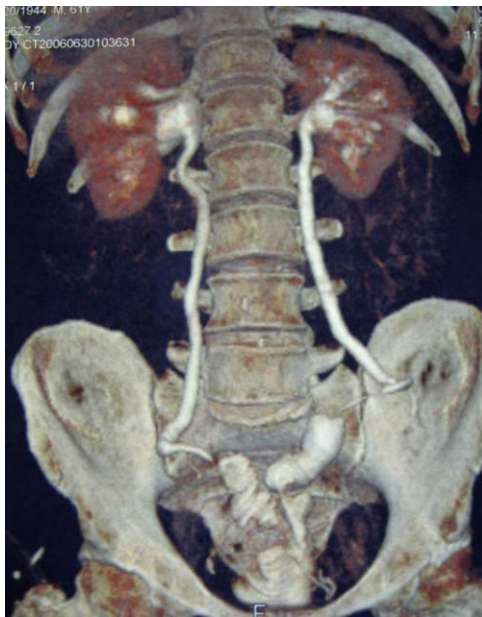

Fig. 4 Control CT scan showing the protection of the upper tract and the shape of the neobladder.

daytime and nighttime urinary frequency. Continence was assessed with a questionnaire and was classified as complete (dry), partial (use of a single pad during the day or at night) and incontinent (using more than one pad during the day or at night). Furthermore, based on the same parameters described above, we compared our series with the other neobladders created extracorporeally and manually by the same author.

Results

The median follow-up of the series was 24 (range 6–32) months. All patients were male; the mean age was 60.8 (range 49–82) years, the mean body mass index (BMI) was 29.25 kg/m² (range 22.5–33.6 kg/m²), and the American Association of Anesthesiologists (ASA) score was I in 4 patients (26.7%) and II in 11 (73.3%). Of these, 6 patients had associated disease and three patients had undergone surgery, one of these being partial cystectomy.

The overall mean operative time in the series was 280 (range: 210–345) min; the mean urinary diversion time was 54.5 (range 40–75) min. A breakdown of the surgical time of each patient is given in Table 1. There were no intraoperative complications, and average bleeding was 125 ml (range 50–300), such that no patient required a blood transfusion. The mean hospital stay was 7 (range 5–15) days.

There were five late postoperative complications. Two took place a month after surgery and consisted of urinary infections (13.3%), which were treated solely with antibiotics and had good response. Three were of stenosis of the uretero-neovesical anastomosis (20%), which was managed with percutaneous balloon dilatation with good functional results. No patient suffered neovesical lithiasis during follow-up, and no exposed clips were observed in the endoscopic control. We also noted that the mechanical suture line was completely covered by intestinal mucosa

(Fig. 5), and there was no deterioration of renal function in any patient of the series during follow-up.

In 3 patients the pathological stage of the specimen was higher than that of the preoperative clinical classification and lymphadenectomy in one patient was positive. These patients received 6 cycles of cisplatin and gemcitabine; there is currently no evidence of disease. There were no positive margins in the surgical specimens.

Typically, urinary frequency is on average every 4–5 h. Thirteen of fourteen patients (92.9%) had complete daytime continence and one patient had partial continence. Six of fourteen patients (42.9%) had complete nocturnal continence and 8 had partial nocturnal continence. One patient of 15 (6.7%) was managed with clean intermittent self-catheterization due to a hypercontinent neobladder and urinary retention.

Discussion

There are currently no discrepancies regarding the fact that laparoscopic radical cystectomy offers significant benefits, both surgical and postoperative, with respect to traditional open surgery. These advantages include lower blood loss, lower analgesic requirement by the patient, shorter hospitalization, more rapid return to daily activities and a better aesthetic appearance^{8–12}. With a medium-term follow-up, there is so far no evidence that it can change the oncological objectives achieved with traditional open surgery^{10,11}.

In this regard, both Basillote et al.¹², and Castle et al.⁸ showed in their respective work that laparoscopic radical cystectomy with extracorporeal creation of a neobladder by means of a Pfannenstiel incision, the former, and an average incision of 6–8 cm, the latter, provide the patient with the benefits of laparoscopic surgery, all without increasing surgical time in comparison with traditional open surgery.

The purpose of an orthotopic neobladder is to endeavor to give the patient the best quality of life possible by trying to provide a continent reservoir, appropriate voiding

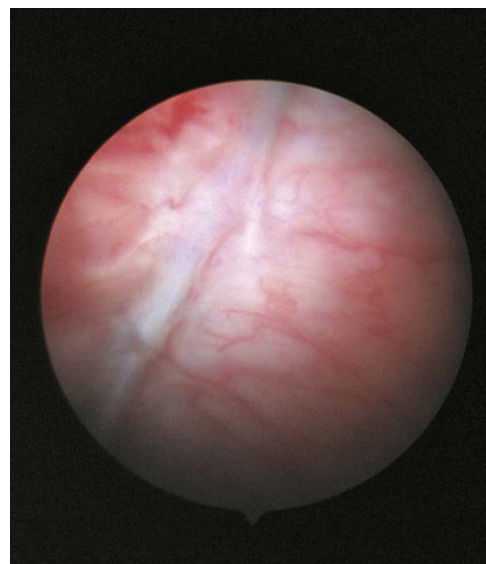

Fig. 5 Endoscopic image showing the line of staples covered by intestinal mucosa.

Table 1 Surgical time employed for each case in the different stages of the procedure, expressed in minutes.

No.	Type of surgery	Cystectomy time	Lymphadenectomy time	Diversion time	Anastomosis time	Total time
1	Cystoprostatectomy	60	75	50	60	300
2	Radical cystectomy	45	55	70	35	270
3	Radical cystectomy	60	80	50	30	300
4	Radical cystectomy	40	65	75	40	300
5	Radical cystectomy	41	44	42	35	220
6	Radical cystectomy	50	44	42	25	240
7	Cystoprostatectomy	90	80	60	35	345
8	Radical cystectomy	45	60	55	20	300
9	Cystoprostatectomy	50	60	50	25	300
10	Radical cystectomy	65	72	50	30	280
11	Radical cystectomy	70	65	60	28	310
12	Cystoprostatectomy	90	120	60	30	310
13	Cystoprostatectomy	40	100	55	30	300
14	Radical cystectomy	40	100	30	20	240
15	Radical cystectomy	60	65	70	50	300

frequency and avoiding the appearance of complications that may affect the upper urinary tract and kidney function. For this reason, various orthotopic neobladder techniques have been developed using intestinal segments and different materials, to which modifications have been added to optimize their performance and to reduce complications²⁻⁷. With regard to the intestinal segment to be used, there seems to be some consensus on the convenience of using terminal ileum and condensing the length to be used, thereby reducing metabolic abnormalities and preventing the formation of a loose bag that functions as a poor reservoir, preventing appropriate spontaneous voiding¹³.

In 2004, Fontana et al.⁷ published a new technique for the creation of a "Y" shaped orthotopic neobladder using non-reabsorbable sutures. It requires less surgical time and has a low complication rate, functional results and an incidence of lithiasis of only 6%. Subsequently, Abreu et al.¹⁴ published their series of two cases, in which they reproduced the Fontana technique with similar surgical results; however, they did not describe the functional results as there was no follow-up.

In our series, surgical time is somewhat lower in the creation of the neobladder (54.5 min) than that of Fontana and Abreu, which was 90 and 67.5 min respectively, without any intra-operative complications. Furthermore, on comparing the creation times of a "Y" shaped neobladder with an orthotopic neobladder created extracorporeally but manually by the same author⁸, our time is also less (54.5 min vs. 73.3 min) (Table 2).

One of the postoperative complications of orthotopic neobladder, as regards both its impact and its management, is ureteral stricture. One of the advantages of this technique is that given the "Y" shape of the reservoir, there are two non-detubularized segments that approximate the ureters, decreasing their mobilization, avoiding crossing of the left ureter under the mesosigma, and thus helping to reduce its dissection and therefore ischemia. There is also less risk of ureteral angulation, which helps to reduce the risk of stricture development.

When performing uretero-neovesical anastomosis, a point of contention is whether or not to apply an antireflux technique. Some authors report that the antireflux technique reduces the risk of bacteriuria and pyelonephritis, preserving the patency of the upper tract without it necessarily entailing a higher risk of stenosis of the anastomosis^{15,16}. On the other hand, Pantuck et al.¹⁷ described an increase in the incidence of stenosis of the uretero-neovesical anastomosis when an antireflux technique is applied. Furthermore, this same study shows that the presence of ureteral reflux in a neobladder with low intravesical pressure does not increase the risk of pyelonephritis, lithiasis or renal failure. Fontana et al. reported a 4% incidence of stenosis using a direct technique without an antirefluxing mechanism⁷. We also performed direct ureteral anastomosis with ample spatulation of the ureter and anastomosis to the intestinal segment. We believe that this further decreases the risk of developing ureterointestinal stenosis.

Table 2 Comparative data on surgical times in other similar series.

Author	Diversion	Suture	Total diversion time (min)
This series	"Y" neobladder	Non-reabsorbable mechanic	54.5 (40-75)
Fontana et al. ⁸	"Y" neobladder	Non-reabsorbable mechanic	90 (70-110)
Abreu et al. ¹⁴	"Y" neobladder	Non-reabsorbable mechanic	67.5 (65-70)
Castillo et al. ⁸	Studer type neobladder	Extracorporeal manual	73.3 (40-90)

Without doubt, the most controversial point of the technique, described by Fontana et al., is the use of non-absorbable mechanical titanium staples, which could increase the risk of stone formation in the neobladder⁷. In this regard, the evidence published suggests that titanium is well tolerated in the urinary tract, as it has a natural resistance to corrosion, low toxicity and excellent biocompatibility with body fluids and tissues¹⁸. In their work on reconstructive surgery of the upper urinary tract (pyeloplasty) using non-absorbable titanium staples, Grubb et al.¹⁹ did not observe any stone formation in their series, with a median follow-up of 27 months. On the other hand, Anderson et al.²⁰ published an incidence of lithiasis of 50% with use of non-absorbable titanium staples in an experimental study on urinary diversion performed in pigs. The incidence of calculi in the neobladder using non-reabsorbable material, described by Fontana et al., is of an acceptable 6%⁷. In the monthly endoscopic follow-up of our patients, we did not encounter any incidence of lithiasis and noted the absence of exposed clips. In all the cases, we found that the mechanical suture line was completely covered by intestinal mucosa.

Furthermore, a "Y" shaped neobladder can be created completely intracorporeally because it is easy to perform. In fact, literature already contains a clinical case published on a laparoscopic radical cystectomy with the complete intracorporeal creation of a "Y" shaped orthotopic ileal neobladder using non-reabsorbable mechanical suture¹⁸, although the operative time was 10 h, which at least makes its performance debatable.

Data for urinary frequency and continence in our series are similar to those described by Fontana et al., and to those of other types of ileal neobladders⁵⁻⁷. We believe that laparoscopic radical cystectomy with the extracorporeal creation of a "Y" shaped orthotopic neobladder applying non-reabsorbable mechanical suture is, as described by its author, fast, easy, reproducible and reliable. The medium and long-term follow-up of this technique is still to be determined, with the aim of assessing the incidence of lithiasis and uretero-neovesical stenosis, as well as to better understand its functional results.

Conflict of interest

The authors declare that they have no conflict of interest.

References

- Stein JP. Contemporary concepts of radical cystectomy and the treatment of bladder cancer. *J Urol*. 2003;169:116–7.
- Bricker E. Bladder substitution after pelvis evisceration. *Surg Clin North Am*. 1950;30:1511–21.
- Camey M, Le Duc A. Liéntérocistoplastie avec cystoprostatectomie totale pour cancer de vessie. *Ann Urol (Paris)*. 1979;2:114.
- Hauttmann RE, Egghart G, Frohnenberg D, Miller K. The ileal neobladder. *J Urol*. 1988;39:139.
- Studer UE, Ackermann D, Casanova GA, Zinng EJ. Three years' experience with an ileal low pressure bladder substitute. *Br J Urol*. 1989;63:43–52.
- Camey M. Detubularized U-shaped cystoplasty (Camey II). *Curr Surg Technol*. 1990;3:1.
- Fontana D, Bellina M, Fasolis G, Frea B, Scarpa RM, Mari M, et al. Y-neobladder: an easy, fast, and reliable procedure. *Urology*. 2004;63:699–703.
- Castillo O, Cabello R, Briones M, Hernández C. Cistectomía radical laparoscópica. *Actas Urol Esp*. 2006;30:531–40.
- Gupta NP, Gill IS, Fergany A, Nabi G. Laparoscopic radical cystectomy with intracorporeal ileal conduit diversion: five cases with a 2-year follow-up. *BJU Int*. 2002;90:391–6.
- Puppo P, Naselli A. Laparoscopic radical cystectomy. *Curr Urol Rep*. 2005;6:106–8.
- DeGer S, Peters R, Roigas J, Wille AH, Tuerk IA, Loening SA. Laparoscopic radical cystectomy with continent urinary diversion (rectosigmoid pouch) performed completely intracorporeally: an intermediate functional and oncologic analysis. *Urology*. 2004;64:935–9.
- Basilote JB, Abdelshehid C, Ahlering TE, Shanberg AM. Laparoscopic assisted radical cystectomy with ileal neobladder: a comparison with the open approach. *J Urol*. 2004;172:489–93.
- Hauttmann RE, de Petriconi R, Gottfried HW, Kleinschmidt K, Mattes R, Pais TH. The ileal neobladder: complications and functional results in 363 patients after 11 years of follow-up. *J Urol*. 1999;161:422–7.
- Abreu SC, Messias FI, Argollo RS, Guedes GA, Araujo MB, Fonseca GN. Laparoscopic assisted radical-cystoprostatectomy with Y-shaped orthotopic ileal neobladder constructed with non-absorbable titanium staples through a 5 cm pfannensteil incision. *Int Braz Urol*. 2005;31:362–7.
- Abol-Enein H, Ghoneim M. Functional results of orthotopic ileal neobladder with serous-lined extramural ureteral reimplantation: experience with 450 patients. *J Urol*. 2001;165:1427–32.
- El-Bahnasaway MS, Osman Y, Gomha MA, Shaaban AA, Ashamallah A, Ghoneim MA. Nocturnal enuresis in men with an orthotopic ileal reservoir: urodynamic evaluation. *J Urol*. 2000;164:10–3.
- Pantuck AJ, Han K, Perrotti M, Weiss RE, Cummings KB. Ureteroenteric anastomosis in continent urinary diversion: long-term results and complications of direct versus nonrefluxing techniques. *J Urol*. 2000;163:450–5.
- Abreu SC, Fonseca GN, Cerqueira JB, Cistectomía MS, Costa MR, Machado PC. Laparoscopic radical cystectomy with intracorporeally constructed Y-shaped orthotopic ileal neobladder using non-absorbable titanium staples exclusively. *Urology*. 2005;66:657.
- Grubb RL, Sundaram CP, Yan Y, Chen C, McDougall EM, Clayman RV. Use of titanium staples during upper tract laparoscopic reconstructive surgery: initial experience. *J Urol*. 2002;168:1366.
- Anderson KR, Fadden PT, Kerlb K, McDougall EM, Clayman RV. Laparoscopic assisted continent urinary diversion in the pig. *J Urol*. 1995;154:1934.