



ELSEVIER



Functional results of burned hands treated with Integra[®]

Alvaro Cuadra^{a,*}, Gerardo Correa^b, Ricardo Roa^a, Jose Luis Piñeros^a,
Hernán Norambuena^c, Susana Searle^d, Rocío Las Heras^e,
Wilfredo Calderón^a

^a Plastic Surgery and Burn Unit, Hospital del Trabajador de Santiago, Chile

^b Rehabilitation Unit, Hospital del Trabajador de Santiago, Santiago, Chile

^c Universidad de Chile, Santiago, Chile

^d Pontificia Universidad Católica de Chile, Santiago, Chile

^e Universidad del Desarrollo, Santiago, Chile

Received 29 July 2011; accepted 5 September 2011

KEYWORDS

Hand;
Burns;
Dermal regenerator;
Functional evaluation

Summary *Introduction:* Dermal substitutes, such as Integra[®] introduced as a new alternative to our surgical arsenal and its use in burn treatment, in both acute and chronic phases, have gained great importance.

Objective: The aim of the experiment is to describe the results of the functional evaluation of patients with burned hands treated with Integra[®] in both acute and chronic phases.

Material and Methods: A retrospective review of a transversal cohort. Patient characteristics evaluated were sociodemographic characteristics, burn mechanism, burn extension and depth, treatments received previous to Integra[®] and complications related to its use. Clinical and photographic evaluations were performed evaluating skin elasticity, range of articular movement, prehensile strength, pain and functional evaluation using the validated 400 Point Evaluation Test.

Results: A total of 17 burned hands in 14 right-handed patients, were treated with Integra[®], three being bilateral hand burns. Eleven were treated in the acute phase and in nine in the scar reconstruction phase. Range of articular motion was complete in 15 of 17 hands. In 88% of the hands, flexible skin coverage was achieved. No statistically significant difference was observed in prehension strength of the burned hand versus the contralateral non-burned hand. Sixteen hands had a painless evolution. The 400 Point Evaluation score was $92.8 \pm 6.3\%$ (80 – 100%). Nearly four-fifths (79%) of the patients returned to normal active working activities.

© 2011 British Association of Plastic, Reconstructive and Aesthetic Surgeons. Published by Elsevier Ltd. All rights reserved.

* Corresponding author. Ramón Carnicer 185, Providencia, Santiago, Chile. Tel.: +56 2 3853000.

E-mail addresses: acuadra@hts.cl, acuadrac@gmail.com (A. Cuadra).

Traumatic hand injuries are a challenge for plastic surgeons because the lack of adequate coverage of this anatomically important segment can lead to retractile scars causing important functional limitations and subsequent disability. Multiple alternatives for hand coverage are available, from simple partial (STSG) and full-thickness skin grafts (FTSG), through local and distant or even free flaps. In the past few years, dermal substitutes, such as Integra® and Alloderm®, associated to the use of STSG and keratinocyte cultures, were introduced as new alternatives to our surgical arsenal. The special characteristics of the thin, mobile and supple skin of the dorsum of the hand, allowing a wide range of frequent movements, together with the highly specialised characteristics of palmar skin, which requires both flexibility and resistance, makes this coverage even more complex. The use of local or distant flaps does not re-establish all these specific features. Since its introduction, Integra® (Dermal Regeneration Template, Ethicon, Inc., Somerville, NJ, USA) has gained importance within our therapeutic arsenal for the coverage of dermal defects of diverse aetiology. Among these, its use in burn treatment, in both acute and chronic phases¹⁻⁴ is worth mentioning. In deep burns of the hand, FTSGs are still considered the gold standard. Literature reports on the use of Integra® in hand burns are scarce; for this reason, we find it relevant to report our experience with the use of this dermal regenerator.

To study the characteristics of cutaneous coverage achieved using Integra®, a transversal cohort study was designed. The main objective is to describe the results of the functional evaluation of patients with burned hands treated with Integra® in both acute and chronic phases. The secondary objective is to describe clinical characteristics of this series of patients treated for burned hands.

Methods

A retrospective review of a transversal cohort is presented. The study was performed in the Burn Unit of the Hospital del Trabajador, in Santiago, Chile, a national referral centre for work-related injuries. Patients suffering deep hand burn injuries as a consequence of a work-related accident, treated with Integra® between March 2001 and April 2007 in our Burn Unit were evaluated. Burns caused by melted metal, fire, hot water and chemical products treated in both the acute or chronic phases were included. Patients with electric, graze and degloving burns, and crush injuries were excluded, as were patients with previous history of hand injuries.

Patients: Patient characteristics evaluated were socio-demographic characteristics, burn mechanism, burn extension and depth, treatments received previous to Integra® and complications related to use of Integra®.

Integra® Placement: In patients treated for deep burns in the acute phase, negative tissue cultures and adequate local vital tissue conditions were advocated before the use of Integra®. Periodic change in wound dressing was released where local complications related to Integra® were evaluated (infection and haematomas). Between the third and fourth week after Integra® placement, the superficial Silastic® cover was removed and grafting was released with

thin, 0.13-mm fenestrated split-thickness auto grafts. In the case of chronic patients, the scar was removed until a vital plane was reached, over which Integra® was placed. The postoperative care and second phase grafting process was identical to the treatment of the acute cases.

Postoperative Care: During this period, rehabilitation consisted of treatment of oedema, with extremity elevation over the mid thoracic heart line, with emphasis on adjusting and positioning the extremity with bandages and special care of thumb abduction, maintaining anatomic position of the hand in the intrinsic plus position. Physical therapy consisting of protected active and passive mobilisation of the extremity was also performed twice a day. On the seventh postoperative day, once graft integration was assured, physical therapy was initiated, and occupational therapists started on stimulation programmes. The postoperative rehabilitation programme was identical for both groups of patients. An integral individualised rehabilitation programme was designed, depending on both extension and specific region of the hand burned, as well as psychosocial characteristics of the patient. The program included physical therapy, occupational therapy and mental health support. The objective was to recuperate hand functionality as well as psychological wellness and reinstate the injured worker into the workplace.

Functional Evaluation: Clinical and photographic evaluations were performed, as well as revision of the clinical files for each case by an independent evaluator (rehabilitation doctor). Skin elasticity (pliability) was evaluated by taking the skin under study between two fingers and lifting it. Range of articular movement was analysed for each segment of the hand. Hand prehensile strength was evaluated by a manual JAMAR® dynamometer (Dynatronics Co., Salt Lake City, UT, USA) (Figure 1). Pain and sensibility over the affected zones was measured through the Numerical Rating Scale (NRS). The hand was photographed for all basic functional positions as well as to document pliability. Evaluations were performed with verbal consent of all patients.

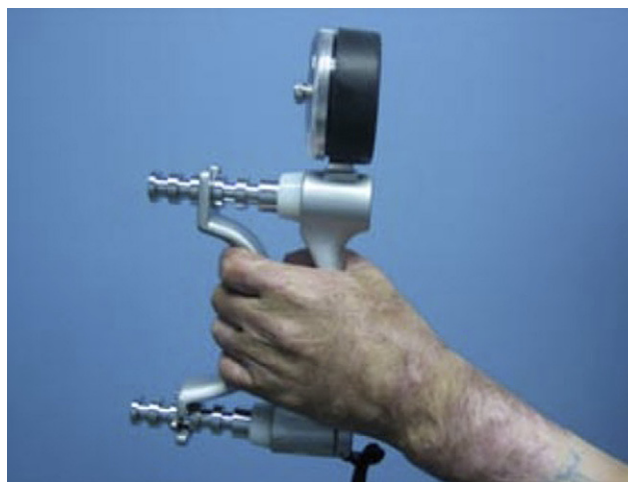


Figure 1 Hand prehension strength evaluated measured with a JAMAR® dynamometer.

400 Point Evaluation Test

Functional evaluation of the hand was performed using a standardised test which consists in observation of the injured hand while rehearsing 57 daily-life situations. This evaluation is composed of four tests: motility of the hand, prehension strength, prehension and object displacement with one hand as well as bimanual hand function. Each item is classified with a score from 0 to 100 points. Each individual test score is added and divided by the maximum score (400) and then multiplied by 100 so as to express the results in term of percentage, 0% being complete loss of hand functionality and 100% normal functionality (5,6).

Laboural Situation Evaluation: All patients were active workers prior to their accidents. Comparisons were made between the workers' pre- and post accident occupation.

Statistics: For statistic data analysis descriptive statistics and Wilcoxon test were used, defining statistic significant values $p < 0.05$.

This study was approved by the ethics committee at the Hospital del Trabajador de Santiago. An informed verbal consent of all patients was obtained prior to evaluation.

Results

The series was composed of 14 patients, 11 male and three female, with an average age of 31.8 years (range 19–68 years), all right handed. Eleven patients presented only one hand burn (eight right hands; three left hands), and three patients had bilateral burns. The series presents a total of 17 burned hands treated with Integra® coverage. In 11 cases, the burn mechanism was a fire accident, two cases were due to melted metal and one case due to chemical burns. Twelve patients presented burns on the dorsum of the hand, of which three also presented associated burns of the fingers, excluding the thumb. Nine patients (11) had over 20% of total body surface (TBS) burns, with an average

of 37% TBS and two patients presented airway burns. Eight of these 11 hands were covered with Integra® in the acute phases of burns (Table 1). Three of the 14 patients had bilateral hand burns, of which only one case was covered bilaterally with Integra®; the other two cases were treated with Integra® on one hand and STSG on the other. Eight patients presented a unilateral burn covered with the dermal regenerator. Eight hands (8/17) were covered with Integra® in the acute phase, 13 ± 7 days from the accident (Table 2). In nine cases, Integra® was used to substitute an old unstable burn scar covered with STSG. The time of cutaneous replacement was 10 ± 7 months (3.7–25.7 months) after the accident in these cases (Table 3). There was one case of infection of the dermal regenerator, located at the metacarpophalangeal region of the middle and annular fingers, which led to its loss and need for an STSG. Functional analysis of the hands was performed at an average of 3.5 years from the moment of the autograft over the neodermis, with a range from 7 months to 6.5 years. The range of articular motion was complete in 15 of 17 cases (88%). Of the two remaining cases, one presented moderate motility limitation in both active and passive movements of the fifth digit, whereas the other case presented limited flexion of the fingers due to dorsal skin retraction. In 88% of the hands (15 of 17), flexible skin coverage was achieved, with adequate pliability between fingers and a good aesthetic result (Figs. 2 and 3). In the rest of the cases (two hands), the result was a thick and ridged skin coverage. Small cicatricial bands were observed in 4 of the 17 hands (24%), three of which had no functional impact. Only one patient required surgery due to the limitation in extending the fifth digit. In two cases, asymptomatic minor syndactyly was observed, with no functional impact on daily living activities. When comparing prehension strength of the burned hand treated with Integra® with the contralateral hand in patients with unilateral hand burns (eight patients), no statistically significant difference was observed: 62 ± 28 pounds in the burned

Table 1 Patient characteristics.

Hand N°	Patient N°	TBS	Hand segment burned	Laterality	Acute/Chronic	Age (years)	Time accident - Integra® (months)	Follow -up (years)
1	1	58%	Hand dorsum	Right	Acute	32.4	27	6.2
2	2	35%	Hand dorsum	Right	Acute	30.0	15	5.8
3	3	1%	Hand dorsum	Right	Acute	30.6	4	2.2
4	4	54%	Hand dorsum	Right	Acute	21.0	9	4.3
5	4			Left	Acute		9	
6	5	20%	Palm of hand	Right	Chronic	40.1	826	3.3
7	6	20%	Hand dorsum	Right	Chronic	26.5	228	3.1
8	7	6%	Hand dorsum	Left	Acute	19.8	12	6.5
9	8	1%	Hand dorsum	Left	Acute	24.3	7	1.1
10	9	20%	Hand dorsum	Right	Chronic	35.4	339	5.8
11	9			Left	Chronic		112	
12	10	15%	Hand dorsum	Right	Chronic	68.6	287	0.6
13	11	24%	Hand dorsum	Right	Chronic	18.8	181	0.9
14	12	10%	Hand dorsum	Right	Chronic	21.1	340	0.8
15	12			Left	Chronic		255	
16	13	43%	Hand dorsum	Left	Acute	39.0	18	5.3
17	14	60%	Fifth digit	Left	Chronic	32.1	133	3.7

Table 2 Moment of Integra® use.

Acute	8 (47%)
Chronic	9 (53%)

Table 3 Time between the accident and use of Integra®.

Acute	13 ± 7 days (4 – 27)
Chronic	10 ± 7 months (3.7 – 27.5)

hand (range 35–120) compared with 66 ± 27 pounds in the non burned hand (ranges 40–120), significance ($p < 0.1$), (Figure 4). Sixteen of the 17 cases had a painless evolution. Only one patient (6%) presented neuropathic pain with NRS scale 2/10, which was the only case of palmer burn compromise of the dominant hand, with a melted metal burn mechanism. Pain in this case did not significantly alter the patients' daily living activities. The overall 400 Point Evaluation score in the 17 burned hands covered with Integra® studied was $92.8 \pm 6.3\%$ (80–100). When evaluated separately, the prehension strength item was the most affected with 79 ± 18 points (ranges 42–100) (Figure 5). Eleven of the 14 patients (79%) returned to normal active working activities (Table 4).

Discussion

Hand coverage is a great challenge when faced, because of the highly specialised characteristics of the skin of the dorsum and palm.^{1,2} Sixty percent of the organism's functionality depends on this corporal segment; consequently, a suboptimal treatment can be devastating. Therefore, the

ideal hand coverage should mimic the special characteristics of the hand's skin, minimising the impact on hand function.⁷

In the specific case of burn accidents, the hand is the corporal segment most frequently involved (85%)⁸ and therefore must be the priority at the moment of early coverage using the most adequate alternative among the resources available. The aim is to prevent future treatment of retractile scars of the hand. This surgical approach must be associated to a multidisciplinary teamwork, to improve results.^{9–11} Results will depend on depth of burns, underlying structure involvement, adequate local care and election of the adequate reconstruction alternative.^{8,11} Multiple alternatives have been described for the coverage of the hand, ranging from the use of FTSG,^{7,12,13} considered today's gold standard, despite the fact that some problems may be encountered such as scar retraction,¹⁰ difficulty in graft integration, availability and morbidity of donor site, the latter being of special importance in the case of large TBS burns.¹³ In our series, nine patients (64%), had over 20% of TBS burns, for which availability of FTSG as an alternative for coverage was discharged, and the alternative of use of Integra® was part of the therapeutic arsenal that our Unit counted with, obtaining excellent functional and aesthetic results. Local, distant and free flaps have also been used for acute and chronic coverage of the hand,^{7,8,14,15} each with its specific tradeoffs with respect to the quality of the coverage, retractile scars, suboptimal aesthetic results and donor site morbidity, eliminating each as being the best alternative. Cutaneous expanders have also been proposed with poor results.¹⁶ The use of Integra® has become an alternative for wound and burn coverage in both acute and chronic stages of wound treatment.^{1,3,4,17,18} Lately, its use in special areas has become a valid option, as is described in this series of cases, where Integra® is used for the treatment of burned

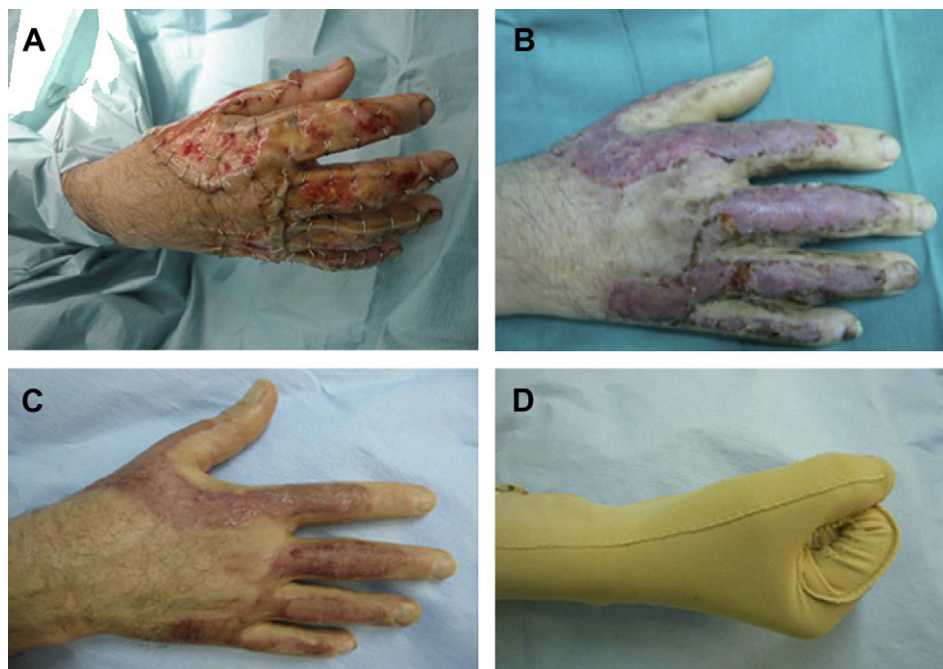


Figure 2 42 year-old man, 54% TBS third degree fire burns that involved the dorsum, long digits and thumb of the right hand. A) Integra® used in acute phase, B) Two weeks post STSG over neodermis, C) One month after STSG D) Elastic compression therapy.

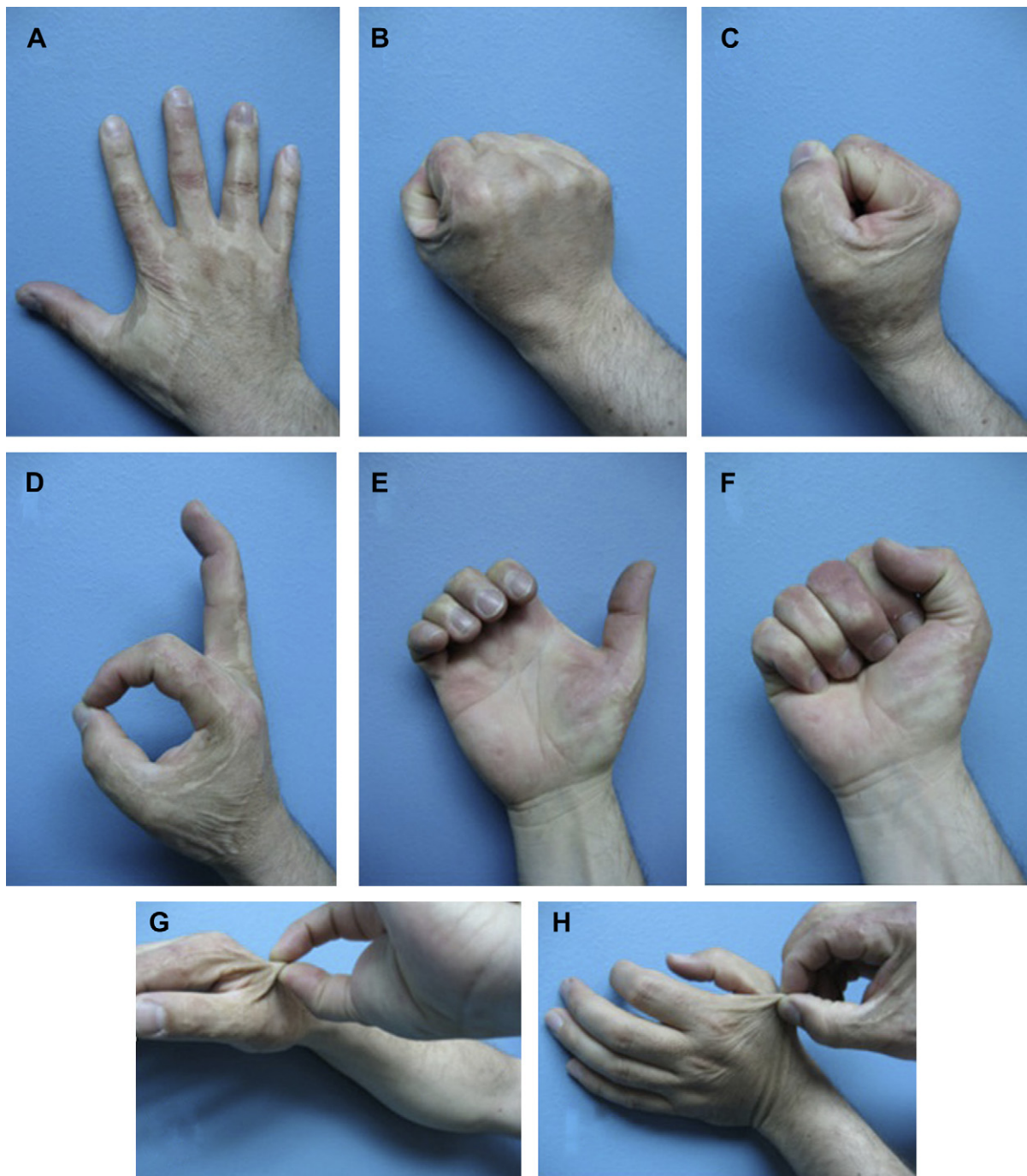

Figure 3 Six year follow up of functional evaluation of Integra® A) Finger abduction, B) and C) Fist, D) OK sign, E) Claw, F) Finger-palm apposition, G) Pliability of the skin of non injured hand, H) Pliability of the burnt hand with Integra®.

palm, dorsum and fingers of the hand in all its phases. Integra® has the property of contributing the matrix for neodermal regeneration, necessary for optimal wound healings.^{19,20} In the specific case of the hand, the need to avoid retractions makes this alternative ideal. The use of thin STSG for the coverage of the neodermis diminishes donor site morbidity, permitting a rapid re-epithelisation of those sites that could be necessary to retake as new donor sites in extended TBS burns.²¹

This series is composed of 17 burned hands in 14 patients. The majority of the patients were young people

constituting part of the active labour force and all were right handed, where an optimum and rapid cutaneous coverage and rehabilitation was necessary for the patient to return to work as soon as possible, evidenced by the average time of coverage in the patients treated in the acute phase of their hand burns (2 weeks). Eight hands were treated in the acute burn phase and nine as part of the scar treatment, with good results in both groups. Dantzer published a series of 29 burned hands treated with Integra®, with acute grafting performed on 15 hands and reconstructive surgery in the chronic phase on 14 hands,

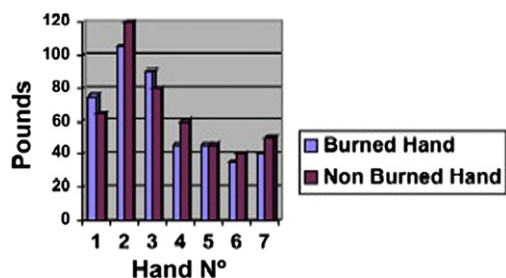


Figure 4 Manuel prehension strength. Comparison between burnt hands treated with Integra® and the contralateral non burnt hand in unilateral hand burns.

evidenced when manual prehension was tested, nevertheless, labour reintegration was obtained in 79% of the cases of patients treated with Integra®, which reflects the fact that this type of coverage not only delivers an excellent aesthetic quality of coverage but also preserved the functionality of the hand, favouring social and laboural reinstatement.

Literature reports concerning the use of Integra® for dermal regeneration in burned hands are scarce, with the largest series reported by Dantzer,¹ including 29 hands. We find it useful to present our experience with the use of this alternative in the treatment of burned hands, while we are conscious of the limitations of our results because

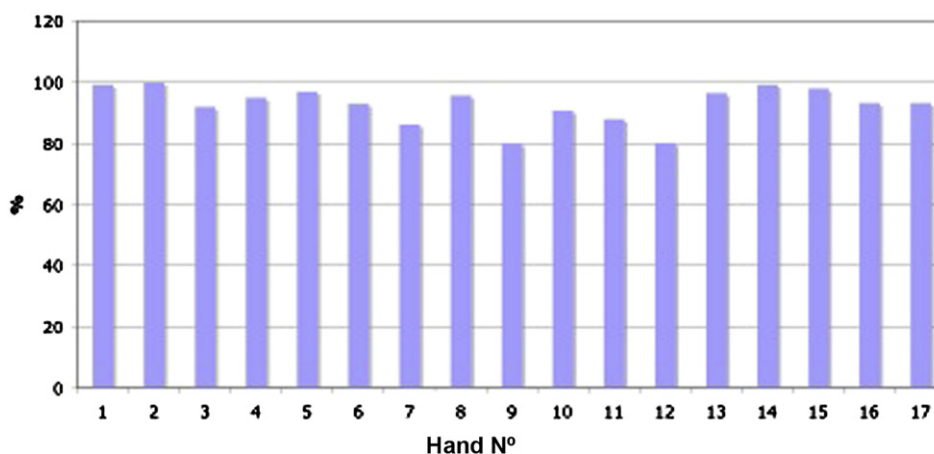


Figure 5 Results of 400 Points Evaluation test applied on patients treated with Integra®.

with favourable functional and aesthetic results.¹ Patients with associated hand injuries were excluded, as were electric burns, because of the high probability of concomitant hand lesions (nervous, vascular and tendon injuries) that may affect and influence functional outcomes. To determine the results of the use of this dermal regenerator in this group of patients, functional validated evaluation tests were applied for prehension, pliability of the skin and pain.^{20,21} In the majority of the patients (88%) hand function was adequate, with complete range of articular movement, good pliability of the skin and optimal aesthetic results. Only one patient presented minimal fifth digit retraction, and four patients evolved with small cicatricial bands with no functional impact. One patient presented syndactyly that required surgical correction but did not affect final functional results. Prehension strength was only minimally altered in five hands in five patients, and only the one case of palmar hand burn evolved with chronic neuropathic pain, which had no functional impact either. The 400 Point Evaluation showed that the major alteration was

of the fact that we performed a retrospective review of the treated patients. We provide new evidence with respect to the use that can be given to Integra® as an excellent and promising alternative for the coverage of local burns, in both acute and chronic phase treatment, with optimal aesthetic and functional results similar to normal skin.

Conflict of interest statement

Ricardo Roa M.D. is a speaker for Integra® Life Science Corporation. He receives a fee for his conferences on Integra®, and was not involved in functional results' evaluation.

The author and co-authors disclose any financial support, benefits or any commercial source related directly or indirectly to the scientific work reported. No grants or funds were received.

Acknowledgements

The authors thank the multidisciplinary group, especially María Isabel Meneses, from the Occupational Therapy Unit, Rigoberto Moya and Ivan Zamorano, from the Physical Therapy Unit, engaged in the patients' rehabilitation process and in the evaluation procedure.

Table 4 Laboral reinsertion.

Laboral status	No. of patients
Working	11(79%)
Not working	3(21%)

References

1. Dantzer E, Queruel P, Salinier L, Palmier B, Quinot JF. Dermal regeneration template for deep hand burns: clinical utility for both early grafting and reconstructive surgery. *J Plast Reconstr Aesthet Surg* 2003;**56**:764–74.
2. Kowalske KJ, Greenhalgh DG, Ward SR. Hand burns. *J Burn Care Res* 2007;**28**(4):607–10.
3. Cedidi C, Hierner R, Wilkens L, Berger A. The deeply burned upper extremity: functional graft distribution concept with selective use of a synthetic dermal substitute (Integra) and split-thickness skin grafts. *Eur J Plast Surg* 2002;**25**:226–30.
4. Frame JD, Lakhel-LeCoadou A, Carstens MH, Lorenz C, Orlet H, Spence R, et al. Use of dermal regeneration template in contracture release procedures: a multicenter evaluation. *Plast Reconstr Surg* 2004;**113**(5):1330–8.
5. Gable C, Chau N, Xenard J, Andre JM. Inter-rater agreement of a functional analytical measure of the upper limb. *Rev Epidemiol Sante Publique* 1993;**41**(1):72–83.
6. Luquet C, Chau N, Nadif M, Guillemin F, Gavillot C, Petry D, et al. Unidimensionality of a functional measure for patient with an injured upper limb. *Rev Epidemiol Sante Publique* 1996 Jun;**44**(3):248–61.
7. Hunt JL, Purdue GF, Zbar RIS. Burns: acute burns, burn surgery and postburn reconstruction. *Selected Readings in Plastic Surgery* 2000;**9**(12).
8. Falcone PA, Edstrom LE. Decision making in the acute thermal hand burn: an algorithm for treatment. *Hand Clin* 1990;**6**(2): 233–8.
9. Hunt JL, Sato R, Baxter CR. Early tangential excision and immediate mesh autografting of deep dermal hand burns. *Ann Surg* 1979;**189**:147–51.
10. Quan PE, Bieringer R, Alston DW, Curreri PW. Control of scar tissue in the finger web spaces by use of graded pressure inserts. *J Burn Care Rehabil* 1981;**2**:27–9.
11. McCauley RL. Reconstruction of the pediatric burned hand. *Hand Clin* 2000;**16**:249–59.
12. Iwuagwu FC, Wilson D, Bailie F. The use of skin grafts in post-burn contracture release: a 10-year review. *Plast Reconstr Surg* 1999;**103**:1198–204.
13. Smith MA, Munster AM, Spence RJ. Burns of the hand and upper limb—a review. *Burns* 1998;**24**:493–505.
14. Chick LR, Lister GD, Sower L. Early free flap coverage of electrical and thermal burns. *Plast Reconstr Surg* 1992;**89**:1013–9.
15. Alexander JW, MacMillan BG, Martel L. Correction of postburn syndactyly: an analysis of children with introduction of the VM-plasty and postoperative pressure inserts. *Plast Reconstr Surg* 1982;**70**:345–54.
16. Salisbury RE. Reconstruction of the burned hand. *Clin Plast Surg* 2000;**27**:65–9.
17. Fette Andreas. Integra artificial skin in use for full-thickness burn surgery: benefits or harms on patient outcome. *Technology and Health Care* 2005;**13**:463–8.
18. Khan MR, El Faki HMA, Gorila A, Rezaq A, Aziz EA, Rentasi K. Experience with integra in the management hypertrophic scars and contractures. *Eur J Plast Surg* 2007;**30**:101–6.
19. MacNeil S. What role does the extracellular matrix serve in skin grafting and wound healing? *Burns* 1994;**20**(1):S67–71.
20. Burke JF, Yannas IV, Quinby Jr WC, Bondoc CC, Jung WK. Successful use of a physiologically acceptable artificial skin in the treatment of extensive burn injury. *Ann Surg* 1981;**194**(4): 413–28.
21. Heimbach D, Luterman A, Burke J, Cram A, Herdon D, Hunt J, et al. Artificial dermis for major burns: a multi-center randomized clinical trial. *Ann Surg* 1988;**208**:313–20.