

See discussions, stats, and author profiles for this publication at: <https://www.researchgate.net/publication/324597157>

Structural Anatomical Investigation of Long-Term Memory Deficit in Behavioral Frontotemporal Dementia

Article in *Journal of Alzheimer's disease: JAD* · March 2018

CITATIONS

0

READS

108

9 authors, including:



Maxime Bertoux

Centre Hospitalier Régional Universitaire de Lille

86 PUBLICATIONS **850** CITATIONS

[SEE PROFILE](#)



Amparo Ruiz-Tagle

University of Lisbon

11 PUBLICATIONS **11** CITATIONS

[SEE PROFILE](#)



Carolina Delgado

University of Chile

36 PUBLICATIONS **101** CITATIONS

[SEE PROFILE](#)



Marcelo Miranda

Clínica Las Condes

204 PUBLICATIONS **674** CITATIONS

[SEE PROFILE](#)

Some of the authors of this publication are also working on these related projects:



Improving language function via motor training [View project](#)



Neurogenetics [View project](#)

Structural Anatomical Investigation of Long-Term Memory Deficit in Behavioral Frontotemporal Dementia

Maxime Bertoux^{a,*}, Emma C. Flanagan^a, Matthew Hobbs^a, Amparo Ruiz-Tagle^c, Carolina Delgado^d, Marcelo Miranda^e, Agustín Ibáñez^{f,g,h,i,j}, Andrea Slachevsky^{k,l,1} and Michael Hornberger^{a,1}

^aNorwich Medical School, University of East Anglia, Norwich, UK

^bCentre de Référence Démence Rares, Pitié-Salpêtrière, INSERM UMRS 975, Paris, France

^cLaboratorio de Neurociencias, Centro de Investigación Avanzada en Educación, Universidad de Chile, Santiago, Chile

^dDepartment of Neurology, Clinic Hospital, University of Chile, Santiago, Chile

^eDepartment of Neurology, Clínica Las Condes, Santiago, Chile

^fCenter for Social and Cognitive Neuroscience (CSCN), School of Psychology, Universidad Adolfo Ibáñez, Santiago, Chile

^gInstitute of Cognitive and Translational Neuroscience (INCyT), INECO Foundation, Favaloro University, Buenos Aires, Argentina

^hNational Scientific and Technical Research Council (CONICET), Buenos Aires, Argentina

ⁱUniversidad Autónoma del Caribe, Barranquilla, Colombia

^jCentre of Excellence in Cognition and its Disorders, Australian Research Council (ACR), Sydney University, NSW, Australia

^kPhysiopathology Department, Neuroscience Department, Faculty of Medicine, University of Chile, Santiago, Chile

^lGerosciences Center for Brain Health and Metabolism, Santiago, Chile

Accepted 15 January 2018

Abstract. Although a growing body of work has shown that behavioral variant frontotemporal dementia (bvFTD) could present with severe amnesia in approximately half of cases, memory assessment is currently the clinical standard to distinguish bvFTD from Alzheimer's disease (AD). Thus, the concept of "relatively preserved episodic memory" in bvFTD remains the basis of its clinical distinction from AD and a criterion for bvFTD's diagnosis. This view is supported by the idea that bvFTD is not characterized by genuine amnesia and hippocampal degeneration, by contrast to AD. In this multicenter study, we aimed to investigate the neural correlates of memory performance in bvFTD as assessed by the Free and Cued Selective Reminding Test (FCSRT). Imaging explorations followed a two-step procedure, first relying on a visual rating of atrophy of 35 bvFTD and 34 AD patients' MRI, contrasted with 29 controls; and then using voxel-based morphometry (VBM) in a subset of bvFTD patients. Results showed that 43% of bvFTD patients presented with a genuine amnesia. Data-driven analysis on visual rating data showed that, in bvFTD, memory recall & storage performances were significantly predicted by atrophy in rostral prefrontal and hippocampal/perihippocampal regions, similar to mild AD. VBM results in bvFTD ($p_{FWE} < 0.05$) showed similar prefrontal and hippocampal regions in addition to striatal and lateral temporal involvement. Our findings

¹These authors contributed equally to this work.

*Correspondence to: Dr. Maxime Bertoux, Centre Mémoire de Ressources et de Recherche, Hôpital Roger Salengro, CHRU de Lille, Lille, France. E-mail: maxime.bertoux@cantab.net.

showed the involvement of prefrontal as well as medial/lateral temporal atrophy in memory deficits of bvFTD patients. This contradicts the common view that only frontal deficits explain memory impairment in this disease and plead for an updated view on memory dysfunctions in bvFTD.

Keywords: Alzheimer's disease, amnesia, behavioral frontotemporal dementia, hippocampus

INTRODUCTION

Behavioral variant frontotemporal dementia (bvFTD) is the second most prevalent type of early onset dementia after Alzheimer's disease (AD) [1]. Despite a characteristic behavioral symptomatology, bvFTD could frequently be misdiagnosed as AD and, in clinical contexts where amyloid biomarkers cannot be sought, clinicians often rely on memory assessment for the differential diagnosis between both diseases.

Episodic memory impairment is indeed the hallmark of typical AD and is not contemplated as a possible clinical presentation of bvFTD in the current diagnostic criteria [2, 3]. However, memory impairments in FTD have been demonstrated through many past works. Originally, three of the five patients initially described by Arnold Pick suffered from episodic memory disturbances. Additionally, genuine amnesia in FTD was consistently observed in the early cases described in the last-century's scientific literature as well as in the more systematic observations that followed (for a review, see [4]). These findings seem to have been relatively ignored until a recent group study reported severe memory impairment in bvFTD [5]. Using the Free and Cued Selective Reminding Test (FCSRT) to investigate the different memory processes and supporting the patients' clinical diagnoses with biological evidence, a following study showed that half of bvFTD patients could present with a genuine amnesia characterized by encoding, storage and consolidation deficits while the remaining patients presented a decrease of spontaneous recall that normalized with cueing [6]. This identification of two distinct cognitive profiles, namely amnesic-bvFTD and non-amnesic-bvFTD [6], has recently been confirmed in an independent study [7]. In fact, during the past years, a growing number of studies have provided various findings of true memory dysfunctions in bvFTD, with patients having been shown to exhibit a wide range of memory difficulties such as in face recognition, object memory [8], prospective memory [9], episodic future-thinking [10], autobiographical memory [11], orientation [12], and word-list recall.

In particular, word-list based memory assessment, the most common form of memory evaluation in the field of neurodegeneration, has constantly shown evidence of variable memory impairment in bvFTD over the last years. Importantly, this poor discrimination power has been shown independently of the test used, such as with the Rey Auditory Verbal Learning Test (RAVLT) [5, 13–16], the California Verbal Learning Test (CVLT) [17, 18], the FCSRT [6, 7, 19], or others [20].

Taken together, these findings show that an important overlap between bvFTD and AD is consistently observed in neuropsychological studies of memory. The recently described bimodal profile of bvFTD patients (i.e., amnesic and non-amnesic presentation) explains why mean memory scores can be statistically different between AD and bvFTD at a group level (e.g., [19, 21]), but not at an individual level, therefore lacking clinical utility in the differential diagnosis of both diseases.

Beyond the psychometric ability of the FCSRT to distinguish bvFTD from AD or not is the topic of its neural correlates in bvFTD. Past structural imaging studies have indeed only been conducted in AD [22] or focused on other memory tests [23–26]. Despite evidence for bilateral hippocampal atrophy in bvFTD [24, 27, 28], a common view is still that executive dysfunctions or prefrontal atrophy explains memory deficit in bvFTD [29]. Although recently contradicted by data-driven evidences [30], this hypothesis has justified the use of the FCSRT to delineate executive from genuine memory deficits in bvFTD and AD, respectively. However, anatomical and neuropsychological data [6, 24, 27, 28, 30] suggest a hippocampal involvement in bvFTD memory dysfunctions as well as the presence of a genuine memory impairment.

This study aims to identify the structural anatomical markers of episodic memory impairment in bvFTD as assessed by the FCSRT. Imaging explorations were conducted using a two-step procedure. First, a visual rating of the atrophy of 98 scans from two centers was conducted in bvFTD, AD, and controls, a procedure close to the neurological clinical practice. We included a group of AD patients because

this disease is the most frequent differential diagnosis of bvFTD and because amnesia is a clinical characteristic of typical AD. The relationship between atrophy and memory performance was then investigated with data-driven methods. Secondly, we used a voxel-based morphometric statistical approach in a subgroup of bvFTD patients and controls from the same center.

METHODS

Participants

A total of 98 participants were included in this study, including 35 probable bvFTD patients, 34 patients with AD, and 29 healthy, aged controls. We included bvFTD patients with memory impairment if other core diagnostic criteria were present [3]. Patients with bvFTD were selected from the database of the Pitié-Salpêtrière Hospital in Paris, France ($n=23$) and through the Cognitive Neurology and Dementia Unit of the Hospital del Salvador, University of Chile ($n=12$). Of these 35 patients who received a clinical diagnosis of bvFTD on the basis of clinical, cognitive and imaging examinations (showing evidence of frontal and/or temporal atrophy at the MRI and/or hypometabolism at the single-photon emission computerized tomography), 31% ($n=11$) had additional biological evidences supporting the clinical diagnosis through non-AD cerebrospinal fluid measures of phospho-tau, total-tau, and amyloid- β levels. A group of 35 patients with AD were included from the Cognitive Neurology and Dementia Unit (Chile) according to McKhann et al. [31] criteria. All underwent a cognitive examination and a T1 MRI. One patient was excluded because of significant movement that blurred the MRI examination resulting in a group of 34 patients. From an initial sample of 35 controls, we retained 29 of them. All were volunteers at the Cognitive Neurology and Dementia Unit (Chile). They underwent a neuropsychological examination and a MRI. On the basis of these examinations, we excluded 6 controls with abnormal cognitive examination or significant vascular signs. All patients were followed for at least 12 months and performed another cognitive assessment at 6, 12, or 18 months. The clinical progression of the patients included did support the initial clinical diagnosis made. All participants underwent a neuropsychological examination, assessing memory, executive functions, verbal abilities, and attention (see Supplementary Table 1). AD patients underwent

the Clinical Dementia Rating scale [32]; 14 patients had questionable dementia ($CDR=0.5$), 15 were at a moderate stage of the disease ($=1$), and 5 at a severe stage ($CDR=2$). CDR data were not available for bvFTD patients.

Exclusion criteria included clinically significant vascular lesions (Fazekas scale with a score >2). FLAIR sequences were available for all controls, ADs, and most of bvFTD. For those patients without a FLAIR sequence, we also considered that any history of stroke or any sign of infarcts on T1 images were exclusion criteria. In any case, the fulfilment of the NINDS-AIREN criteria for vascular disease or the NINDS-AIREN imaging criteria was an exclusion criterion. Other exclusion criteria were missing cognitive data, concomitant motor-neuron disease, alcoholism, absence of T1-MRI or blurred MRI because of significant movements; atypical clinical, and imaging evolution compatible with the diagnostic of non-progressive bvFTD; atypical evolution not in accordance with initial diagnosis (i.e., predominance of language impairments, abrupt cognitive deterioration, cognitive improvement or fluctuation).

The Ethics and Scientific Committees of the East Metropolitan Health Service, Chile University (Chile) approved the recruitment and testing of participants whom all provided written informed consent. Biological and clinical data of French patients were collected during the routine clinical workup and were retrospectively extracted for the purpose of this study. Thus, according to French legislation, explicit informed consent was waived. However, the regulation concerning electronic filing was followed, and both patients and their relatives were previously informed that individual data could be used in retrospective clinical research.

Assessment of memory

All participants underwent the Free and Cued Selective Reminding Test (FCSRT), a memory test based on a semantic cueing method that controls for effective encoding of 16 unrelated words and facilitates retrieval by this semantic cueing. Immediate cued recall was tested in a first phase, to control for encoding (Encoding score). Then, the memory phase was performed in three successive trials, each trial including a free recall attempt (consisting of spontaneous recall of as many items as possible during 2 min) then a cued recall attempt, using an aurally presented semantic category for items that were not spontaneously retrieved by the patients. The same

semantic cues given during the initial encoding stage were used. These phases provided a free recall score and a cued recall score (the sum of both being the total recall score). We computed a percentage of sensitivity to cues. Following a delay of 30 min, a final recall trial was performed, providing free and cued delayed recall scores. The FCSRT age, sex, and educational level adjusted normative data were considered to classify participants as being amnestics or non-amnestics. In more detail, total recall scores equal to or below the 10th percentile were considered as abnormal and reflecting a genuine amnesia.

Imaging acquisition and analyses

All participants underwent a whole-brain T1-weighted examination. In Paris, this examination was performed with a 1.5 Tesla GE-Medical Systems Signa Excite ($n = 12$ bvFTD) or with a 3 Tesla GE-Medical Systems Signa HDx ($n = 11$ bvFTD) MRI scanners. In Santiago, the examination was performed with a 1.5 Tesla Siemens scanner ($n = 34$ AD) or with a 1.5 Tesla Phillips Intera scanner ($n = 12$ bvFTD and 29 controls). Importantly, as Chilean controls and bvFTD participants underwent the examination from the same machine with identical parameters, VBM analyses were restricted to these participants. Twenty controls were then selected to match the bvFTD participants on age. The 1.5 Tesla Phillips Intera scanner is equipped with a standard head coil. A T1-weighted spin echo sequence acquired parallel to the plane connecting the anterior and posterior commissures and covering the whole brain was used to generate 120 contiguous axial slices (repetition time = 2300 ms; echo time = 13 ms; flip angle = 68° ; field of view = rectangular 256 mm; matrix size = 256×240 ; slice thickness = 1 mm; isotropic voxel size $1 \times 1 \times 1$ mm).

Visual atrophy ratings

Two raters (EF, MH), blind to the clinical diagnoses, rated T1 coronal MRIs. Previously, all textual information displayed on the MR scans was removed and the coronal slices were exported into standardized and anonymous video files. The ratings of the scans involved reviewing 6 standardized coronal MRI slices: the first one slice before seeing the corpus-callosum; the second at the level of the fronto-temporal junction; the third posterior to the optical chiasma when the optical nerve are distinct and not joined; the fourth at the level of the junction between

the Pons and the rest of the brain; the fifth at the level where the brainstem is detached from the rest of the brain; the sixth one slice after the posterior corpus callosum. A total of 11 regions were scored bilaterally; on the first slice the dorso-lateral, medial and ventro-median prefrontal cortices; on the second slice the anterior cingulate and polar temporal cortices; on the third the amygdala as well as the perirhinal and entorhinal cortices; on the fourth, the anterior hippocampus; on the fifth, the posterior hippocampus; on the sixth, the precuneus. Atrophy within each region was rated on a 5-point Likert scale ranging from 0 to 4 (0 = normal; 1 = borderline appearances, possibly normal; 2 = definite atrophy present; 3 = marked atrophy; 4 = severe atrophy). The raters were first trained (two sessions) on an independent set of 29 MR scans that included different dementia populations with varying degrees of severity, as well as healthy controls. Inter-rater reliability between the two raters was assessed through inter-class correlation. Coefficients were significant and good (average Cronbach's alpha = 0.744).

Statistics

Using SPSS 20 (SPSS, Chicago, IL, USA), one-way ANOVA were conducted to compare demographic, neuropsychological, and imaging data across groups (with age as a covariate for the two last dimensions), followed by Bonferroni *post hoc* tests. Binary logistic regressions with Enter method were computed for atrophy ratings. As a second step, all brain regional ratings were entered into an Automated Linear Model (ALM) as predictors of FCSRT Free recall and total recall scores separately. Basically, in a heterogeneous group of potential predictor variables, ALM will find the best way to predict targeted values on a single scaled outcome variable. ALM overcomes the limitations of traditional regression techniques [33] and involves automatic data preparation and variable selection.

Voxel based morphometry analyses

These analyses were performed on 3D T1-weighted sequences that were acquired with the same machine in Santiago, Chile. Images were analyzed with FSL-voxel based morphometry (VBM), a VBM analysis [34, 35] which is part of the FSL software package (<http://www.fmrib.ox.ac.uk/fsl/fslvbm/index.html>) [36]. First, tissue segmentation was carried out using FMRIB's automatic

segmentation tool (FAST) [37] from brain-extracted images. The resulting grey-matter partial volume maps were then aligned to the Montreal Neurological Institute standard space (MNI152) using the non-linear registration approach using FNIRT [38, 39], which uses a b-spline representation of the registration warp field [40]. Default settings were used for these steps, but quality control for each scan was performed and slight alteration of the search space for the segmentation algorithm was performed for some patients with severe atrophy. A study specific template was created in which bvFTD and control participants were equally represented, following which the native grey matter images were re-registered non-linearly to this template. The registered partial volume maps were then modulated (to correct for local expansion or contraction) by dividing them by the Jacobian of the warp field. Importantly, the Jacobian modulation step did not include the affine part of the registration, which means that the data are normalized for head size as a scaling effect [41]. The modulated images were then smoothed with an isotropic Gaussian kernel with a SD of 3 mm.

VBM analyses were conducted on 20 controls and 12 bvFTD patients who did not differ on age (68.85 and 68.27 years, respectively, $p > 0.84$) and education level (13.55 and 13.67 years respectively, $p > 0.95$). VBM analyses were run on a subsample of participants that had the same imaging protocol, as a validation of the visual ratings of regional atrophy. AD patients were not included in these analyses because the acquisition of the MRI for those patients was performed with a different machine.

A voxel-wise general linear model (GLM) was applied and permutation-based non-parametric

testing was used to form clusters with the Threshold-Free Cluster Enhancement (TFCE) method [42], tested for significance at $p < 0.05$, corrected for multiple comparisons via Family-wise Error (FWE) correction across space. Age was added as a nuisance variable in the GLM.

First, a two-sample t -test was run to contrast patients and controls in order to identify specific regions atrophied in patients. Then, we performed a correlation analysis between grey matter intensity and FCSRT scores in bvFTD only (using a specific template with bvFTD patients only). Each FCSRT score was entered as a covariate of interest in the GLM. For statistical power, a covariate only statistical model with a positive t -contrast was used, providing an index of association between grey matter intensity and performance on the FCSRT. Anatomical locations of significant results were overlaid on the MNI standard brain. Anatomical labelling was determined with reference to the Harvard-Oxford probabilistic cortical atlas.

RESULTS

Demographics and clinical data (Table 1)

Control participants did not differ from AD and bvFTD on age (all p 's > 0.05), but AD patients were significantly older than bvFTD patients ($p = 0.001$). The three groups did not differ on education level. MMSE performance followed an expected profile with controls scoring significantly higher than bvFTD patients ($p < 0.001$), who in turn scored significantly higher than AD patients ($p = 0.001$). In addition, the neuropsychological assessment revealed an

Table 1
Demographics, clinical, and memory performances for controls, AD, and bvFTD patients and percentage of amnesic participants according to the FCSRT normative data

| | Controls ($n = 29$) | AD ($n = 34$) | bvFTD ($n = 35$) |
|------------------------------------|-----------------------|-----------------------------|-----------------------------|
| Demographics & clinical data | | | |
| Age (y) | 71.72 (5.8) | 74.11 (6.7) [§] | 67.17 (9.3) [§] |
| Education (y) | 12.86 (4.0) | 10.79 (4.8) | 12.14 (5.2) |
| MMSE | 28.28 (1.5)*,¶ | 21 (4.7) ^{¶,§} | 24.23 (3.9) ^{*,§} |
| Episodic memory assessment (FCSRT) | | | |
| Encoding (/16) | 15.14 (0.9)*,¶ | 9.29 (4.4) [¶] | 14.35 (2.3)* |
| Free recall (/48) | 28.35 (6.6)*,¶ | 8.06 (6.77) ^{¶,§} | 16.83 (8.06) ^{*,§} |
| Total recall (/48) | 44.86 (3.4)*,¶ | 22.26 (13.2) ^{¶,§} | 37.74 (11.4) ^{*,§} |
| Sensitivity to cues (%) | 85.45 (14.1)*,¶ | 39.08 (26.0) ^{¶,§} | 71.06 (26.5) ^{*,§} |
| Delayed total recall (/16) | 15.34 (0.9)*,¶ | 6.18 (5.0) ^{¶,§} | 12.77 (4.1) ^{*,§} |
| Amnesic participants (%) | 0% | 85% | 43% |

Mean (Standard deviation). MMSE, Mini-Mental State Examination; FCSRT, Free and Cued Selective Reminding Test. *Significant difference ($p < 0.05$ corrected) between bvFTD and controls; [§]Significant difference ($p < 0.05$ corrected) between AD and bvFTD; [¶]Significant difference ($p < 0.05$ corrected) between AD and controls.

impairment of abstract reasoning, cognitive inhibition, attention, and verbal fluency abilities in both AD and bvFTD (see Supplementary Table 1 for more details).

Episodic memory impairment (Table 1)

FCSRT scores showed that controls performed significantly better than bvFTD (all p 's < 0.05) except for the encoding score ($p = 0.626$). However, bvFTD performed significantly better than AD (all p 's < 0.001) on all scores (free recall, total recall, sensitivity to cues, and delayed recall), except encoding score.

When taking the FCSRT normative data to identify amnesic patients, 85% of AD and 43% of bvFTD were considered to be amnesic. There was no difference in the proportion of amnesic patients in the Chilean and French subgroups (41.7% and 43.5%, respectively). Interestingly, when considering the FCSRT thresholds originally proposed to identify the "amnesic syndrome of the medial temporal type" [43], we obtained a strict identical classification of patients. Mean percentile rank and ranges are available in Supplementary Table 2.

Regional atrophy, visual ratings (Fig. 1)

Raters' average scores of atrophy for each region were compared across the groups. When considering the three groups, the ANOVA showed significant

differences in all brain regions rated (all p 's < 0.05). *Post-hoc* two-by-two Bonferroni comparisons were then performed. Compared to controls, AD showed more atrophy in all regions (all p 's < 0.05) with the exception of the left dorsolateral prefrontal cortex. Compared to controls, bvFTD showed more atrophy in all regions (all p 's < 0.05) except in the bilateral dorsal prefrontal cortex and in the left precuneus, where only statistical trends were observed.

AD had more atrophy than bvFTD in the left anterior ($p < 0.005$; Cohen's $d = 0.096$) hippocampus and in the left and right posterior hippocampus ($p = 0.008$; $d = 0.126$ and $p = 0.01$; $d = 0.039$, respectively). These effect-sizes were small. However, bvFTD had more atrophy than AD in the right ventro-medial ($p = 0.01$; $d = 0.626$) and right medial prefrontal cortices ($p = 0.0001$; $d = 0.949$). By contrast, these effect-sizes were medium and large.

Logistic regressions were conducted on the raters' average scores of atrophy in the regions identified during the direct comparison between bvFTD and AD. The left anterior hippocampus reached an accuracy of 66.7% to predict the correct diagnosis of patients (i.e., AD identified as AD and bvFTD identified as bvFTD). The right anterior and posterior hippocampus reached an accuracy of 62.3% and 63.8%, respectively. In the frontal regions, the right OFC and the right mPFC reached an accuracy of 66.7% and 69.6% to predict the correct diagnoses.

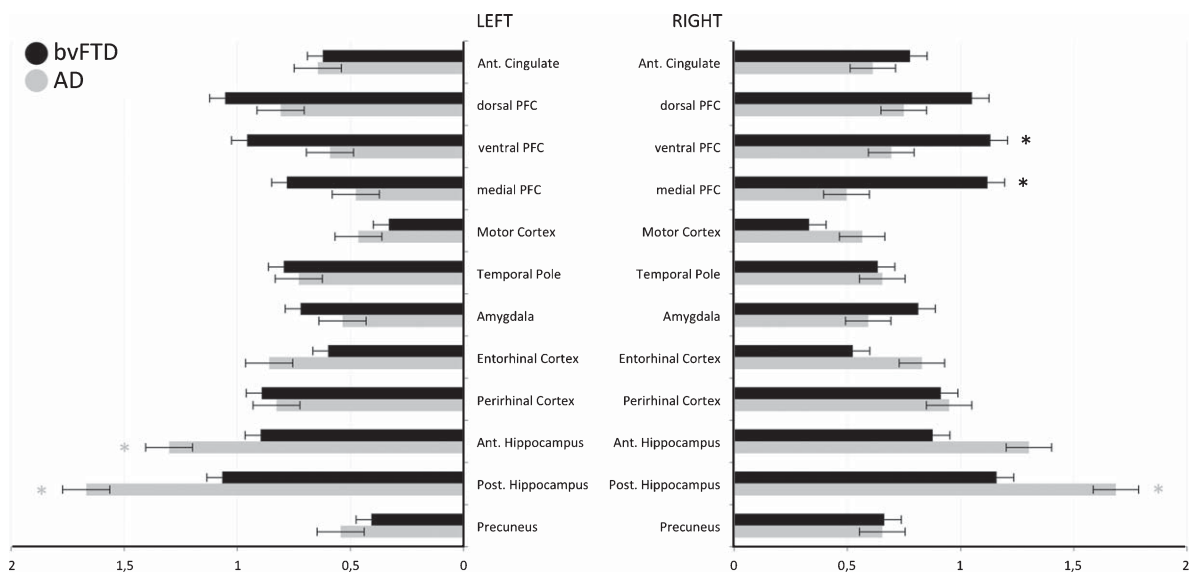


Fig. 1. Graphic representation of the differences (and error bars) between AD (grey) and bvFTD (black) patients and controls atrophy (taken as a baseline) in all left and right regions of interest. Asterisk represent either AD > bvFTD (grey) or bvFTD > AD (black) significant difference (corrected for multiple comparison). Ant, anterior; Post, posterior; PFC, prefrontal cortex.

Automated linear model

In this step, all brain regional ratings were entered into an ALM aiming to identify the significant predictors of FCSRT free recall and total recall scores separately. One separate ALM was run for each patients group.

FCSRT free recall

In AD, the model reached an adjusted R^2 of 49.5% with an information criterion of 130.799 and identified the bilateral medial prefrontal cortex as a significant predictor of the FCSRT Free Recall score, although this result failed to survive after correction for multiple comparisons. In bvFTD, the model failed to identify any significant predictor.

FCSRT total recall

In AD, the model reached an adjusted R^2 of 27% with an information criterion of 169.822 and identified the bilateral mPFC and the left dorsolateral as significant predictors of the FCSRT total recall score, but these regions failed to remain significant after correcting the model for multiple comparisons. In addition, a visual inspection of the linear regression plot between predicted and actual values showed two separate subgroups corresponding to patients with severe amnesia (FCSRT total recall <20) and patients with moderate amnesia (FCSRT total score >20). A linear curve was only evident in the last subgroup. We then decided to distinguish AD patients as being in the mild or moderate/severe stage of the disease using the CDR as an independent criterion and ran the ALM again on the AD subgroups identified by the CDR score separately. In the mild AD group

($N = 14$), the model reached an adjusted R^2 of 96.9% with an information criterion of 46.802 and identified the left amygdala, the right OFC, the left mPFC, the left perirhinal and entorhinal cortices, and the right posterior hippocampus as significant predictors. All these regions remained significant after correction. In the moderate/severe AD group ($N = 20$), the model failed to identify any significant predictor.

In bvFTD, the model reached an adjusted R^2 of 59.9% with an information criteria of 150.915 and identified the bilateral perirhinal cortex, the bilateral OFC, the left anterior hippocampus, the right posterior hippocampus, and the left mPFC as significant predictors of the FCSRT total recall score. After correction, the left perirhinal and right ventromedian cortices as well as left anterior hippocampus remained significant.

Voxel based morphometry (Figs. 2 and 3)

All VBM results were obtained at a threshold of $p < 0.05$ after FWE correction. We only report clusters with a conservative cluster extent threshold of 100 contiguous voxels. Peak coordinates, cluster sizes, and t -values for each result are reported in Supplementary Table 3. Comparison between bvFTD and controls showed an important cluster (66148 voxels) encompassing large parts of the dorsal and ventral medial frontal cortex, regions of the dorsolateral frontal cortex, anterior and posterior insula, most of the regions of the striatum, the thalamus, polar regions of the temporal lobe, middle temporal gyrus, amygdala and hippocampus bilaterally, as well as regions within the parietal and occipital lobe, mostly lateralized on the right side and a bilateral involvement of the cerebellum. Another large cluster (1693 voxels) was also found in the right cerebellum.

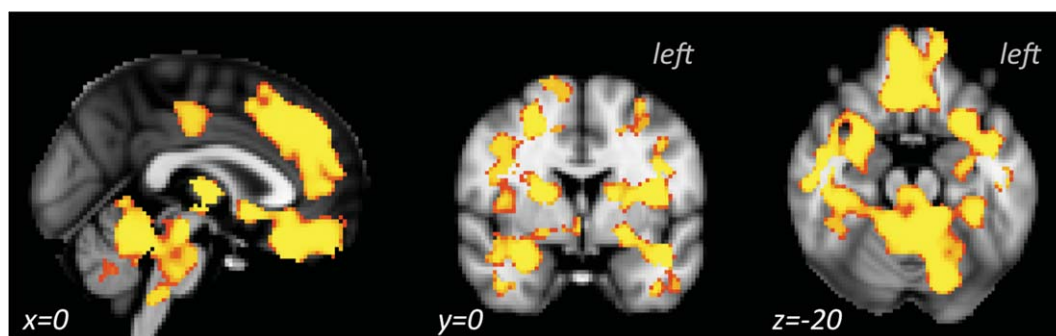


Fig. 2. Atrophy observed in the bvFTD group, resulting from the VBM contrast between controls and bvFTD patients at $p_{FWE} < 0.05$ (controlled for age).

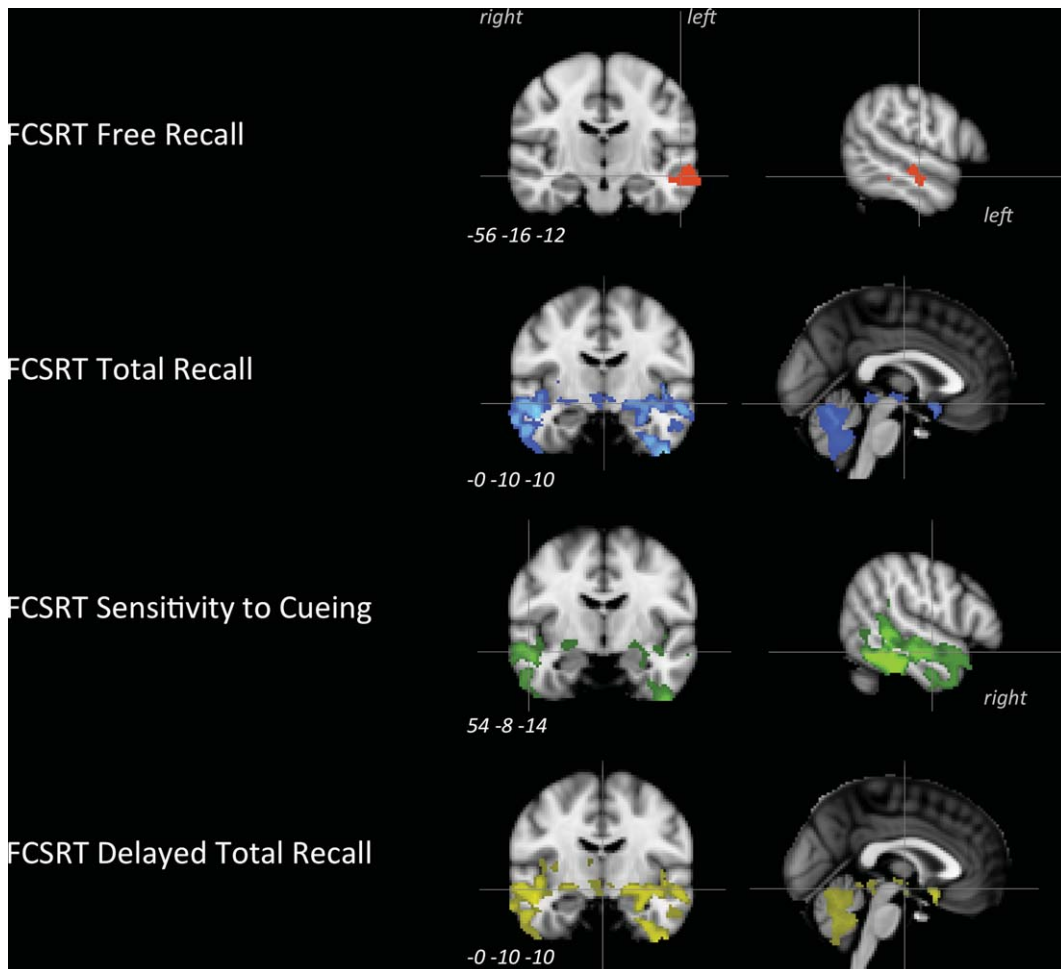


Fig. 3. Results of the correlation between grey-matter intensity in bvFTD and FCSRT Free (red), total (blue), and delayed total (yellow) recall scores as well as sensitivity to cueing (green) at $p_{FWE} < 0.05$ (with age as a nuisance variable). MNI coordinates (x, y, z) are specified for each pair of views (coronal and sagittal).

Correlation with FCSRT free recall in bvFTD

Results showed two clusters (266 and 138 voxels, respectively) in the left middle temporal gyrus.

Correlation with FCSRT total recall in bvFTD

A large cluster (19498 voxels) correlated with the FCSRT total recall score and encompassed the ventral mPFC in its subgenual portion, the anterior putamen and nucleus accumbens within the striatum, the insula, large parts of the polar and lateral regions of the temporal lobes bilaterally, bilateral median cerebellum (regions V, IX, vermis VIII), bilateral lateral cerebellum (regions VI and Crus I) as well as the left amygdala, anterior hippocampus, perihippocampus, and ventral temporal regions.

Correlation with FCSRT sensitivity to cueing in bvFTD

Sensitivity to cueing correlated with a first cluster (6874 voxels) within the right temporal lobe including the right polar temporal regions extending to the anterior portion of the superior temporal gyrus and to large parts of the middle temporal gyrus. This cluster also included posterior portions of the inferior temporal gyrus (including its most ventral parts) as well as right putamen and amygdala. A second cluster (3466 voxels) was found in the left temporal lobe encompassing the temporal pole in its superior regions, anterior and posterior regions of the inferior temporal gyrus, posterior regions of the middle temporal gyrus, and the left amygdala and hippocampus.

Correlation with FCSRT delayed total recall in bvFTD

Delayed total recall score correlated with a large cluster (22788 voxels) that was highly similar to the cluster identified with the correlations with FCSRT total recall score. The same regions were involved, with ventral prefrontal regions extended more anteriorly, beyond the sole subgenual cortex.

DISCUSSION

The main goal of the study was to identify, in bvFTD, the structural grey-matter correlates of episodic memory dysfunctions as measured by the FCSRT. Past neuroimaging studies in the field did rely on other memory tests, which are different in their construct as they do not allow to control for encoding or to delineate free and cued recalls. To our knowledge, only one previous imaging study did investigate the neural correlates of FCSRT scores in bvFTD but through metabolic imaging [7].

In accordance with previous works [6, 7, 28], we first observed that 40% of bvFTD patients had abnormal memory performance characterized by poor retrieval, decreased storage abilities, and low sensitivity to semantic cues. The imaging results showed a lateral temporal involvement related to the free recall score of the test, a large fronto-insulo-striato-cerebello-temporal correlation with FCSRT's total and delayed total recall scores, and a lateral-polar temporal involvement related to the sensitivity to semantic cues during the test. In more detail, the bilateral ventro-median prefrontal cortex (vmPFC), the left hippocampus, left perihippocampal regions, and the bilateral temporal poles in bvFTD showed a significant relationship with the total and delayed total recall of the FCSRT, two measures of memory storage and consolidation. By contrast, regions identified in mild AD were the left amygdala, right vmPFC, left mPFC, left anterior perihippocampal regions, and the right posterior hippocampus. These regions were identified during the first step of our study, based on a visual rating of each patient's scan atrophy, blinded to diagnosis. In this step, all measures of atrophy were entered in an automated linear model (ALM) used to identify the key regions that significantly predicted the FCSRT total recall performance in each group. In a second step, VBM correlation analyses with FCSRT performance in bvFTD identified the same regions as the ALM did, alongside a larger fronto-insulo-temporal network.

In contradiction with the common conception that memory deficits in bvFTD are solely attributed to prefrontal dysfunctions, the correlation between the degree of hippocampal atrophy and memory storage/consolidation deficits was highly expected in our study. Many converging works have indeed shown the role of these regions during encoding and consolidation of episodic memories [see 44] and atrophy of the left hippocampus in particular has been found to correlate with the FCSRT total recall score in AD [22]. Here we show that, similarly to what is observed in AD, the atrophy of the hippocampal/parahippocampal regions is involved in the true memory deficit observed in bvFTD.

Another region identified in our results is the vmPFC. Although its role in autobiographical memory is well known, especially for emotional or self-related items [45, 46], its role in episodic memory as assessed by word-list based tests remains unclear. This region is richly interconnected with multiple structures within the Papez circuit as well as limbic and paralimbic regions involved in memory processing [47]. Its connections with the temporal pole via the ventral branch of the uncinate fascicle are of crucial interest in the context of memory retrieval. This regional combination was found to trigger the retrieval of episodic and factual events [48, 49], and OFC was specifically found to be of critical usefulness during the encoding phase and for applying organizational strategies during the retrieval phase of the CVLT [50]. One interesting interpretation could nicely explain the involvement of the vmPFC during the FCSRT retrieval phases. A recent lesion study showed that impairment of mnemonic monitoring and control was associated with lesions of the subcallosal segment of the vmPFC, the same region found in our VBM results [51]. According to these authors, similarly to the way valuation mechanisms integrate various aspects of a choice into a single subjective value, mnemonic monitoring processes integrate information to subjectively assess the likelihood of a memory being correct or not. Our findings could thus reflect a critical involvement of the atrophy of this region to a failed or imperfect second-order confidence, choice or answer [51]. In other words, the correlation between the vmPFC and FCSRT measures could represent a failed judgement about the accuracy of the given answers related to the semantic cues.

The atrophy of the temporal pole was also correlated to storage and consolidation deficits in our study. Similarly to the vmPFC and hippocampus,

this region was already found to be covaried with memory performance in bvFTD [16] as well as in AD [52]. Clinically based investigations as well as computational models strongly support the critical role of the temporal pole in semantic cognition, acting as an amodal “semantic hub” [53]; however, the role of the temporal pole in verbal memory processing is far less known. Its involvement in episodic memory could only be indirectly suggested by prior studies that have shown how semantic impairment may contribute to deficits in verbal episodic memory or during learning (e.g., [54, 55]). However, one recent work has showed a direct link between temporal pole and episodic verbal memory by showing the impact of temporal pole lesion in false memory [56]. In more detail, this study demonstrated that the temporal pole contains partially overlapping neural representation of related concepts, with the extent of this neural overlap reflecting the semantic similarity between those concepts. As the FCSRT total recall depends on the ability to rely on a given semantic cue (e.g., profession) to retrieve a previously learned word (e.g., plumber), it is easy to understand that providing a semantic cue could open the door to false memories which are closely related to the same semantic concept (e.g., electrician), thus explaining the correlation between temporal pole’s atrophy and the FCSRT total recall score decrease as well as the decrease of sensitivity to semantic cues. Further qualitative studies analyzing the type of errors committed during memory testing by patients could help to confirm that the same mechanism is indeed at play in this context.

Among the other regions involved in memory deficits in bvFTD, our analyses identified the lateral temporal regions, insula, and cerebellum that were correlated to memory storage and consolidation performance. Strong evidence suggests that lateral temporal regions are also involved in semantic processing and that this region carries the neural representation of concrete words in particular [57]. Investigations related to the role of the insula in verbal memory are rare and further studies are needed to fully understand its role in memory processing. Although our data cannot directly address this question, Mesulam and Mufson [58] suggested that insular connections provide a critical anatomical substrate for memory functions and lesion data have supported this assumption [59]. Median and lateral subregions of the cerebellum have already been found to correlate with memory performance (and other cognitive functions) in bvFTD [60] with lobules VII and the

vermis emerging as specific correlates to memory deficit. These results support the concept of a cortical-cerebellar network to support memory processing in bvFTD [61] and highlight the necessity to investigate further the cerebellar contribution in cognitive processing.

Although this study is the first to investigate the structural grey-matter correlates of the FCSRT performance in bvFTD, a recent study focused on the metabolic correlates of this test is of particular interest [7]. To our knowledge, this study was the only previous imaging study focused on FCSRT performance in bvFTD, and it reported that FCSRT total recall score was correlated with lower metabolism in bilateral inferior temporal gyri, right uncus, and right parahippocampus gyri. The same regions (minus parahippocampal regions) were found to be correlated to the total delayed recall score. Interestingly, this study did not report any metabolic correlates in the vmPFC or hippocampus. This absence of result could be due to the inclusion of the MMSE as a covariate, which integrate items assessing memory encoding/retrieval and is also correlated to disease severity. However, the involvement of these two regions together with the temporal pole was reported in virtually all previous structural studies of memory performance in bvFTD, using visual rating scale of atrophy [23, 62], VBM correlation analyses [16, 25, 26], or VBM contrast in bvFTD patients between high and low memory impairment [24], in addition to imaging studies reporting hippocampal degeneration in bvFTD [27, 63, 64]. Taken together, these metabolic and structural findings, including ours, highlight the impact of medial prefrontal and medial/lateral temporal alterations on memory impairments in bvFTD.

The small sample size of the VBM analysis could limit the interpretation of our findings. In addition, the direct contrast between bvFTD and AD groups in VBM has not been investigated because each group was examined with different scanners, and the design of our study did not allow the use of statistical procedures that could control for this bias. Although VBM analyses conducted specifically in the AD subgroup identified FCSRT total recall’s correlates in the hippocampi, retrosplenial, and subcallosal cortices, this result was only obtained at an uncorrected threshold and needs to be replicated in larger sample. Further studies should replicate our findings in a larger sample, ideally with biological data that could support the clinical diagnoses of the patients. These data were not available for the majority of our patients, and thus

we cannot rule out that some bvFTD patients had an underlying AD pathology (or that some AD patients had FTLN pathology). In addition, future studies should employ diffusion tensor imaging procedures to investigate the white matter tracts that could be degenerated in bvFTD and impact memory performance in this disease. Our study suggests that, given the role of vmPFC and temporal limbic structures in memory deficits, the uncinate fasciculus, connecting these structures together, could be a good candidate for a region of interest approach. Another limitation is that this study did not take into account the use of medication that could impact cognition in patients. Although this limit is common to most of the studies in the field, studies that specifically address this question should be conducted to investigate this possible pharmacological impact. Finally, the absence of FLAIR sequence for all participants may have led to the inclusion of patients with vascular impairment although our exclusion criteria may have restrained this limit.

Despite these limitations, the good consistency between visual ratings of atrophy and VBM analyses (both relying on results corrected for multiple comparisons) support the validity of our results. This study thus has important implications for the understanding of memory deficits in bvFTD. In this study, we showed evidences that memory storage functions could be genuinely impaired in bvFTD and that hippocampal, perihippocampal, temporal, and vmPFC regions were found to correlate with these deficits. In line with a recent data-mining cognitive study [30], this contradicts the common view that executive dysfunctions (and thus atrophy in dorsal/cingulate frontal regions) solely cause memory deficits in bvFTD. Another important impact of this study is related to the diagnostic criteria of bvFTD and AD. The well-established link between hippocampus atrophy and FCSRT storage difficulties has driven the conceptualization of the “amnesic syndrome of the hippocampal type” that have been proposed to specifically help the diagnosis of typical AD [2]. By contrast, the “relative preservation of episodic memory” is included in the revised diagnosis criteria for bvFTD [3]. We believe that our results, taken with the growing number of studies that showed a significant proportion of bvFTD patients presenting patent episodic memory impairments are now blurring the line between AD and bvFTD and their clinical distinction [5, 6, 7, 15, 18, 24–26, 28, 30]. Despite their usefulness, there is thus a necessity to revise the current diagnostic criteria for bvFTD, given the

important proportion of amnesic-bvFTD presentation. Future studies on this topic should also review each bvFTD patients’ clinical profile and symptoms in order to check their compatibility with the current revised criteria, data that were not available in the present study.

Furthermore, this study also highlights that current neuropsychological tests of memory functioning may not be appropriate neither to identify the impaired processes, nor to distinguish one disease from another, as it was previously thought. For example, the FCSRT’s free recall has long been considered as a measure of executive processing of memory retrieval, by contrast to total recall, considered as a purest measure of memory storage. However, this study and others did not retrieve any evidences supporting this assumption (e.g., [16, 30]). Also, beyond the group differences that can be statistically observed (e.g., [21]), individual performances show how poor the accuracy of the FCSRT is to distinguish bvFTD from AD because of the significant proportion of amnesic-bvFTD patients [6, 7]. Finally, we believe that word-list based memory assessments are not ecologically valid and should be replaced by tasks more closely related to everyday activities. They have been considered as a useful proxy to assess episodic memory but their “episodic” character is only assumed and lacks support of evidence. Episodic recollection is supposed to imply autoegetic consciousness [65], but this ability is not measured in word-list based tasks and thus, these tests do not comply with this “episodic” criterion [65, 66]. In addition, no real-life situations involve learning and retrieving 16 unrelated words, which is in stark contrast to more ecological paradigms developed recently such as the supermarket task [67] that may have a real potential. Current memory tests such as the RAVLT, FCSRT, or CVLT also involve a strong language component and are thus difficult to use or to interpret in context of aphasia. Beyond memory assessment, our group and others have shown that social cognition has good potential to distinguish bvFTD from AD, even when both diseases present with a severe amnesia [68], as it critically involves the mPFC [69, 70], a region selectively atrophied in bvFTD. Supporting this view, our imaging results show that the mPFC was the region providing the better distinction accuracy between bvFTD and AD. Social cognition may thus be the most interesting cognitive domain to explore as it could provide key elements for the distinction between both diseases.

ACKNOWLEDGMENTS

MB is supported by DistALZ. AI is partially supported by CONICET, CONICYT/FONDECYT (Regular 1170010), FONCYT, PICT (2012-0412 and 2012-1309), CONICYT/FONDAP 15150012, and the INECO Foundation. AS is partially supported by CONICYT/FONDAP 15150012 and CONICYT/FONDECYT Regular 1170010 and 1160940).

Authors' disclosures available online (<https://www.j-alz.com/manuscript-disclosures/17-0771r2>).

SUPPLEMENTARY MATERIAL

The supplementary material is available in the electronic version of this article: <http://dx.doi.org/10.3233/JAD-170771>.

REFERENCES

- [1] Piguet O, Hornberger M, Mioshi E, Hodges JR (2011) Behavioural-variant frontotemporal dementia: Diagnosis, clinical staging, and management. *Lancet Neurol* **10**, 162-172.
- [2] Dubois B, Feldman HH, Jacova C, Hampel H, Molinuevo JL, Blennow K, DeKosky ST, Gauthier S, Selkoe D, Bateman R, Cappa S, Crutch S, Engelborghs S, Frisoni GB, Fox NC, Galasko D, Habert MO, Jicha GA, Nordberg A, Pasquier F, Rabinovici G, Robert P, Rowe C, Salloway S, Sarazin M, Epelbaum S, de Souza LC, Vellas B, Visser PJ, Schneider L, Stern Y, Scheltens P, Cummings JL (2014) Advancing research diagnostic criteria for Alzheimer's disease: The IWG-2 criteria. *Lancet Neurol* **13**, 614-629.
- [3] Rascovsky K, Hodges JR, Knopman D, Mendez MF, Kramer JH, Neuhaus J, van Swieten JC, Seelaar H, Dopper EG, Onyike CU, Hillis AE, Josephs KA, Boeve BF, Kertesz A, Seeley WW, Rankin KP, Johnson JK, Gorno-Tempini ML, Rosen H, Prigleau-Latham CE, Lee A, Kipps CM, Lillo P, Piguet O, Rohrer JD, Rossor MN, Warren JD, Fox NC, Galasko D, Salmon DP, Black SE, Mesulam M, Weintraub S, Dickerson BC, Diehl-Schmid J, Pasquier F, Deramecourt V, Lebert F, Pijnenburg Y, Chow TW, Manes F, Grafman J, Cappa SF, Freedman M, Grossman M, Miller BL (2011) Sensitivity of revised diagnostic criteria for the behavioural variant of frontotemporal dementia. *Brain* **134**, 2456-2477.
- [4] Hornberger M, Piguet O (2012) Episodic memory in frontotemporal dementia: A critical review. *Brain* **135**, 678-692.
- [5] Hornberger M, Piguet O, Graham AJ, Nestor PJ, Hodges JR (2010) How preserved is episodic memory in behavioral variant frontotemporal dementia? *Neurology* **74**, 472-479.
- [6] Bertoux M, de Souza LC, Corlier F, Lamari F, Bottlaender M, Dubois B, Sarazin M (2014) Two distinct amnesic profiles in behavioral variant frontotemporal dementia. *Biol Psychiatry* **75**, 582-588.
- [7] Fernández-Matarrubia M, Matías-Guiu JA, Cabrera-Martín MN, Moreno-Ramos T, Valles-Salgado M, Carreras JL, Matías-Guiu J (2017) Episodic memory dysfunction in behavioral variant frontotemporal dementia: A clinical and FDG-PET study. *J Alzheimers Dis* **57**, 1251-1264.
- [8] Kumfor F, Hutchings R, Irish M, Hodges JR, Rhodes G, Palermo R, Piguet O (2015) Do I know you? Examining face and object memory in frontotemporal dementia. *Neuropsychologia* **71**, 101-111.
- [9] Kammingsa J, O'Callaghan C, Hodges JR, Irish M (2014) Differential prospective memory profiles in frontotemporal dementia syndromes. *J Alzheimers Dis* **38**, 669-679.
- [10] Irish M, Hodges JR, Piguet O (2013) Episodic future thinking is impaired in the behavioural variant of frontotemporal dementia. *Cortex* **49**, 2377-2388.
- [11] Irish M, Hornberger M, Lah S, Miller L, Pengas G, Nestor PJ, Hodges JR, Piguet O (2011) Profiles of recent autobiographical memory retrieval in semantic dementia, behavioural-variant frontotemporal dementia, and Alzheimer's disease. *Neuropsychologia* **49**, 2694-2702.
- [12] Ramanan S, Bertoux M, Flanagan E, Irish M, Piguet O, Hodges JR, Hornberger M (2017) Longitudinal executive function and episodic memory profiles in behavioral-variant frontotemporal dementia and Alzheimer's disease. *J Int Neuropsychol Soc* **23**, 34-43.
- [13] Reul S, Lohmann H, Wiendl H, Duning T, Johnen A (2017) Can cognitive assessment really discriminate early stages of Alzheimer's and behavioural variant frontotemporal dementia at initial clinical presentation? *Alzheimers Res Therapy* **9**, 61.
- [14] Consonni M, Rossi S, Cerami C, Marcone A, Iannaccone S, Francesco Cappa S, Perani D (2017) Executive dysfunction affects word list recall performance: Evidence from amyotrophic lateral sclerosis and other neurodegenerative diseases. *J Neuropsychol* **11**, 74-90.
- [15] Schubert S, Leyton CE, Hodges JR, Piguet O (2016) Longitudinal memory profiles in behavioral-variant frontotemporal dementia and Alzheimer's disease. *J Alzheimers Dis* **51**, 775-782.
- [16] Wong S, Bertoux M, Savage G, Hodges JR, Piguet O, Hornberger M (2016) Comparison of prefrontal atrophy and episodic memory performance in dysexecutive Alzheimer's disease and behavioral-variant frontotemporal dementia. *J Alzheimers Dis* **51**, 889-903.
- [17] Ranasinghe KG, Rankin KP, Pressman PS, Perry DC, Lobach IV, Seeley WW, Coppola G, Karydas AM, Grinberg LT, Shany-Ur T, Lee SE, Rabinovici GD, Rosen HJ, Gorno-Tempini ML, Boxer AL, Miller ZA, Chiong W, DeMay M, Kramer JH, Possin KL, Sturm VE, Bettscher BM, Neylan M, Zackey DD, Nguyen LA, Ketelle R, Block N, Wu TQ, Dallich A, Russek N, Caplan A, Geschwind DH, Vossel KA, Miller BL (2016) Distinct subtypes of behavioral variant frontotemporal dementia based on patterns of network degeneration. *JAMA Neurol* **73**, 1078-1088.
- [18] Mansoor Y, Jastrzab L, Dutt S, Miller BL, Seeley WW, Kramer JH (2015) Memory profiles in pathology or biomarker confirmed Alzheimer disease and frontotemporal dementia. *Alzheimer Dis Assoc Disord* **29**, 135-140.
- [19] Lemos R, Duro D, Simões MR, Santana I (2014) The free and cued selective reminding test distinguishes frontotemporal dementia from Alzheimer's disease. *Arch Clin Neuropsychol* **29**, 670-679.
- [20] Perri R, Fadda L, Caltagirone C, Carlesimo GA (2013) Word list and story recall elicit different patterns of memory deficit in patients with Alzheimer's disease, frontotemporal dementia, subcortical ischemic vascular disease, and Lewy body dementia. *J Alzheimers Dis* **37**, 99-107.
- [21] Teichmann M, Epelbaum S, Samri D, Levy Nogueira M, Michon A, Hampel H, Lamari F, Dubois B (2017) Free and Cued Selective Reminding Test - accuracy for the

- differential diagnosis of Alzheimer's and neurodegenerative diseases: A large-scale biomarker-characterized mono-center cohort study (ClinAD). *Alzheimers Dement* **13**, 913-923.
- [22] Sarazin M, Chauviré V, Gerardin E, Colliot O, Kinkingnéhun S, de Souza LC, Hugonot-Diener L, Garnero L, Lehéricy S, Chupin M, Dubois B (2010) The amnesic syndrome of hippocampal type in Alzheimer's disease: An MRI study. *J Alzheimers Dis* **22**, 285-294.
- [23] Pennington C, Hodges JR, Hornberger M (2011) Neural correlates of episodic memory in behavioral variant frontotemporal dementia. *J Alzheimers Dis* **24**, 261-268.
- [24] Hornberger M, Wong S, Tan R, Irish M, Pigué O, Kril J, Hodges JR, Halliday G (2012) In vivo and post-mortem memory circuit integrity in frontotemporal dementia and Alzheimer's disease. *Brain* **135**, 3015-3025.
- [25] Wong S, Flanagan E, Savage G, Hodges JR, Hornberger M (2014) Contrasting prefrontal cortex contributions to episodic memory dysfunction in behavioural variant frontotemporal dementia and Alzheimer's disease. *PLoS One* **9**, e87778.
- [26] Irish M, Pigué O, Hodges JR, Hornberger M (2014) Common and unique gray matter correlates of episodic memory dysfunction in frontotemporal dementia and Alzheimer's disease. *Hum Brain Mapp* **35**, 1422-1435.
- [27] de Souza LC, Chupin M, Bertoux M, Lehéricy S, Dubois B, Lamari F, Le Ber I, Bottlaender M, Colliot O, Sarazin M (2013) Is hippocampal volume a good marker to differentiate Alzheimer's disease from frontotemporal dementia? *J Alzheimers Dis* **36**, 57-66.
- [28] Marelli C, Gutierrez LA, Menjot de Champfleury N, Charroux C, De Verbizier D, Touchon J, Douillet P, Berr C, Lehmann S, Gabelle A (2015) Late-onset behavioral variant of frontotemporal lobar degeneration versus Alzheimer's disease: Interest of cerebrospinal fluid biomarker ratios. *Alzheimers Dement (Amst)* **1**, 371-379.
- [29] Thomas-Anterion C, Jacquin K, Laurent B (2000) Differential mechanisms of impairment of remote memory in Alzheimer's and frontotemporal dementia. *Dement Geriatr Cogn Disord* **11**, 100-106.
- [30] Bertoux M, Ramanan S, Slachevsky A, Wong S, Henriquez F, Musa G, Delgado C, Flanagan E, Bottlaender M, Sarazin M, Hornberger M, Dubois B (2016) So close yet so far: Executive contribution to memory processing in behavioral variant frontotemporal dementia. *J Alzheimers Dis* **54**, 1005-1014.
- [31] McKhann GM, Knopman DS, Chertkow H, Hyman BT, Jack Jr CR, Kawas CH, Klunk WE, Koroshetz WJ, Manly JJ, Mayeux R, Mohs RC, Morris JC, Rossor MN, Scheltens P, Carrillo MC, Thies B, Weintraub S, Phelps CH (2011) The diagnosis of dementia due to Alzheimer's disease: Recommendations from the National Institute on Aging-Alzheimer's Association workgroups on diagnostic guidelines for Alzheimer's disease. *Alzheimers Dement* **7**, 263-269.
- [32] Morris JC (1993) The Clinical Dementia Rating (CDR): Current version and scoring rules. *Neurology* **43**, 2412-2414.
- [33] Yang H (2013) The case for being automatic: Introducing the automatic linear modeling (LINEAR) procedure in SPSS statistics. *Multiple Linear Regression Viewpoints* **39**, 27-37.
- [34] Ashburner J, Friston, KJ (2000) Voxel-based morphometry - the methods. *Neuroimage* **11**, 805-821.
- [35] Good CD, Johnsrude IS, Ashburner J, Henson RN, Friston KJ, Frackowiak RS (2001) A voxel-based morphometric study of ageing in 465 normal adult human brains. *Neuroimage* **14**, 21-36.
- [36] Smith SM, Jenkinson M, Woolrich MW, Beckmann CF, Behrens TE, Johansen-Berg H, Bannister PR, De Luca M, Drobnjak I, Flitney DE, Niazy RK, Saunders J, Vickers J, Zhang Y, De Stefano N, Brady JM, Matthews PM (2004) Advances in functional and structural MR image analysis and implementation as FSL. *Neuroimage* **23**, S208-S219.
- [37] Zhang Y, Brady M, Smith S (2001) Segmentation of brain MR images through a hidden Markov random field model and the expectation-maximization algorithm. *IEEE Trans Med Imaging* **20**, 45-57.
- [38] Andersson JLR, Jenkinson M, Smith S (2007) Non-linear optimisation. FMRIB technical report TR07JA2. <http://www.fmrib.ox.ac.uk/analysis/techrep>
- [39] Andersson JLR, Jenkinson M, Smith S (2007) Non-linear registration, aka Spatial normalisation. FMRIB technical report TR07JA2. <http://www.fmrib.ox.ac.uk/analysis/techrep>
- [40] Rueckert D, Sonoda LI, Hayes C, Hill DL, Leach MO, Hawkes DJ (1999) Nonrigid registration using free-form deformations: Application to breast MR images. *IEEE Trans Med Imaging* **18**, 712-721.
- [41] Good CD, Scallan RI, Fox NC, Ashburner J, Friston KJ, Chan D, Crum WR, Rossor MN, Frackowiak RS (2002) Automatic differentiation of anatomical patterns in the human brain: Validation with studies of degenerative dementias. *Neuroimage* **17**, 29-46.
- [42] Smith SM, Nichols TE (2009) Threshold-free cluster enhancement: Addressing problems of smoothing, threshold dependence and localisation in cluster inference. *Neuroimage* **44**, 83-98.
- [43] Sarazin M, Berr C, De Rotrou J, Fabrigoule C, Pasquier F, Legrain S, Michel B, Puel M, Volteau M, Touchon J, Verny M, Dubois B (2007) Amnesic syndrome of the medial temporal type identifies prodromal AD: A longitudinal study. *Neurology* **69**, 1859-1867. Erratum in: *Neurology* (2008) **70**, 2016.
- [44] Squire LR (2004) Memory systems of the brain: A brief history and current perspective. *Neurobiol Learn Mem* **82**, 171-177.
- [45] Markowitsch HJ, Vandekerckhove MM, Lanfermann H, Russ MO (2003) Engagement of lateral and medial prefrontal areas in the ephory of sad and happy autobiographical memories. *Cortex* **39**, 643-665.
- [46] Piefke M, Weiss PH, Zilles K, Markowitsch HJ, Fink GR (2003) Differential remoteness and emotional tone modulate the neural correlates of autobiographical memory. *Brain* **126**, 650-668.
- [47] Carmichael ST, Price JL (1995) Limbic connections of the orbital and medial prefrontal cortex in macaque monkeys. *J Comp Neurol* **363**, 615-641.
- [48] Habib R, Nyberg L, Tulving E (2003) Hemispheric asymmetries of memory: The HERA model revisited. *Trends Cogn Sci* **7**, 241-245.
- [49] Fink GR (2003) In search of one's own past: The neural bases of autobiographical memories. *Brain* **126**, 1509-1510.
- [50] Savage CR, Deckersbach T, Heckers S, Wagner AD, Schacter DL, Alpert NM, Fischman AJ, Rauch SL (2001) Prefrontal regions supporting spontaneous and directed application of verbal learning strategies: Evidence from PET. *Brain* **124**, 219-231.
- [51] Hebscher M, Barkan-Abramski M, Goldsmith M, Aharon-Peretz J, Gilboa A (2016) Memory, decision-making, and the ventromedial prefrontal cortex (vmPFC): The

- roles of subcallosal and posterior orbitofrontal cortices in monitoring and control processes. *Cereb Cortex* **26**, 4590-4601.
- [52] Wolk DA, Dickerson BC, Alzheimer's Disease Neuroimaging Initiative (2011) Fractionating verbal episodic memory in Alzheimer's disease. *Neuroimage* **54**, 1530-1539.
- [53] Patterson K, Nestor PJ, Rogers TT (2007) Where do you know what you know? The representation of semantic knowledge in the human brain. *Nat Rev Neurosci* **8**, 976-987.
- [54] Goldblum MC, Gomez CM, Dalla Barba G, Boller F, Deweer B, Hahn V, Dubois B (1998) The influence of semantic and perceptual encoding on recognition memory in Alzheimer's disease. *Neuropsychologia* **36**, 717-729.
- [55] Casaletto KB, Marx G, Dutt S, Neuhaus J, Saloner R, Kritikos L, Miller B, Kramer JH (2017) Is "learning" episodic memory? Distinct cognitive and neuroanatomic correlates of immediate recall during learning trials in neurologically normal aging and neurodegenerative cohorts. *Neuropsychologia* **102**, 19-28.
- [56] Chadwick MJ, Anjum RS, Kumaran D, Schacter DL, Spiers HJ, Hassabis D (2016) Semantic representations in the temporal pole predict false memories. *Proc Natl Acad Sci U S A* **113**, 10180-10185.
- [57] Wang J, Conder JA, Blitzer DN, Shinkareva SV (2010) Neural representation of abstract and concrete concepts: A meta-analysis of neuroimaging studies. *Hum Brain Mapp* **31**, 1459-1468.
- [58] Mesulam MM, Mufson EJ (1982) Insula of the old world monkey. III: Efferent cortical output and comments on function. *J Comp Neurol* **212**, 38-52.
- [59] Manes F, Springer J, Jorge R, Robinson RG (1999) Verbal memory impairment after left insular cortex infarction. *J Neurol Neurosurg Psychiatry* **67**, 532-534.
- [60] Tan RH, Devenney E, Kiernan MC, Halliday GM, Hodges JR, Hornberger M (2015) Terra incognita-cerebellar contributions to neuropsychiatric and cognitive dysfunction in behavioral variant frontotemporal dementia. *Front Aging Neurosci* **7**, 121.
- [61] Guo CC, Tan R, Hodges JR, Hu X, Sami S, Hornberger M (2016) Network-selective vulnerability of the human cerebellum to Alzheimer's disease and frontotemporal dementia. *Brain* **139**, 1527-1538.
- [62] Lavenu I, Pasquier F, Lebert F, Pruvo JP, Petit H (1998) Explicit memory in frontotemporal dementia: The role of medial temporal atrophy. *Dement Geriatr Cogn Disord* **9**, 99-102.
- [63] van de Pol LA, Hensel A, van der Flier WM, Visser PJ, Pijnenburg YA, Barkhof F, Gertz HJ, Scheltens P (2006) Hippocampal atrophy on MRI in frontotemporal lobar degeneration and Alzheimer's disease. *J Neurol Neurosurg Psychiatry* **77**, 439-442.
- [64] Rabinovici GD, Seeley WW, Kim EJ, Gorno-Tempini ML, Rascovsky K, Pagliaro TA, Allison SC, Halabi C, Kramer JH, Johnson JK, Weiner MW, Forman MS, Trojanowski JQ, Dearmond SJ, Miller BL, Rosen HJ (2007) Distinct MRI atrophy patterns in autopsy-proven Alzheimer's disease and frontotemporal lobar degeneration. *Am J Alzheimers Dis Other Dement* **22**, 474-488.
- [65] Tulving E (1984) Précis of Element of episodic memory. *Behav Brain Sci* **7**, 223-268.
- [66] Pause BM, Zlomuzica A, Kinugawa K, Mariani J, Pietrowsky R, Dere E (2013) Perspectives on episodic-like and episodic memory. *Front Behav Neurosci* **7**, 33.
- [67] Tu S, Wong S, Hodges JR, Irish M, Piguet O, Hornberger M (2015) Lost in spatial translation - A novel tool to objectively assess spatial disorientation in Alzheimer's disease and frontotemporal dementia. *Cortex* **67**, 83-94.
- [68] Bertoux M, de Souza LC, O'Callaghan C, Greve A, Sarazin M, Dubois B, Hornberger M (2016) Social cognition deficits: The key to discriminate behavioral variant frontotemporal dementia from Alzheimer's disease regardless of amnesia? *J Alzheimers Dis* **49**, 1065-1074.
- [69] Bertoux M, Volle E, Funkiewiez A, de Souza LC, Leclercq D, Dubois B (2012) Social Cognition and Emotional Assessment (SEA) is a marker of medial and orbital frontal functions: A voxel-based morphometry study in behavioral variant of frontotemporal degeneration. *J Int Neuropsychol Soc*, **18**, 972-985.
- [70] Bertoux M, Volle E, de Souza LC, Funkiewiez A, Dubois B, Habert MO (2014) Neural correlates of the mini-SEA (Social Cognition and Emotional Assessment) in behavioral variant frontotemporal dementia. *Brain Imaging Behav* **8**, 1-6.