

Neuroanatomical Comparison of the “Word” and “Picture” Versions of the Free and Cued Selective Reminding Test in Alzheimer’s Disease

Andrea Slachevsky^{a,b,c,d,e,f}, Paulo Barraza^d, Michael Hornberger^{f,g}, Carlos Muñoz-Neira^c, Emma Flanagan^f, Fernando Henríquez^{b,d}, Eduardo Bravo^h, Mauricio Farías^h and Carolina Delgadoⁱ

^a*Gerosciences Center for Brain Health and Metabolism, Providencia, Santiago, Chile*

^b*Laboratory of Neuropsychology and Clinical Neuroscience (LANNEC), Physiopathology Program – ICBM, Neurological Sciences Department and Neurology Department, Faculty of Medicine, Universidad de Chile Santiago, Santiago, Chile*

^c*Memory and Neuropsychiatric Clinic (CMYN), Neurology Service – Hospital del Salvador and Faculty of Medicine, University of Chile, Santiago, Chile*

^d*Center for Advanced Research in Education (CIAE), Universidad de Chile, Santiago, Chile*

^e*Department of Neurology, Clínica Alemana – Universidad del Desarrollo, Santiago, Chile*

^f*Norwich Medical School, University of East Anglia, Norwich, UK*

^g*DCLL, Norfolk and Suffolk NHS Foundation Trust, Norwich, UK*

^h*Department of Neuroradiologic, Institute of Neurosurgery Asenjo, Santiago, Chile*

ⁱ*Department of Neurology and Neurosurgery, Clinical Hospital, Universidad de Chile, Santiago, Chile*

Handling Associate Editor: Christine Bastin

Accepted 19 September 2017

Abstract. Episodic memory tests with cued recall, such as the Free and Cued Selective Reminding Test (FCSRT), allow for the delineation of hippocampal and prefrontal atrophy contributions to memory performance in Alzheimer’s disease (AD). Both Word and Picture versions of the test exist but show different profiles, with the Picture version usually scoring higher across different cohorts. One possible explanation for this divergent performance between the different modality versions of the test might be that they rely on different sets of neural correlates. The current study explores this by contrasting the neural correlates of the Word and Picture versions of the FCSRT with voxel-based morphometry (VBM) in AD and healthy subjects. We predicted that the Picture version would be associated with different cortical regions than the Word version, which might be more hippocampal-centric. When comparing 35 AD patients and 34 controls, AD patients exhibited impairments on both versions of the FCSRT and both groups performed higher in the Picture version. A region of interest analysis based on prior work revealed significant correlations between free recall of either version with atrophy of the temporal pole and hippocampal regions. Thus, contrary to expectations, performance on both the Word and the Picture version of the FCSRT is associated with largely overlapping networks. Free recall is associated with hippocampal volume and might be properly considered as an indicator of hippocampal structural integrity.

Keywords: Alzheimer’s disease, biomarkers, episodic memory, FCSRT Picture version, FCSRT Word version, Free and Cued Selective Reminding Test, hippocampus, voxel based morphometry

* Correspondence to: Dr. Andrea Slachevsky, Gerosciences Center for Brain Health and Metabolism, Facultad de Medicina, Universidad de Chile, Avenida Salvador 486, Providencia,

Santiago, Chile. Tel.: +56 (2)29770530; E-mail: andrea.slachevsky@uchile.com.

INTRODUCTION

Dementia rates are increasing on a global scale, especially in Latin America and Asia, where Alzheimer's disease (AD) is the most prevalent type of dementia [1, 2]. Its amnesic type, characterized by a marked impairment in both the encoding and recall of new information, is the most common syndromic presentation of AD [3, 4]. This amnesic form of AD has been associated with neuropathological changes of the anatomical structures related to episodic memory, mainly the hippocampi and other structures of the medial temporal lobes [5, 6]. In particular, dysfunction of the hippocampal complex in AD leads to a specific episodic memory impairment characterized by a diminished free recall that is only marginally improved by providing a cue [7]. Such memory impairment can be better detected using a cued recall assessment, which is capable of isolating AD-typical hippocampal involvement in the most effective manner, increasing the accuracy of the diagnosis in AD [8, 9]. In this respect, the Free and Cued Selective Reminding Test (FCSRT), a cued recall evaluation for episodic memory, has proven to be an effective tool to detect AD at its early stages [10, 11], and predict future cases of AD dementia [7, 12, 13]. It identifies patients with mild cognitive impairment (MCI) who are at a higher risk for developing AD [7] and also differentiates AD from other types of dementia [14, 15].

Two versions of the FCSRT with stimuli in different modalities have been widely used, namely the "Word" (verbal) [7, 12] and "Picture" (visual) versions [10]. In a previous study [16], the authors of the present investigation reported that both the Word and Picture versions of the FCSRT present almost the same diagnostic utility for the diagnosis of mild AD, although the scores obtained from the Picture version were significantly higher on the total recall than those of the Word version in mild AD patients and controls [16]. On one hand, these results suggest that the Picture version of the FCSRT might be easier than its Word version, or alternatively, that mild AD patients benefit more from pictures than from words. The latter explanation could suggest involvement of different cognitive processes and therefore different neural networks supporting performance on each version of the test. PET studies have reported an association between free recall of the Word version of the FCSRT and right frontal perfusion, with cued recall associated instead with parahippocampal metabolism [17]. Furthermore, structural neuroimaging studies

with the FCSRT Word version have exhibited an association between free recall and hippocampal volume measured with MRI-based volumetry in AD and MCI patients [18–20]. Free recall of the Picture version has been associated with left and right hippocampal volume, although the association was either stronger for left hippocampal, or only reported for the left hippocampal volume in AD patients and non-demented elderly people [21, 22]. Recall of the spatial localization of items has been associated with bilateral hippocampal volumes, although somewhat stronger with the right hippocampal volume in AD patients [21].

To the best of our knowledge, no studies have made a direct comparison between the Word and Picture versions of the FCSRT within the same population of mild AD patients. Likewise, the main objective of this study is to elucidate whether there actually are differential neural correlates for the Word or Picture versions of the FCSRT concerning episodic memory performance. As the main objective of our study was to compare the neural correlates of both modalities of presentation of the FCSRT, we focused on a single measure of FCSRT (free recall). This aim was addressed using voxel-based morphometry (VBM) analyses across a sample of mild AD patients and cognitively normal controls. We predicted that performances on the Word version of the FCSRT would be inversely associated with left hippocampal atrophy and the Picture version with bilateral hippocampal atrophy. Additionally, we expected that the performance on the Picture version would rely more on other cortical structures, than the hippocampus. Hence we predicted that other cortical areas, such as higher visual association area in the ventral pathway, mainly the fusiform and the parahippocampal area, would be more involved in the Picture version than in the Word version, which would be more hippocampal-centric. This difference would reflect the less pronounced impairment in free and total recall of the Picture version in comparison with the Word version of the FCSRT in patients with AD [23].

METHODS

Participants

The sample consisted of 69 participants in this study. This cohort was divided into two groups matched by sex, age, and years of education and included 35 subjects with a clinical diagnosis of AD and 34 cognitively normal (CN) subjects.

All patients considered in this study were recruited from two Memory Clinics: the Cognitive Neurology and Dementia Unit of the Neurology Department at Hospital del Salvador and Faculty of Medicine, Universidad de Chile, and the Neuropsychology Unit of the Neurology and Neurosurgery Department at Hospital Clínico Universidad de Chile (HCUCH), which are both located in Santiago, Chile. CN subjects were recruited from a variety of sources, including spouses or relatives of the patients with dementia also considered in this investigation and older adults who regularly attended community groups of elderly people. Inclusion criteria considered Spanish-speaking participants older than 60 years of age with a proper capacity to provide consent for research, whether they were patients diagnosed with AD or cognitively healthy individuals. All participants required a reliable proxy, such as a carer, who had known them for at least 5 years. Specifically, a person that was able to provide information about the activities of daily living performance and the behavior of the participants as well as a general medical history was considered a proxy. The exclusion criteria entailed illiteracy, underlying neurological or psychiatric illness that could affect cognition (except for AD) such as significant head injuries, movement disorders, cerebrovascular diseases, alcohol and other drug abuse, physical disability, sensory disturbances, or disabling cognitive impairment that could interfere with the neuropsychological assessment, and the absence of a reliable proxy. All AD patients met the NINCDS-ADRDA criteria for probable AD [24]. Diagnosis was made by consensus between senior neurologists (AS and CD) based on extensive clinical investigations, interviews with a reliable proxy, laboratory tests, and global cognitive functioning. Briefly, AD patients displayed a history of significant episodic memory loss, within the context of a preserved behavioral and personality score above 0.5 on the Clinical Dementia Rating scale (CDR) (25 with CDR = 1; 8 patients with CDR = 2; 2 with CDR = 3) [25]. CN subjects did not report memory complaints, had a score of 0 on the CDR [25], and their cognitive performance was considered as normal according to local normative data for the Addenbrooke's Cognitive Examination – Revised Chilean Version (ACE-R-Ch) (>76) [26]. Scores of the FCSRT were not considered to establish the diagnosis.

Ethical approval for this study was obtained from the Ethical and Scientific Committee of the East Metropolitan Health Service and HCUCH Ethic Committee in Santiago, Chile. All participants, or

their person responsible, provided informed consent in accordance with the Declaration of Helsinki.

Clinical and neuropsychological examination

All proxies were interviewed together with the participants in order to estimate the CDR scores of the sample. Concerning neuropsychological assessment, experienced clinical psychologists extensively trained at conducting neuropsychological evaluations (CMN and FH) and blinded to the condition of each subject administered a battery of tools that, in addition to both Word and Picture FCSRT versions to measure episodic memory, included the Mini-Mental State Examination (MMSE) [27], the Montreal Cognitive Assessment (MoCA) [28], and the Addenbrooke's Cognitive Examination-Revised, Chilean version (ACE-R-Ch) [26] to assess global cognitive functioning; the Boston Naming Test as an index of naming; the Rey-Osterrieth Complex Figure Test as an indicator of visuospatial constructional ability [29]; the Forward and Backward Digit-Span task as an index of working memory; the Frontal Assessment Battery (FAB) [30], the Modified Version of the Wisconsin Card Sorting Test (MCST) [31], Verbal Fluency tests [Phonemic Verbal Fluency test (i.e., words beginning with letters A, F, and S in 1 min) and Semantic Fluency test (i.e., animals in 1 min)] and the Trail Making Test A and B [32] as indicators of executive function (EF) (see Supplementary Material).

Episodic Memory testing: Word and Picture FCSRT versions

Spanish versions of the Word and Picture FCSRT were conducted on the entire sample. The Word version of the Spanish FCSRT (words as stimuli) was first administered, and seven days later the Picture version of the Spanish FCSRT was applied (black and white line drawings). The Verbal and the Picture versions of the test used different semantic categories (items) to avoid a learning effect between both versions of the test.

Both versions of the FCSRT were conducted according to the procedure defined by Grober and Buschke [33] and described in detail elsewhere [16]. The FCSRT is based on a semantic cueing method that controls for effective encoding of 16 words or pictures and facilitates retrieval by semantic cueing. Immediate cued recall is tested in a first phase to control for encoding (encoding score). Then, the memory

phase is performed in three successive trials. The learning phase of the 16 items was followed by one minute of counting backwards to avoid the recency (short-term memory) effect. This interference task was followed by a free recall trial for all 16 items, and a cued recall trial for those items not retrieved at free recall, and for which the same semantic cues as those used during encoding were verbally given. The first and second recall trials were followed by 20 seconds of counting backwards [17]. Overall, both versions of the FCSRT yield several memory measurements, namely the immediate recall (IR) (for the study phase), free recall (FR), cued recall, total recall (TR) scores (maximum score = 48) and sensitivity to cueing index (for the memory phase). As other studies, we did not include the delayed recall and recognition phase in this study, to avoid extending the neuropsychological assessment. It should be noted that the Word and Picture versions of the FCSRT are both ‘verbal memory tasks’ as they both require ‘verbal processing’ while they are being performed encoding, consolidating, recalling or retrieving. The main difference is that the Picture version uses visual items in the test administration.

Statistical analyses for demographical and neuropsychological data

The Statistical Package for the Social Sciences (SPSS) version 20 for Windows (IBM Corp., Armonk, NY, USA) was used to analyze the demographic and neuropsychological data. Together with estimating descriptive indicators for the latter, comparisons between AD and CN subjects were conducted using chi-squared tests for the categorical variables and unpaired two-tailed *t*-tests for the continuous variables. Differences with a $p < 0.05$ were considered significant. In addition, the effect sizes (Cohen’s *d* statistic) were calculated to determine the magnitude of the group differences. According to Cohen, effect sizes between 0.2 and 0.49 are considered small; those between 0.5 and 0.79, moderate; and those 0.8, large [34].

MRI acquisition

MRI acquisition was performed on two 1.5 Tesla MRI scanners, a Philips Intera Nova Dual gradient system (45 mT/m), and a Siemens Symphony Maestro Class (Ernlagen, Germany) with 20 mT/m gradient system. High resolution anatomical scans were obtained using a T1-weighted

three-dimensional gradient recalled echo acquisition: 3D T1 fast field echo sequence on Philips scanner, and 3D T1 fast low angle shot on Siemens scanner, both with the same acquisition parameters (TE = 4.6 ms, TR = 25 ms; flip angle = 30°, field of view on frequency = 250 mm, 256 × 256 matrix, isotropic voxel size 1 × 1 × 1 mm). We present a comparison between subjects scanned at each scanner in Supplementary Table 2. AD subjects scanned are comparable except for performance in total visual recall.

Statistical analyses for neuroimaging data

VBM analysis

MRI data were analyzed with FSL-VBM, a VBM analysis [35, 36] that is part of the FSL software package (http://www.fmrib.ox.ac.uk/fsl/fsl_vbm/index.html) [37]. First, tissue segmentation was carried out using FMRIB’s Automatic Segmentation Tool (FAST) [38] from brain-extracted images. The resulting grey matter partial volume maps were then aligned to the Montreal Neurological Institute standard space (MNI152) using the nonlinear registration approach using FNIRT [39, 40] which uses a b-spline representation of the registration warp field [41]. As visual inspection revealed that none of the controls had hippocampal atrophy, we boosted statistical power by conducting the analysis across controls and patients, as the controls would not have memory deficits or hippocampal atrophy, as reported in our previous work [42, 43]. A study-specific template was created, combining AD and CN images, to which the native grey matter images were re-registered nonlinearly. This procedure reduces anatomical biases compared to studies including only a patient group [44]. The registered partial volume maps were then modulated (to correct for local expansion or contraction), by dividing them by the Jacobian of the warp field. The modulated images were then smoothed with an isotropic Gaussian kernel with a sigma of 3 mm (FWHM: 8 mm). Because we had strong regional a priori, based on previous literature [42], a region of interest (ROI) mask for prefrontal and medial temporal brain regions was created, by using the Harvard-Oxford cortical and subcortical structural atlas. The following atlas regions were included in the mask: hippocampus, parahippocampal gyrus, fusiform cortex, temporal pole, superior frontal gyrus, middle frontal gyrus, inferior frontal gyrus, orbitofrontal gyrus, subcallosal cortex, medial prefrontal cortex, paracingulate gyrus, anterior cingu-

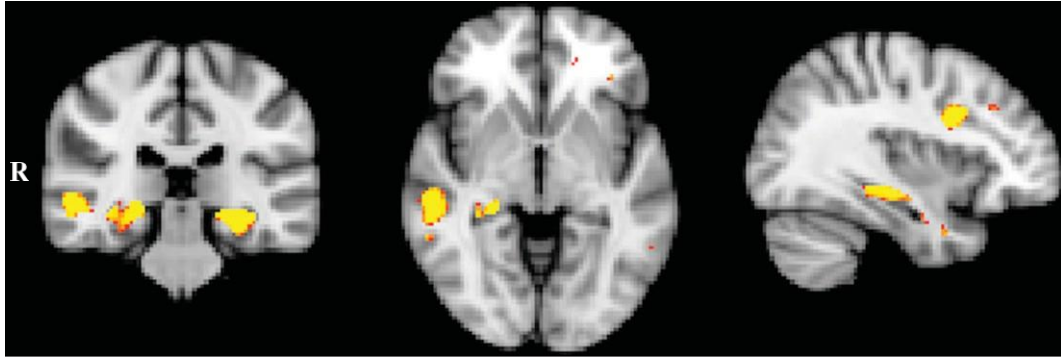


Fig. 1. VBM analysis showing brain areas of decreased gray matter intensity in AD patients in comparison with Controls (MNI coordinates $X = 36$; $Y = -30$; $Z = -4$). Colored voxel show regions that were significant in the analysis with $p < 0.05$ corrected for multiple comparisons (FWE), with a cluster threshold of 100 contiguous voxels. Clusters are overlaid on the MNI standard brain.

late gyrus, and frontal pole. The statistical analysis was performed by employing a voxel-wise general linear model (GLM) which was applied to investigate grey matter intensity differences, and permutation-based nonparametric testing (with 5000 permutations per contrast) [45] was used to form clusters with the threshold-free cluster enhancement method [46], tested for significance at $p < 0.05$, and corrected for multiple comparisons via Family-wise Error (FWE) correction across space, unless otherwise stated. In that case, a threshold of 100 contiguous voxels was used, uncorrected at the $p < 0.001$ threshold.

In a first step, differences in gray matter intensities between AD patients and CN subjects were assessed. To control for a possible scanner effect, we introduced these data as a covariate (see Supplementary Table 3 and Figure 1). Next, correlations between gray matter atrophy and Word and Picture free recall scores of the FCSRT were entered as covariates in the design matrix of the VBM analysis for AD patients combined with controls. It has been previously reported [47] that this procedure improves the statistical power to detect brain-behavior relationships. In a third step, an overlap analysis was conducted to identify common regions of gray matter atrophy correlating with both Word and Picture free recall scores. The statistical maps generated from the contrast using Word and Picture free recall scores as a covariate, were scaled using a threshold of $p < 0.01$, following which, the scaled contrasts were multiplied to create an inclusive, or overlap, mask across groups. In a final step, we performed a contrast analysis between Word and Picture versions to study the existence of significant anatomical differences between both versions. For the exclusive masks, the same procedure as

above was adopted; however, the scaled images were subsequently divided by each other, to create an exclusive mask for each condition.

For all covariate analyses, a threshold of 100 contiguous voxels was used, with FWE correction at the $p < 0.05$ threshold, unless otherwise stated. In that case, a threshold of 100 contiguous voxels was used, uncorrected at the $p < 0.001$ threshold. Regions of significant atrophy were superimposed on the MNI standard brain, with maximum coordinates provided in MNI space. Areas of significant gray matter loss were localized with reference to the Harvard-Oxford probabilistic cortical and subcortical atlas. For statistical power, we used a covariate-only statistical model with a t-contrast, providing an index of association between brain atrophy and episodic memory performance on the experimental measures.

RESULTS

Demographic and neuropsychological data

Demographics and neuropsychological scores are shown in Table 1. AD and control groups did not differ in terms of sex, age or education (all $ps > 0.05$). In brief, AD patients exhibited scores significantly higher on assessments of severity of the disease (CDR) and lower on measures of global cognitive efficiency (ACE-R-Ch, MMSE, and MoCA) and episodic memory (free and total recall of Word and Picture versions of the FCSRT) than those observed for CN subjects. Compared to the CN group, the AD group was significantly impaired on all scores of the Word and Picture versions of the FCSRT. Still, both controls and AD patients performed better in

Table 1
Demographic characteristics of Alzheimer's disease patients and normal controls

	AD	Controls	<i>t</i> -test / χ^2	Effect Size (<i>d</i>) ¹
Number of cases	35	34		
Male / Female	15 (42.8%) / 20 (57.14%)	11 (32.35%) / 23 (67.64%)	0.368	
Age (y)	74.23 ± 6.59 (63–88)	72 ± 5.8 (64–87)	-1.489	0.359
Education (y)	11.06 ± 4.99	12.94 ± 3.77	1.764	-0.425
MMSE	21.14 ± 4.69 (7–28)	28.26 ± 1.63 (24–30)	8.358*	-2.027
ACE-R	63.34 ± 15.25 (28–89)	93.00 ± 5.34 (79–100)	10.716*	-2.595
MoCA	14.23 ± 5.61 (3–24)	25.09 ± 3.35 (18–30)	9.718*	-2.350
CDR	1.23 ± 0.69 (1–3)	0 ± 0 (0–0)	-1.22*	-2.52
CDR-SB ^ε	5.41 ± 2.72 (1–11)	0 ± 0 (0–0)	-5.41*	-2.81
Word version				
Free Recall	8.09 ± 6.67 (0–30)	27.85 ± 6.48 (13–39)	12.480*	-3.005
Total recall	22.17 ± 13 (1–47)	44.56 ± 3.41 (37–48)	9.714*	-2.356
Picture version ^ε				
Free Recall	12.29 ± 9.22 (0–35)	33.24 ± 4.67 (20–40)	11.844*	-2.866
Total recall	32.83 ± 11.95 (4–48)	47.12 ± 2.02 (37–48)	6.876*	-1.667

ACE-R, Addenbrooke's Cognitive Examination Revised; AD, Alzheimer's disease; ^εAD patients and controls showed significantly higher scores in the Picture version compared to the Word version of the FCSRT. CDR, Clinical Dementia Rating; CDR-SB, CDR- Sum of box. ¹Cohen's *d* **p* < 0.001. MMSE, Mini-Mental State Examination, MoCA, Montreal Cognitive Assessment; Data are presented in mean ± standard deviation (minimum–maximum).

Table 2
VBM results showing regions of significant gray matter intensity decrease for the contrast of AD and Control groups corrected by scanner type

Regions	Hemisphere	MNI coordinates			Number of voxels
		x	y	z	
Hippocampus	Left	-24	-30	-12	975
Hippocampus	Right	24	-32	-8	812
Middle temporal gyrus, posterior division	Right	56	-36	-4	404
Inferior frontal gyrus, par opercularis/precentral gyrus	Right	36	8	24	238
Precentral gyrus / inferior frontal gyrus, par opercularis	Left	-36	4	26	170
Middle temporal gyrus, temporooccipital part	Left	-56	-50	-8	100

All results corrected for multiple comparisons (FWE) at *p* < 0.05; only cluster with at least 100 contiguous voxels included. MNI, Montreal Neurological Institute.

the Picture compared to the Word version of the task (see Table 1). (The details of the neuropsychological battery in CN and AD subjects are shown in Supplementary Table 1).

VBM: Group comparison analysis

Results are shown in Table 2 and Fig. 1. The AD group was contrasted with the CN group to reveal patterns of brain atrophy in the fronto-medial temporal mask. The AD group showed significant grey matter atrophy in bilateral hippocampal brain regions, and a more right lateralized atrophy in the posterior part of the middle temporal gyrus, as well as atrophy involving both bilateral precentral and inferior gyri (par opercularis) (*p* fweccorr < 0.05). The same results were obtained in the analysis including the scanner as a covariate (see Supplementary Table 2 and Supplementary Figure 1).

VBM: Correlations with free recall scores of the Word version and the Picture version of the FCSRT

Results are shown in Table 3 and Fig. 2. Free recall scores of the FCSRT Word and Picture versions were entered as covariates in the design matrix of the VBM analysis. For the AD patients combined with controls, the free recall score of both the Word and Picture versions covaried with atrophy in the left temporal pole and bilateral hippocampal brain regions (*p* fweccorr < 0.05). The Word version also covaried with atrophy in the right middle frontal gyrus (*p* fweccorr < 0.05).

VBM: Overlapping pattern of the Word and Picture versions of the FCSRT

Results are shown in Fig. 3. For the AD group combined with controls, the free recall score of the

Table 3
 VBM results showing regions of significant gray matter intensity decrease that covary with free recall performance in AD combined with Controls, for the Word and Picture versions of the FCSRT

Regions	Hemisphere	MNI coordinates			Number of voxels
		x	y	z	
Word version					
Temporal pole	Left	-38	6	-32	666
Hippocampus	Right	32	-6	-26	305
Middle frontal gyrus	Right	34	30	32	211
Hippocampus	Left	-22	-30	-8	146
Picture version					
Temporal pole	Left	-36	6	-32	920
Hippocampus	Right	32	-6	-26	479
Hippocampus	Left	-24	-32	-10	176

All results corrected for multiple comparisons (FWE) at $p < 0.05$. Only cluster with at least 100 contiguous voxels included. MNI, Montreal Neurological Institute.

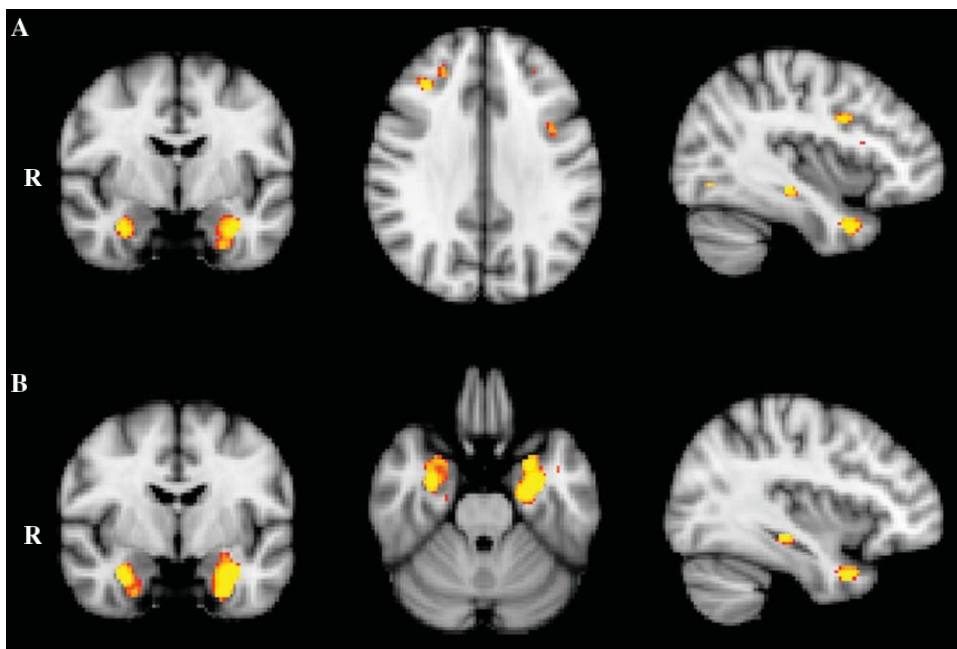


Fig. 2. VBM analysis showing brain areas in which gray matter intensity correlates significantly with free recall performance in AD in comparison with Controls, for (A) Word (MNI coordinates $X = -38$; $Y = -6$; $Z = 32$) and (B) Picture (MNI coordinates $X = -36$; $Y = -6$; $Z = -26$) versions of the FCSRT. Colored voxel in A and B show regions that were significant in the analysis with $p < 0.05$ corrected for multiple comparisons (FWE). For all analysis, a cluster threshold of 100 contiguous voxels was used. Clusters are overlaid on the MNI standard brain.

Word and Picture versions of the FCSRT showed high atrophy overlap mainly in the left temporal pole and hippocampal regions.

VBM: Differential patterns of the Word and Picture versions of the FCSRT

Results are shown in Fig. 4. For the AD group combined with controls, only the free recall score of the Word version covaried with atrophy in the right

middle frontal gyrus ($p_{fwecorr} < 0.05$). The free recall score of the Picture version covaried only with atrophy in the right and left parahippocampus regions and the right temporal fusiform region ($p_{fwecorr} < 0.05$).

DISCUSSION

Our results showed that free recall for both the Word and Picture versions of the FCSRT correlated

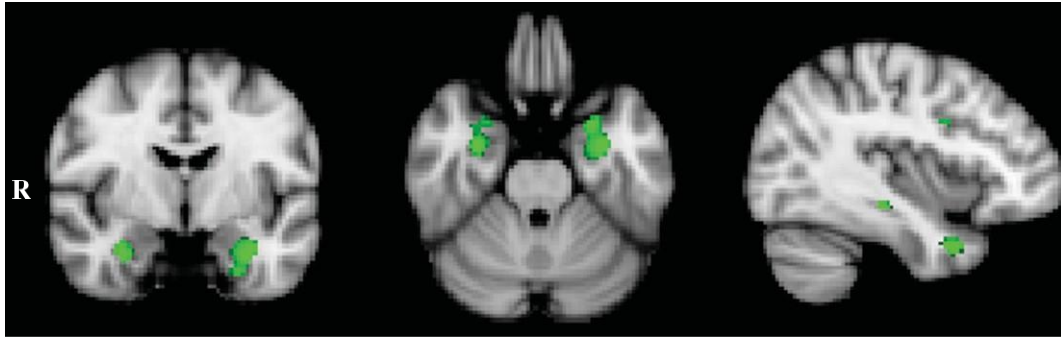


Fig. 3. VBM analysis showing brain regions in which gray matter intensity correlates with free recall performance in both Word and Picture version of the FCSRT (MNI coordinates $X = -38$; $Y = -6$; $Z = -26$). Colored voxel show regions that were significant in the analysis with $p < 0.05$ corrected for multiple comparisons (FWE). For all analysis, a cluster threshold of 100 contiguous voxels was used. Clusters are overlaid on the MNI standard brain.

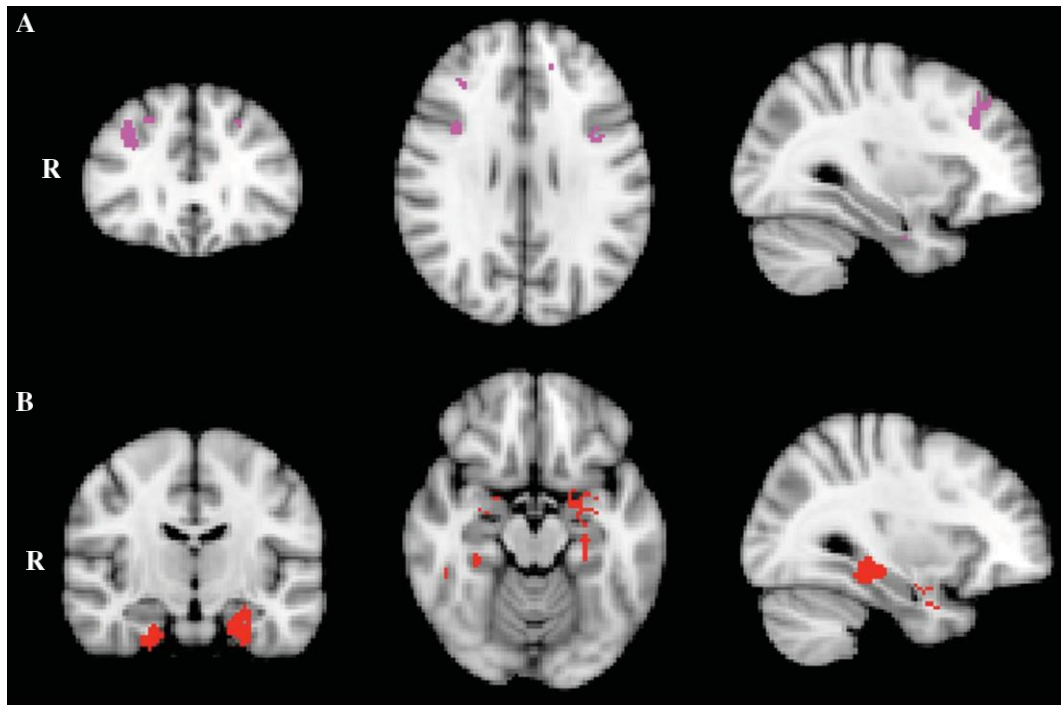


Fig. 4. VBM analysis showing exclusive brain areas in which gray matter intensity correlates significantly with free recall performance in AD in comparison with Controls, for (A) Word (MNI coordinates $X = 32$; $Y = 30$; $Z = 28$) and (B) Picture (MNI coordinates $X = 32$; $Y = -14$; $Z = -16$) versions of the FCSRT. Colored voxel in A and B show regions that were significant in the analysis with $p < 0.05$ corrected for multiple comparisons (FWE). For all analysis, a cluster threshold of 100 contiguous voxels was used. Clusters are overlaid on the MNI standard brain.

bilaterally with several brain structures, including mainly commonalities but also some differences between both versions.

Concerning the neuroanatomical comparison of the Word and Picture versions, performances on free recall were mainly correlated with two large clusters in the hippocampus and the temporal pole. For the Word version, there were additional smaller

clusters in the frontal cortex. For the Picture version, there were also two clusters in both parahippocampal regions and the right fusiform gyrus. Notably, we performed the VBM analysis using only one measure of memory performance, i.e., free recall, due to the fact that free and total recall measures are highly correlated due to total recall consisting of both free and cued recall. As our main goal was to compare the

Table 4

VBM results showing common regions of significant grey matter intensity decrease that correlate with free recall performance in AD combined with Controls, which overlap in Word and Picture versions of the FCSRT

Regions	Hemisphere	MNI coordinates			Number of voxels
		x	y	z	
Regions of overlap					
Temporal pole	Left	-38	6	-32	482
Hippocampus	Right	32	-6	-26	222
Hippocampus	Left	-22	-30	-8	113

All results corrected for multiple comparisons (FWE) at $p < 0.05$. Only cluster with at least 100 contiguous voxels included. MNI, Montreal Neurological Institute.

two-modality versions of the FCSRT, we constrained our analysis to the free recall scores only (however, results of the total recall can be found in the Supplementary Material). In general, our results replicate previous findings that free recall is a measure of encoding and storage processes that are dependent on the hippocampus [48]. The hippocampus has been reported as a critical region for episodic memory. Indeed, involvement of the hippocampus is a hallmark feature of AD and is considered to underlie the predominant amnesic syndrome [49]. Furthermore, previous studies reported correlation between scores of FCSRT free recall and atrophy in the left hippocampus and parahippocampus in AD and MCI subjects [19, 20, 22].

This finding is concordant with a recent study reporting that either the Rey Complex Figure delayed recall and the FCSRT delayed Recall, visual and a verbal episodic memory tests, are associated with total hippocampal volume in cognitively normal older adults [47]. Moreover, studies with visual tests show association with right hippocampus MCI subjects [20].

Picture free recall was also associated with a cluster in both the parahippocampus region and the right fusiform cortex. The involvement of the right

fusiform gyrus in our study could be explained by its role in the recognition of objects categories, such as animals, houses, and man-made tools [50]. The association of the Picture version with both parahippocampal regions is expected due to the visual characteristics of the test. This result is also in agreement with the evidence suggesting that both parahippocampal regions are involved in memory-related processing that involves associations between elements [51].

Finally, free recall on the Word version was also associated with one small cluster in the middle frontal gyrus. A similar result has been reported by Lekeu et al. in AD patients [17] and has been recently reported by Philippi et al. in patients with mild cognitive impairment using the Word version of the FCSRT [20]. It has been suggested that this association is related to the implication of search activity and strategic retrieval of the information during free recall [20]. The involvement of prefrontal regions in memory processing is well established, and patients with prefrontal lesions exhibit impaired performance in free recall in memory [52–54]. The lateral frontal pole has been implicated in working memory and episodic memory retrieval [55]. The association of episodic memory performance with frontal polar atrophy is concordant with previous studies in AD [42, 56]. Moreover, Irish et al. [56] reported, using another verbal memory task (RAVLT), an association between memory impairment and frontal lobe atrophy. Interestingly, two divergent patterns of prefrontal and medial frontal atrophy have been described in AD. Atrophy of the prefrontal cortex has been associated with poor memory performance only in AD patients with impairment in EF [42]. Concordant with this result, our AD subjects present a significant impairment in EF tests. The extent to which frontal pathology contributes to episodic memory dysfunction in AD needs to be explored further [56].

Table 5

VBM results showing exclusive regions of significant gray matter intensity decrease that correlate with free recall performance in AD combined with Controls, for the Word and Picture versions of the FCSRT

Regions	Hemisphere	MNI coordinates			Number of voxels
		x	y	z	
Word version					
Middle frontal gyrus	Right	32	30	28	167
Picture version					
Parahippocampal gyrus, anterior division	Left	-24	-12	-38	324
Temporal fusiform cortex, posterior division	Right	32	-36	-16	167
Parahippocampal gyrus, anterior division	Right	24	-14	-38	150

All results corrected for multiple comparisons (FWE) at $p < 0.05$. Only cluster with at least 100 contiguous voxels included. MNI, Montreal Neurological Institute.

Interestingly, the contrast analysis revealed that this association is exclusively for the Word version, suggesting that it could be material specific.

Also, free recall of both versions of the FCSRT was associated with a large cluster in the temporal pole. This cluster could be explained by semantic memory processing involved in the FCSRT [57]. Therefore, an involvement of these areas might explain poor performances on episodic memory tasks taking into account that episodic memory problems can be underpinned by impairment of semantic memory network.

The behavioral results showed higher performances on the Picture version than for the Word version in AD and controls, as previously reported [16]. Several factors could account for this result. First, the category of cue-items pairs differs between the Word and Picture version, i.e. the Picture version includes only concrete items whereas the Word version include more abstract cue-item pairs. A positive effect of word concreteness has been previously reported in episodic memory [58]. Additionally, according to the dual encoding theory of memory, pictures are remembered better than words because their representations in memory include both verbal and visual storage while words are encoded only verbally [59]. An alternate account for the picture superiority effect on memory performance is that pictures give rise to more distinct semantic representations than words [60]. The contrast imaging analysis revealed that the Picture version was associated with a broader network of regions involved in the recognition of object categories, which could facilitate memory for the Picture version, and brain regions involved in semantic memory.

Despite these interesting findings, some methodological issues warrant consideration in the current context. We cannot exclude that other atrophy in the temporal and frontal lobes is involved in these tests. We applied a conservative multiple comparison correction threshold as well as cluster extent thresholds of 100 contiguous voxels to reduce the number of false positives. Importantly, Monte Carlo simulations and experimental data demonstrate that cluster thresholding is an effective tool to reduce the probability of false positive findings without compromising the statistical power of the study [56, 61]. However, it will be important to replicate these findings in independent patient cohorts using similar correction methods. Finally, the diagnosis of AD was established on clinical grounds without any neuropathological confirmation for the diagnoses. Nevertheless, clinical pathological studies suggested

that NINCDS-ADRDA criteria are reliable for the diagnosis of AD [62]. Finally, even if most of AD patients included in our study are at the mild stage of AD, several subjects present with moderate AD and were severely impaired in the FCSRT, in line with previous studies with AD [19, 63, 64]. Indeed, a floor effect in some patients is also reported in previous studies and does not affect the VBM analysis.

In conclusion, our results suggest that both versions of the FCSRT are appropriate measures of episodic memory in AD. Performances on these tests are associated with dysfunction of a neural network with an established role in episodic memory impairment in early AD [65]. Our results suggest that free recall can be considered a hippocampal test. The Picture version of the FCSRT could have great utility to evaluate episodic memory impairment in a low-educated population or more severe patients. Finally, further insight on the neuroanatomical correlates of the FCSRT requires the study of other neurodegenerative diseases.

DISCLOSURE STATEMENT

Authors' disclosures available online (<http://j-alz.com/manuscript-disclosures/16-0973r2>).

SUPPLEMENTARY MATERIAL

The supplementary material is available in the electronic version of this article: <http://dx.doi.org/10.3233/JAD-160973>.

REFERENCES

- [1] Prince M, Wimo A, Guerchet M, Gemma-Claire A, Yu-Tzu W, Prina M (2015) *World Alzheimer Report 2015 The Global Impact of Dementia An analysis of prevalence, incidence, cost and trends*. Alzheimer's Disease International (ADI), London.
- [2] Alzheimer's, Association (2016) 2016 Alzheimer's disease facts and figures. *Alzheimers Dement* **12**, 459-509.
- [3] Dubois B, Feldman HH, Jacova C, Hampel H, Molinuevo JL, Blennow K, DeKosky ST, Gauthier S, Selkoe D, Bateman R, Cappa S, Crutch S, Engelborghs S, Frisoni GB, Fox NC, Galasko D, Habert MO, Jicha GA, Nordberg A, Pasquier F, Rabinovici G, Robert P, Rowe C, Salloway S, Sarazin M, Epelbaum S, de Souza LC, Vellas B, Visser PJ, Schneider L, Stern Y, Scheltens P, Cummings JL (2014) Advancing research diagnostic criteria for Alzheimer's disease: The IWG-2 criteria. *Lancet Neurol* **13**, 614-629.
- [4] McKhann GM, Knopman DS, Chertkow H, Hyman BT, Jack CR Jr, Kawas CH, Klunk WE, Koroshetz WJ, Manly JJ, Mayeux R, Mohs RC, Morris JC, Rossor MN, Scheltens P, Carrillo MC, Thies B, Weintraub S, Phelps CH (2011) The diagnosis of dementia due to Alzheimer's

- disease: Recommendations from the National Institute on Aging-Alzheimer's Association workgroups on diagnostic guidelines for Alzheimer's disease. *Alzheimers Dement* **7**, 263-269.
- [5] Braak H, Braak E (1991) Neuropathological staging of Alzheimer-related changes. *Acta Neuropathol* **82**, 239-259.
- [6] Nelson PT, Alafuzoff I, Bigio EH, Bouras C, Braak H, Cairns NJ, Castellani RJ, Crain BJ, Davies P, Del Tredici K, Duyckaerts C, Frosch MP, Haroutunian V, Hof PR, Hulette CM, Hyman BT, Iwatsubo T, Jellinger KA, Jicha GA, Kovari E, Kukull WA, Leverenz JB, Love S, Mackenzie IR, Mann DM, Masliah E, McKee AC, Montine TJ, Morris JC, Schneider JA, Sonnen JA, Thal DR, Trojanowski JQ, Troncoso JC, Wisniewski T, Woltjer RL, Beach TG (2012) Correlation of Alzheimer disease neuropathologic changes with cognitive status: A review of the literature. *J Neuropathol Exp Neurol* **71**, 362-381.
- [7] Sarazin M, Berr C, De Rotrou J, Fabrigoule C, Pasquier F, Legrain S, Michel B, Puel M, Volteau M, Touchon J, Verny M, Dubois B (2007) Amnesic syndrome of the medial temporal type identifies prodromal AD: A longitudinal study. *Neurology* **69**, 1859-1867.
- [8] Dubois B, Feldman HH, Jacova C, Dekosky ST, Barberger-Gateau P, Cummings J, Delacourte A, Galasko D, Gauthier S, Jicha G, Meguro K, O'Brien J, Pasquier F, Robert P, Rossor M, Salloway S, Stern Y, Visser PJ, Scheltens P (2007) Research criteria for the diagnosis of Alzheimer's disease: Revising the NINCDS-ADRDA criteria. *Lancet Neurol* **6**, 734-746.
- [9] Wagner M, Wolf S, Reischies FM, Daerr M, Wolfsgruber S, Jessen F, Popp J, Maier W, Hull M, Frolich L, Hampel H, Pernecky R, Peters O, Jahn H, Luckhaus C, Gertz HJ, Schroder J, Pantel J, Lewczuk P, Kornhuber J, Wiltfang J (2012) Biomarker validation of a cued recall memory deficit in prodromal Alzheimer disease. *Neurology* **78**, 379-386.
- [10] Grober E, Buschke H, Bang S, Dresner R (1988) Screening for dementia by memory testing. *Neurology* **38**, 900-903.
- [11] Petersen RC, Smith GE, Ivnik RJ, Kokmen E, Tangalos EG (1994) Memory function in very early Alzheimer's disease. *Neurology* **44**, 867-872.
- [12] Auriacombe S, Helmer C, Amieva H, Berr C, Dubois B, Dartigues JF (2010) Validity of the free and cued selective reminding test in predicting dementia: The 3C study. *Neurology* **74**, 1760-1767.
- [13] Grober E, Lipton RB, Hall C, Crystal H (2000) Memory impairment on free and cued selective reminding predicts dementia. *Neurology* **54**, 827-832.
- [14] Grober E, Hall CB, Lipton RB, Zonderman AB, Resnick SM, Kawas C (2008) Memory impairment, executive dysfunction, and intellectual decline in preclinical Alzheimer's disease. *J Int Neuropsychol Soc* **14**, 266-278.
- [15] Pillon B, Deweer B, Agid Y, Dubois B (1993) Explicit memory in Alzheimer's, Huntington's, and Parkinson's diseases. *Arch Neurol* **50**, 374-379.
- [16] Delgado C, Muñoz-Neira C, Soto A, Martínez M, Henríquez F, Flores P, Slachevsky A (2016) Comparison of the psychometric properties of the "Word" and "Picture" versions of the Free and Cued Selective Reminding Test in a Spanish-speaking cohort of patients with mild Alzheimer's disease and cognitively healthy controls. *Arch Clin Neuropsychol* **31**, 165-175.
- [17] Lekeu F, Van der Linden M, Chicherio C, Collette F, Deguelde C, Franck G, Moonen G, Salmon E (2003) Brain correlates of performance in a free/cued recall task with semantic encoding in Alzheimer disease. *Alzheimer Dis Assoc Disord* **17**, 35-45.
- [18] Deweer B, Lehericy S, Pillon B, Baulac M, Chiras J, Marsault C, Agid Y, Dubois B (1995) Memory disorders in probable Alzheimer's disease: The role of hippocampal atrophy as shown with MRI. *J Neurol Neurosurg Psychiatry* **58**, 590-597.
- [19] Sarazin M, Chauvire V, Gardin E, Colliot O, Kingingehun S, de Souza LC, Hugonot-Diener L, Garnero L, Lehericy S, Chupin M, Dubois B (2010) The amnesic syndrome of hippocampal type in Alzheimer's disease: An MRI study. *J Alzheimers Dis* **22**, 285-294.
- [20] Philippi N, Noblet V, Duron E, Cretin B, Bouilly C, Wisniewski I, Seux ML, Martin-Hunyadi C, Chaussade E, Demuynck C, Kremer S, Lehericy S, Gounot D, Armspach JP, Hanon O, Blanc F (2016) Exploring anterograde memory: A volumetric MRI study in patients with mild cognitive impairment. *Alzheimers Res Ther* **8**, 26.
- [21] de Toledo-Morrell L, Dickerson B, Sullivan MP, Spanovic C, Wilson R, Bennett DA (2000) Hemispheric differences in hippocampal volume predict verbal and spatial memory performance in patients with Alzheimer's disease. *Hippocampus* **10**, 136-142.
- [22] Ezzati A, Katz MJ, Zammit AR, Lipton ML, Zimmerman ME, Sliwinski MJ, Lipton RB (2016) Differential association of left and right hippocampal volumes with verbal episodic and spatial memory in older adults. *Neuropsychologia* **93**, 380-385.
- [23] Ally BA (2012) Using pictures and words to understand recognition memory deterioration in amnesic mild cognitive impairment and Alzheimer's disease: A review. *Curr Neurol Neurosci Rep* **12**, 687-694.
- [24] McKhann GM, Knopman DS, Chertkow H, Hyman BT, Jack CR Jr, Kawas CH, Klunk WE, Koroshetz WJ, Manly JJ, Mayeux R, Mohs RC, Morris JC, Rossor MN, Scheltens P, Carrillo MC, Thies B, Weintraub S, Phelps CH (2011) The diagnosis of dementia due to Alzheimer's disease: Recommendations from the National Institute on Aging-Alzheimer's Association workgroups on diagnostic guidelines for Alzheimer's disease. *Alzheimers Dement* **7**, 263-269.
- [25] Morris JC (1993) The Clinical Dementia Rating (CDR): Current version and scoring rules. *Neurology* **43**, 2412-2414.
- [26] Muñoz-Neira C, Henríquez Chaparro F, Sánchez Cea M, Ihnen J, Flores P, Slachevsky A (2012) Propiedades psicométricas y utilidad diagnóstica del Addenbrooke's Cognitive Examination - Revised (ACE-R) en una muestra de ancianos chilenos. *Rev Med Chile* **140**, 1006-1013.
- [27] Folstein MF, Folstein SE, McHugh PR (1975) "Minimal state": A practical method for grading the cognitive state of patients for the clinician. *J Psychiatr Res* **12**, 189-198.
- [28] Nasreddine ZS, Phillips NA, Bedirian V, Charbonneau S, Whitehead V, Collin I, Cummings JL, Chertkow H (2005) The Montreal Cognitive Assessment, MoCA: A brief screening tool for mild cognitive impairment. *J Am Geriatr Soc* **53**, 695-699.
- [29] Rey A (1959) *Test de copie d'une figure complexe*, Centre de Psychologie Appliquée, Paris.
- [30] Dubois B, Slachevsky A, Litvan I, Pillon B (2000) The FAB: A Frontal Assessment Battery at bedside. *Neurology* **55**, 1621-1626.
- [31] Nelson HE (1976) A modified card sorting test sensitive to frontal lobe defects. *Cortex* **12**, 313-324.

- [32] Reitan R (1958) Validity of the Trail Making Test as an indication of organic brain damage. *Percept Mot Skills* **8**, 271-276.
- [33] Grober E, Buschke H (1987) Genuine memory deficit in dementia. *Dev Neuropsychol* **3**, 13-36.
- [34] Cohen JD (1988) *Statistical Power Analysis for the Behavioral Sciences*. Mahwah, NJ.
- [35] Ashburner J, Friston KJ (2000) Voxel-based morphometry—the methods. *Neuroimage* **11**, 805-821.
- [36] Good CD, Johnsrude IS, Ashburner J, Henson RN, Friston KJ, Frackowiak RS (2001) A voxel-based morphometric study of ageing in 465 normal adult human brains. *Neuroimage* **14**, 21-36.
- [37] Smith SM, Jenkinson M, Woolrich MW, Beckmann CF, Behrens TE, Johansen-Berg H, Bannister PR, De Luca M, Drobnjak I, Flitney DE, Niazy RK, Saunders J, Vickers J, Zhang Y, De Stefano N, Brady JM, Matthews PM (2004) Advances in functional and structural MR image analysis and implementation as FSL. *Neuroimage* **23**(Suppl 1), S208-S219.
- [38] Zhang Y, Brady M, Smith S (2001) Segmentation of brain MR images through a hidden Markov random field model and the expectation-maximization algorithm. *IEEE Trans Med Imaging* **20**, 45-57.
- [39] Andersson JLR, Jenkinson M, Smith S (2007) Non-linear optimisation. FMRIB technical report. *FMRIB Analysis Group Technical Reports*, FMRIB technical report TR07JA1.
- [40] Andersson JLR, Jenkinson M, Smith S (2007) Non-linear registration, aka Spatial normalisation. *FMRIB Analysis Group Technical Reports*, FMRIB technical report TR07JA2.
- [41] Rueckert D, Sonoda LI, Hayes C, Hill DLG, Leach MO, Hawkes DJ (1999) Non-rigid registration using free-form deformations: Application to breast MR images. *IEEE Trans Med Imaging* **18**, 712-721.
- [42] Wong S, Bertoux M, Savage G, Hodges JR, Piguet O, Hornberger M (2016) Comparison of prefrontal atrophy and episodic memory performance in dysexecutive Alzheimer's disease and behavioral-variant frontotemporal dementia. *J Alzheimers Dis* **51**, 889-903.
- [43] Pennington C, Hodges JR, Hornberger M (2011) Neural correlates of episodic memory in behavioral variant frontotemporal dementia. *J Alzheimers Dis* **24**, 261-268.
- [44] Fillmore PT, Phillips-Meek MC, Richards JE (2015) Age-specific MRI brain and head templates for healthy adults from 20 through 89 years of age. *Front Aging Neurosci* **7**, 44.
- [45] Nichols TE, Holmes AP (2002) Nonparametric permutation tests for functional neuroimaging: A primer with examples. *Hum Brain Mapp* **15**, 1-25.
- [46] Smith SM, Nichols TE (2009) Threshold-free cluster enhancement: Addressing problems of smoothing, threshold dependence and localisation in cluster inference. *Neuroimage* **44**, 83-98.
- [47] Zammit AR, Ezzati A, Zimmerman ME, Lipton RB, Lipton ML, Katz MJ (2017) Roles of hippocampal subfields in verbal and visual episodic memory. *Behav Brain Res* **317**, 157-162.
- [48] Bertoux M, de Souza LC, Corlier F, Lamari F, Bottlaender M, Dubois B, Sarazin M (2014) Two distinct amnesic profiles in behavioral variant frontotemporal dementia. *Biol Psychiatry* **75**, 582-588.
- [49] Di Paola M, Macaluso E, Carlesimo GA, Tomaiuolo F, Worsley KJ, Fadda L, Caltagirone C (2007) Episodic memory impairment in patients with Alzheimer's disease is correlated with entorhinal cortex atrophy. A voxel-based morphometry study. *J Neurol* **254**, 774-781.
- [50] Fedurco M (2012) Long-term memory search across the visual brain. *Neural Plast* **2012**, 392695.
- [51] Aminoff EM, Kveraga K, Bar M (2013) The role of the parahippocampal cortex in cognition. *Trends Cogn Sci* **17**, 379-390.
- [52] Blumenfeld RS, Ranganath C (2007) Prefrontal cortex and long-term memory encoding: An integrative review of findings from neuropsychology and neuroimaging. *Neuroscientist* **13**, 280-291.
- [53] Simons JS, Spiers HJ (2003) Prefrontal and medial temporal lobe interactions in long-term memory. *Nat Rev Neurosci* **4**, 637-648.
- [54] Wheeler MA, Stuss DT, Tulving E (1995) Frontal lobe damage produces episodic memory impairment. *J Int Neuropsychol Soc* **1**, 525-536.
- [55] Gilbert SJ, Spengler S, Simons JS, Steele JD, Lawrie SM, Frith CD, Burgess PW (2006) Functional specialization within rostral prefrontal cortex (area 10): A meta-analysis. *J Cogn Neurosci* **18**, 932-948.
- [56] Irish M, Piguet O, Hodges JR, Hornberger M (2014) Common and unique gray matter correlates of episodic memory dysfunction in frontotemporal dementia and Alzheimer's disease. *Hum Brain Mapp* **35**, 1422-1435.
- [57] Patterson K, Nestor PJ, Rogers TT (2007) Where do you know what you know? The representation of semantic knowledge in the human brain. *Nat Rev Neurosci* **8**, 976-987.
- [58] Fliessbach K, Weis S, Klaver P, Elger CE, Weber B (2006) The effect of word concreteness on recognition memory. *Neuroimage* **32**, 1413-1421.
- [59] Grober E, Sanders AE, Hall C, Lipton RB (2010) Free and cued selective reminding identifies very mild dementia in primary care. *Alzheimer Dis Assoc Disord* **24**, 284-290.
- [60] Konkle T, Brady TF, Alvarez GA, Oliva A (2010) Conceptual distinctiveness supports detailed visual long-term memory for real-world objects. *J Exp Psychol Gen* **139**, 558-578.
- [61] Forman SD, Cohen JD, Fitzgerald M, Eddy WF, Mintun MA, Noll DC (1995) Improved assessment of significant activation in functional magnetic resonance imaging (fMRI): Use of a cluster-size threshold. *Magn Reson Med* **33**, 636-647.
- [62] Knopman DS, DeKosky ST, Cummings JL, Chui H, Corey-Bloom J, Relkin N, Small GW, Miller B, Stevens JC (2001) Practice parameter: Diagnosis of dementia (an evidence-based review). Report of the Quality Standards Subcommittee of the American Academy of Neurology. *Neurology* **56**, 1143-1153.
- [63] Traykov L, Baudic S, Raoux N, Latour F, Rieu D, Smaghe A, Rigaud AS (2005) Patterns of memory impairment and perseverative behavior discriminate early Alzheimer's disease from subcortical vascular dementia. *J Neurol Sci* **229-230**, 75-79.
- [64] Baudic S, Barba GD, Thibaudet MC, Smaghe A, Remy P, Traykov L (2006) Executive function deficits in early Alzheimer's disease and their relations with episodic memory. *Arch Clin Neuropsychol* **21**, 15-21.
- [65] Aggleton JP, Pralus A, Nelson AJ, Hornberger M (2016) Thalamic pathology and memory loss in early Alzheimer's disease: Moving the focus from the medial temporal lobe to Papez circuit. *Brain* **139**(Pt 7), 1877-1890.