

by Boyd and Rapini,¹ 40 000 skin biopsies were analyzed and 69 collision tumors were found, 14 of which involved a nevus and a seborrheic keratosis.

In case of doubt, confocal microscopy, a noninvasive imaging technique, helps to improve the evaluation of melanocytic lesions, as it permits in vivo evaluation of microscopic structures.³ Moscarella et al.² described 24 cases of collision tumors and reported an excellent correlation between the histologic images and those obtained on confocal microscopy.

Conflicts of Interest

The authors declare that they have no conflicts of interest.

References

1. Boyd AS, Rapini RP. Cutaneous collision tumors. An analysis of 69 cases and review of the literature. *Am J Dermatopathol.* 1994;16:253–7.

2. Moscarella E, Rabinovitz H, Oliviero MC, Brown L, Longo C, Zalaudek I, et al. The role of reflectance confocal microscopy as an aid in the diagnosis of collision tumors. *Dermatology.* 2013;227:109–17.
3. Salerni G, Lovatto L, Carrera C, Palou J, Alos L, Puig-Butlle JA, et al. Correlation among dermoscopy, confocal reflectance microscopy, and histologic features of melanoma and basal cell carcinoma collision tumor. *Dermatol Surg.* 2011;37:275–9.

L. Ascanio Armada,^{a,*} R. Gamo Villegas,^a
A. Pampin Franco,^a F. Pinedo Moraleda^b

^a Servicio de Dermatología, Hospital Universitario Fundación Alcorcón, Alcorcón, Madrid, Spain

^b Servicio de Anatomía Patológica, Hospital Universitario Fundación Alcorcón, Alcorcón, Madrid, Spain

* Corresponding author.

E-mail addresses: luciaascanioarmada@gmail.com,
mlascanio@fhacorcon.es (L. Ascanio Armada).

31 May 2015 7 December 2015

Unusual Ultrasound Appearance of Subungual Keratoacanthoma With Clinical and Histological Correlation[☆]



Presentación ecográfica no habitual de queratoacantoma subungueal con correlación clínica e histológica

To the Editor:

Keratoacanthomas (KA) form a group of tumors of epidermal origin but whose nature remains controversial. They are thought to be low-grade squamous cell carcinomas (SCC) that may become more aggressive in immunocompromised individuals. KAs are characterized by a rapid, exophytic growth, usually followed by spontaneous regression, and they typically occur in sun-exposed areas in elderly patients.¹

The subungual or periungual variant of KA is rare; it is usually locally destructive and is less likely to undergo spontaneous involution. This variant is more common in white male patients and in the fifth decade of life. The cause is still unknown, but associations have been reported with trauma, carcinogen exposure, eczema, psoriasis, atopic dermatitis, xeroderma pigmentosum, and incontinentia pigmenti.²

Case Description

We present the case of a 45-year-old woman with a history of incontinentia pigmenti. She consulted for a 1-month

history of a painful, rapidly growing swelling in the periungual region of the right thumb.

Physical examination revealed a skin-colored nodular lesion that occupied the ulnar and proximal borders of the nail of the first digit of the right hand (Fig. 1).

Color Doppler ultrasound was requested. The report described a solid, hypoechoic tumor with a center of lower echogenicity and of solid appearance, located at the ulnar border of the periungual region and extending into the nail bed on the same side; the ultrasound appearance was not suggestive of malignancy. The lesion measured 11 mm (transverse) × 10.7 mm (longitudinal) × 8.3 mm (depth). Vascularization was predominantly peripheral, in the form of narrow vessels with low-velocity arterial flow, and there was remodeling of the surface of the underlying distal phalanx. In addition, signs of inflammatory (hypervascularity) were

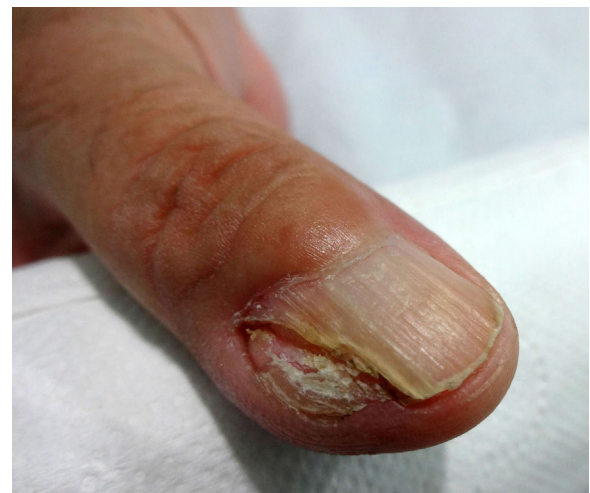

Figure 1 Clinical photograph of the keratoacanthoma. The nodular, skin-colored lesion affected the proximal and ulnar borders of the nail and periungual region of the right thumb.

[☆] Please cite this article as: Le-Bert M, Soto D, Vial V, Bentjerodt R, Wortsman X. Presentación ecográfica no habitual de queratoacantoma subungueal con correlación clínica e histológica. *Actas Dermosifiliogr.* 2016;107:442–444.

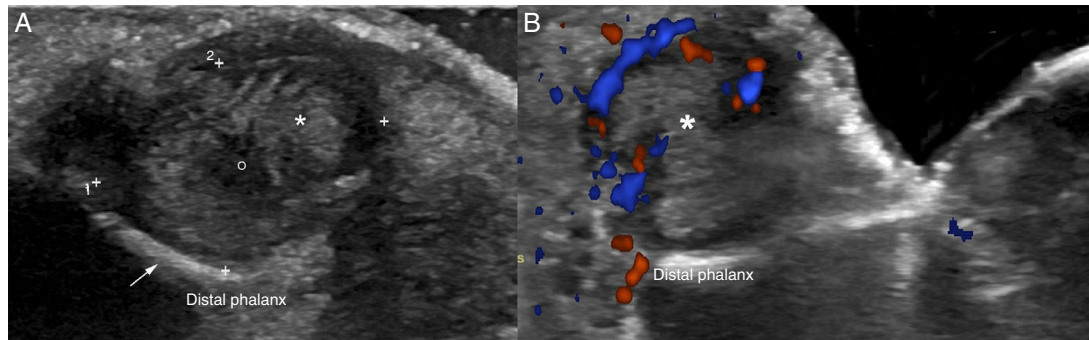


Figure 2 Nail ultrasound in keratoacanthoma. A, Gray scale (longitudinal axis, right thumb, ulnar border) shows a hypoechoic tumor (asterisk, between + signs) with lower echogenicity centrally (o). Observe remodeling of the underlying bone surface (arrow). B, Color Doppler of the nail (longitudinal axis, right thumb, ulnar border) showing hypervascularity (in color) at the periphery of the tumor (asterisk).

observed in the nail bed, and the nail plate showed changes probably of secondary dystrophic origin (Fig. 2).

The lesion was excised and histology revealed a well-differentiated, cobblestoned crateriform tumor with numerous scattered dyskeratotic cells, intralesional microabscesses, and mixed peripheral inflammation, compatible with periungual KA (Fig. 3).

The histology report was drafted in accordance with the medical principles of the Declaration of Helsinki, and the patient gave her consent for publication.

Discussion

This case demonstrates the usefulness of ultrasound in the diagnosis of ungual pathology, and also draws attention to the clinical signs that can lead us to suspect the presence of a tumor in the region of the nail.

Color Doppler ultrasound typically reveals a lesion with a heterogeneous ultrasound structure, with a hypoechoic border of solid appearance and an anechoic center of fluid appearance. Remodeling of the surface of the underlying bone is common.³⁻⁵

Our case presented an unusual ultrasound appearance, as the lesion was hypoechoic and had a central area of lower echogenicity, but not the anechoic fluid component typically reported.

The central region of the tumor corresponds to the keratin-filled central crater²⁻⁴; in our case, the ultrasound finding would appear to be due to a more compact central keratin mass. Ultrasound also enabled us to confirm the neoplastic nature of the lesion and to establish the differential diagnosis with other types of tumors of the nail region that present distinct ultrasound patterns, such as glomus tumor and onychomatixoma.^{6,7}

Glomus tumor usually presents as a solid, moderately well-defined, hypoechoic nodular lesion that provokes remodeling of the surface of the distal phalanx. The majority of glomus tumors have internal vascularization and are situated in the proximal nail bed.^{5,6}

Onychomatixoma has a hypoechoic appearance with hyperechoic lines or foci that affect the nail matrix and extend into the interplate space. These tumors usually have a reduced vascularity and do not tend to produce erosion or remodeling of the underlying bone surface.⁵⁻⁷

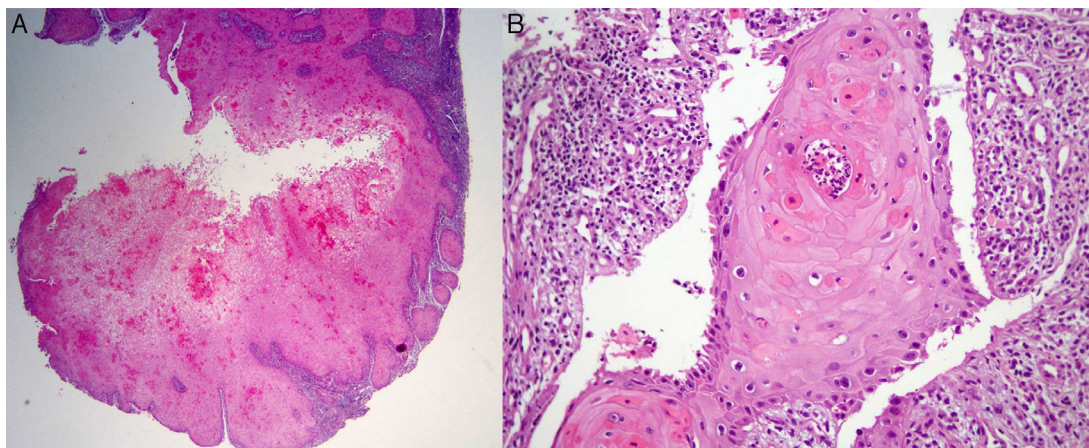


Figure 3 Histology of keratoacanthoma. A, Well-differentiated, cobblestoned crateriform neoplasm. The numerous and clearly visible scattered dyskeratotic cells are a key to diagnosis. Hematoxylin-eosin (H&E), original magnification $\times 2$. B, Tumor foci with mild nuclear atypia, scattered dyskeratotic cells, intratumoral microabscesses, and peripheral inflammation. H&E, original magnification $\times 10$.

On ultrasound, SCC is less well defined and, rather than an anechoic or hypoechoic center, it has a heterogeneous, hypoechoic echostructure, with erosion of the nail plate and a variable degree of vascularity.⁵ In contrast to SCC, plain x-rays of a bone defect caused by a KA typically show well-defined borders, as KAs do not show intensely invasive behavior.³

Other imaging studies to evaluate bone involvement, apart from ultrasound, include computed tomography and magnetic resonance imaging. However, color Doppler ultrasound has been described as the method of choice as it provides the most sensitive images for the diagnosis of ungual and periungual tumors. Computed tomography and magnetic resonance imaging usually present false negatives in tumors measuring less than 3 mm and poor definition of the ungual and periungual planes.⁶

In conclusion, when an ungual tumor is suspected, the clinical findings should be correlated with the ultrasound findings, and this should be completed by adequate histological analysis. Although the ultrasound findings were unusual in our case, color Doppler ultrasound enabled the diagnosis of a periungual tumor to be confirmed. This can favor early diagnosis and aid surgical planning.

Conflicts of Interest

The authors declare that they have no conflicts of interest.

References

1. Takai T, Misago N, Murata Y. Natural course of keratoacanthoma and related lesions after partial biopsy: Clinical analysis of 66 lesions. *J Dermatol.* 2015;42:353–62.
2. Baran R, Goettmann S. Distal digital keratoacanthoma: A report of 12 cases and a review of the literature. *Br J Dermatol.* 1998;139:512–5.

3. Choi JH, Shin DH, Shin DS, Cho KH. Subungual keratoacanthoma: Ultrasound and magnetic resonance imaging findings. *Skeletal Radiol.* 2007;36:769–72.
4. Thomas L, Vaudaine M, Wortsman X, Jemec GBE, Drape JL. Imaging the nail unit. In: Baran R, de Berker D, Holzberg M, Thomas L, editors. *Baran & Dawber's Diseases of the nails and their management.* 4th edition West Sussex: Wiley; 2012. p. 132–53.
5. Wortsman X. Sonography of the nail. In: Wortsman X, Jemec GBE, editors. *Dermatologic ultrasound with clinical and histologic correlations.* 1st edition NY: Springer; 2013. p. 419–76.
6. Wortsman X, Wortsman J, Soto R, Saavedra T, Honeyman J, Sazunic I, et al. Benign tumors and pseudotumors of the nail: A novel application of sonography. *J Ultrasound Med.* 2010;29:803–16.
7. Soto R, Wortsman X, Corredoira Y. Onychomatricoma: Clinical and sonographic findings. *Arch Dermatol.* 2009;145:1461–2.

M. Le-Bert,^a D. Soto,^b V. Vial,^c R. Bentjerodt,^d
X. Wortsman^{e,*}

^a *Departamento de Dermatología, Centro de Referencia de Salud Peñalolén Cordillera Oriente, Peñalolén, Santiago, Chile*

^b *Escuela de Medicina, Universidad de los Andes, Santiago, Chile*

^c *Departamento de Medicina, Facultad de Medicina, Universidad de los Andes, Santiago, Chile*

^d *Departamento de Patología, Citolab, Santiago, Chile*

^e *Departamento de Radiología y Departamento de Dermatología, Instituto de Investigación y Diagnóstico por Imágenes en Piel y Tejidos Blandos, Clínica Servet, Facultad de Medicina, Universidad de Chile, Santiago, Chile*

* Corresponding author.

E-mail address: sworts@yahoo.com (X. Wortsman).

Cutaneous Collagenous Vasculopathy: A Case Report and Review of the Literature[☆]



Vasculopatía colágena cutánea. Aportación de un caso y revisión de la literatura

To the Editor:

Cutaneous collagenous vasculopathy (CCV) is an idiopathic microangiopathy affecting blood vessels of the superficial dermal vascular plexus.^{1,2} It is a rare condition characterized by the appearance of multiple cutaneous telangiectasias with a variable distribution on the trunk and limbs, but it does not affect the mucosas or nail bed and has not been

associated with systemic repercussions in the cases reported in the literature.^{3–5} CCV shows marked clinical similarities with generalized essential telangiectasia, which is the main clinical differential diagnosis to be considered.^{1,4} Since its first description in the year 2000 by Salama and Rosenthal¹ and up to the year 2015, we have found reports of 28 new cases of CCV (Table 1). We present a patient recently diagnosed with CCV in our department.

The patient was a 74-year-old man with a past history of adenoma of the prostate. He was on no long-term treatment. He was seen in our department for evaluation of reddish skin lesions that had developed progressively over the previous 3 years. The telangiectasias had first appeared on the lower limbs and, over the course of a few years, had spread to the abdomen and to the forearms. The patient reported occasional pruritus. There was no personal or family history of widespread cutaneous telangiectasias or of mucosal bleeding. Physical examination revealed erythematous plaques formed of multiple telangiectatic vessels; the plaques were distributed symmetrically over the forearms (Fig. 1A), lower abdomen, thighs (Fig. 1B), and lower legs (Fig. 1C). There were no mucosal or nail bed alterations.

[☆] Please cite this article as: Castiñeiras-Mato I, Rodríguez-Lojo R, Fernández-Díaz ML, Bal-Nieves F. Cutaneous Collagenous Vasculopathy: A Case Report and Review of the Literature. *Actas Dermosifiliogr.* 2016;107:444–447.