



ACTAS Derma-Sifiliográficas

Full English text available at
www.actasdermo.org



CASE AND RESEARCH LETTERS

Sarcoidal Necrobiosis Lipoidica in a Nondiabetic Patient: Usefulness of Skin Ultrasound[☆]



Necrobiosis lipóidica sarcoidea en paciente no diabético. Utilidad de la ecografía cutánea

To the Editor:

Necrobiosis lipoidica is a granulomatous disease of unknown origin that typically gives rise to multiple lesions on the anterior aspect of both lower legs. The histopathologic abnormalities are mainly observed in the mid and deep dermis. The alterations tend to extend into the subcutaneous cellular tissue along the adipose tissue septa, giving rise to a predominantly septal panniculitis.^{1,2}

High-frequency skin ultrasound has been shown to be a useful additional test for the diagnosis and differentiation of inflammatory diseases that affect the dermis and subcutaneous cellular tissue.³

Case Description

Our patient was a 40-year-old woman with a history of systemic lupus erythematosus, with lupus nephritis diagnosed in 1997 (currently asymptomatic and not on treatment) and nonspecific colitis diagnosed in 2010 (on treatment with sulfasalazine). She was seen for asymptomatic lesions on the lower legs. The alterations had started 2 years earlier as a single lesion on the anterior aspect of left lower leg and had later affected the right lower limb. Dermoscopic study of 1 of the lesions (FotoFinder Medicam 800HD, FotoFinder Systems GmbH, Bad Birnbach, Germany) revealed a dense network of branching anastomosing vessels on a yellow-orange background (Fig. 1).

Ultrasound was performed using the LOGIQ E9 XDclear device (General Electric Health Systems, Milwaukee, United States) with 2 linear transducers with maximum frequencies of 15 and 18 MHz. Hypochoic areas were observed in the mid and deep dermis, with evidence of increased blood flow

on color power Doppler. Compared with healthy perilesional skin, the dermohypodermal interface was blurred as a result of a diffuse increase in echogenicity of the subcutaneous cellular tissue (Fig. 2A). At greater depth, vertical hypochoic bands were seen to penetrate deeply into the fat (Fig. 2B).

Histopathology revealed areas of degenerated collagen surrounded by palisaded histiocytes and a lymphocytic and plasma-cell infiltrate that mainly affected the mid and deep dermis (Fig. 3A). The inflammatory changes extended into the subcutaneous cellular tissue, with foci of degenerated collagen surrounded by histiocytes in the connective tissue septa of the hypodermis, forming granulomas of vaguely sarcoid appearance (Fig. 3B).

A diagnosis of sarcoidal necrobiosis lipoidica was made and blood tests were requested, including measurement of blood glucose, thyroid hormones, and antithyroid antibodies, which were normal or negative. Treatment was started with topical corticosteroids.

Discussion

This case illustrates the usefulness of high-frequency ultrasound to guide the diagnosis in suspected necrobiosis lipoidica. The technique enables us to locate foci of inflammation in the mid and deep dermis, and to demonstrate the presence of panniculitis with edema and thickening of the septa in the subcutaneous cellular tissue. Dermal inflammation is seen as hypochoic areas that usually have increased blood flow on color Doppler or power Doppler (slow flow). The inflammatory findings in the subcutaneous cellular tissue vary depending on whether involvement is predominantly lobular, septal, or mixed. Lobular involvement produces a diffuse increase in echogenicity of the adipose tissue; septal involvement produces a typically hypochoic noncompressible thickening of the septa, seen as hypochoic perilobular bands. In mixed panniculitis, the 2 patterns coexist.³ In our patient, we also observed the characteristic loss of sharpness of the dermohypodermal junction, which we believe to be due to the simultaneous inflammatory involvement of the deep reticular dermis and the hypodermis.

Dermoscopy in our patient was characteristic. The lesions presented hairpin vessels on a yellowish-orange background with whitish areas. Branching vascular structures are formed of anastomosing vessels of a similar size. The presence of comma vessels has also been described as an early manifestation of the disease.⁴ A pigmented

[☆] Please cite this article as: García-Gavín J, Comba Pérez-Pérez L, Requena L, Wortsman X. Necrobiosis lipóidica sarcoidea en paciente no diabético. Utilidad de la ecografía cutánea. Actas Dermosifiliogr. 2016;107:525–527.

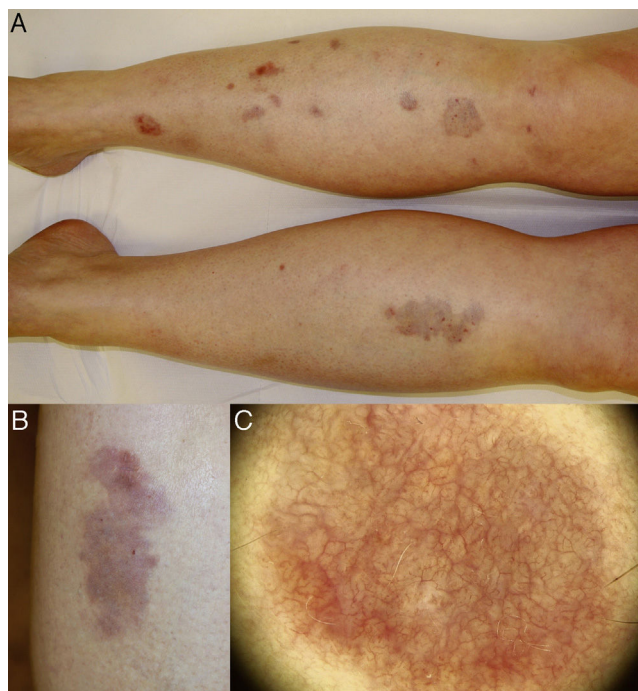


Figure 1 A, Well-defined, round and oval plaques affecting the anterior aspect of both lower legs. B, Detail of an isolated erythematous lesion, with orange, yellowish, brownish, and whitish areas; superficial atrophy and numerous telangiectasias can be observed. C, Dermoscopic image showing a dense network of branching anastomosing vessels on a yellow-orange background with whitish areas.

pseudonetwork and a brown-colored background due to melanocyte stimulation are sometimes observed.⁵

The case presented occurred in a nondiabetic patient with a diagnosis of systemic lupus erythematosus and non-specific colitis. The association of necrobiosis lipoidica and diabetes mellitus is well known, but the proportion of patients who present both diseases varies between the different studies (11% to 65%).⁶⁻⁸ Necrobiosis lipoidica has also been reported in healthy individuals and in patients with other autoimmune and inflammatory diseases, including inflammatory bowel disease.⁸

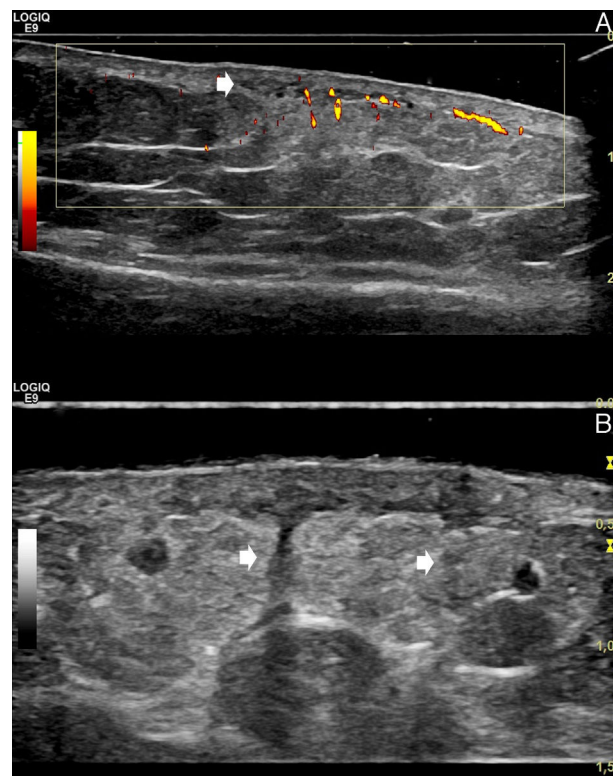


Figure 2 A, Power Doppler ultrasound (linear 15 MHz transducer; longitudinal axis, left leg): hypoechoic areas in the mid and deep dermis (arrow), with blurring of the dermohypodermal junction and a diffusely increased echogenicity of the underlying superficial hypodermal adipose tissue. Power Doppler shows increased dermal and superficial hypodermal flow. The image allows us to compare the affected area (right side of the image) with healthy perilesional skin (left side of the image). B, Gray-scale ultrasound (linear 18 MHz transducer; longitudinal axis, left leg). The hypoechoic vertical bands correspond to thickened septa (arrows).

Finally, the finding on histopathology of sarcoid granulomas in the dermis and in the adipose tissue septa was interesting. These structures, formed of groups of giant and

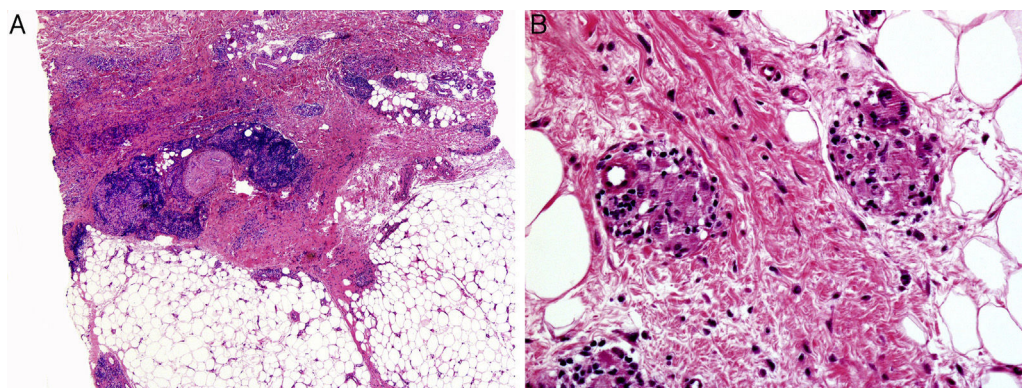


Figure 3 A, Predominant involvement of the mid and deep dermis, with areas of degenerated collagen surrounded by palisaded histiocytes and a lymphocytic and plasma-cell infiltrate. B, The inflammatory changes extend into the subcutaneous cellular tissue, with foci of degenerated collagen surrounded by histiocytes in the connective tissue septa, forming granulomas of vaguely sarcoid appearance.

epithelioid cells in areas of degenerated collagen, are an uncommon feature that defines what has been called the sarcoid variant of necrobiosis lipoidica.^{9,10}

Conflicts of Interest

The authors declare that they have no conflicts of interest.

References

1. Reid SD, Ladizinski B, Lee K, Baibergenova A, Alavi A. Update on necrobiosis lipoidica: A review of etiology, diagnosis, and treatment options. *J Am Acad Dermatol.* 2013;69:783–91.
2. Requena L. Normal subcutaneous fat, necrosis of adipocytes and classification of the panniculitides. *Semin Cutan Med Surg.* 2007;26:66–70.
3. Worstman X, Carreño L, Morales C. Inflammatory diseases of the skin. In: Wortsman X, Jemec GBE, editors. *Dermatologic ultrasound with clinical and histologic correlations.* New York: Springer; 2013. p. 73–118.
4. Pellicano R, Caldarola G, Filabozzi P, Zalaudek I. Dermoscopy of necrobiosis lipoidica and granuloma annulare. *Dermatology.* 2013;226:319–23.
5. Conde-Montero E, Avilés-Izquierdo JA, Mendoza-Cembranos MD, Parra-Blanco V. Dermatoscopia de la necrobiosis lipoidica. *Actas Dermosifiliogr.* 2013;104:534–7.
6. O'Toole EA, Kennedy U, Nolan JJ, Young MM, Rogers S, Barnes L. Necrobiosis lipoidica: Only a minority of patients have diabetes mellitus. *Br J Dermatol.* 1999;140:283–6.
7. Erfurt-Berge C, Seitz AT, Rehse C, Wollina U, Schwede K, Renner R. Update on clinical and laboratory features in necrobiosis lipoidica: A retrospective multicentre study of 52 patients. *Eur J Dermatol.* 2012;22:770–5.
8. Marcoval J, Gómez-Armayones S, Valentí-Medina F, Bonfill-Ortí M, Martínez-Molina L. Necrobiosis lipoidica. Estudio descriptivo de 35 pacientes. *Actas Dermosifiliogr.* 2015;106:402–7.
9. Yen P-S, Wang K-H, Chen W-Y, Yang Y-W, Ho W-T. The many faces of necrobiosis lipoidica: A report of three cases with histologic variations. *Dermatologica Sinica.* 2011;29:67–71.
10. Requena L. Necrobiosis lipoidica. In: Herrera Ceballos E, Moreno Carazo A, Requena Caballero L, Rodríguez Peralto JL, editors. *Dermatopatología: Correlación Clínica Patológica.* Barcelona: Signamet Edicions, S.A.; 2007. p. 401–4.

J. García-Gavín,^{a,*} L. Comba Pérez-Pérez,^a L. Requena,^b X. Wortsman^c

^a *Clínica Pérez & Gavín dermatólogos, Vigo, Pontevedra, Spain*

^b *Departamento de Dermatología, Fundación Jiménez Díaz, Universidad Autónoma, Madrid, Spain*

^c *Departamentos de Radiología y Dermatología, Instituto de Investigación y Diagnóstico por Imágenes en Piel y Tejidos Blandos (IDIEP), Clínica Servet, Facultad de Medicina, Universidad de Chile, Santiago, Región Metropolitana, Chile*

* Corresponding author.

E-mail addresses: jgavin@pgdermatologos.com, juangavin@gmail.com (J. García-Gavín).

Can Psoriasis Produce Irreversible Alopecia?☆



¿La psoriasis produce alopecia irreversible?

Dear Editor:

Can psoriasis cause irreversible alopecia? This was the question posed by one of our patients, a 21-year-old woman with no medical history of interest who had plaque psoriasis affecting the scalp, the upper part of the chest, and the midface area. Her condition, which had first developed more than 10 years earlier, was initially well controlled with topical drugs, but deteriorated rapidly when she was 18 years of age, causing significant psychosocial stress. Methotrexate, the first systemic treatment prescribed, was withdrawn due to poor tolerance. After that a very good response was achieved with ciclosporin, but her condition relapsed immediately when an attempt was made to reduce the dose. Ciclosporin was followed by etanercept, with minimal improvement; ustekinumab, which required frequent cycles of oral corticosteroids to control flares; and infliximab, to which she had a good response until the eighth cycle,

when her condition became progressively more severe. The scalp was the site with the most severe and extensive lesions, and hair density was significantly reduced on the psoriatic plaques. When infliximab was discontinued, the patient was admitted to hospital to facilitate more intensive topical care and to start treatment with prednisone and methotrexate 12.5 mg/wk, a regimen that achieved sig-

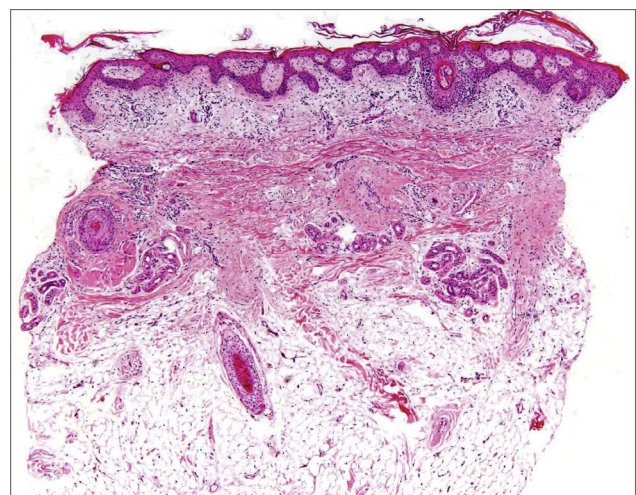


Figure 1 Vertical section. Note the marked reduction in hair follicle density and how follicles have been replaced by fibrous tracts.

☆ Please cite this article as: Gutiérrez García-Rodrigo C, Rivera Díaz R, Vanaclocha Sebastián F, Rodríguez Peralto JL. ¿La psoriasis produce alopecia irreversible?. *Actas Dermosifiliogr.* 2016;107:527–530.