
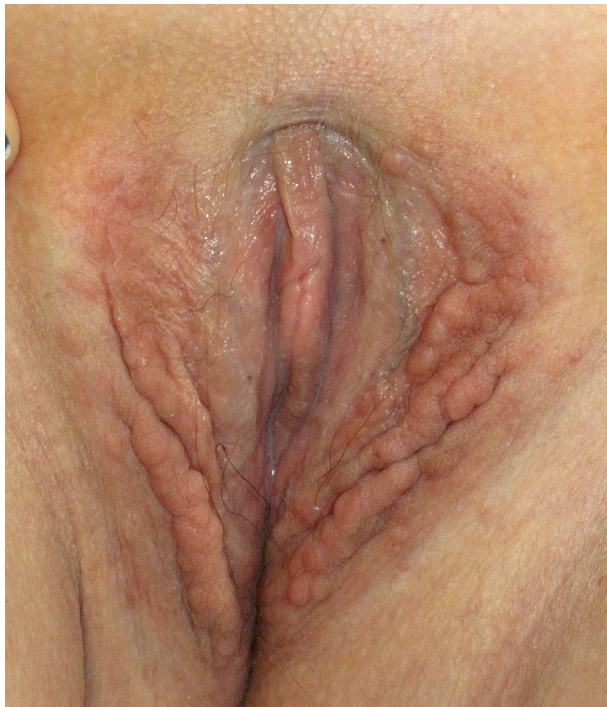

# Visual Dermatology: Eruptive Vulvar Syringoma


Journal of Cutaneous Medicine and Surgery  
2020, Vol. 24(2) 189–189  
© The Author(s) 2019  
Article reuse guidelines:  
sagepub.com/journals-permissions  
DOI: 10.1177/1203475419888868  
jcms.sagepub.com

Daniel Morgado-Carrasco<sup>1</sup> and Pablo Vargas-Mora<sup>2</sup> 



Syringomas are benign adnexal tumors which mainly occur on the periorbital area of young women, although can be observed on the neck, chest, extremities, and genitalia. In some cases, syringomas can be eruptive or even generalized, and multiple syringomas can be observed in familial syringomatosis. Syringomas in the context of tumor syndromes have been rarely reported. Vulvar syringomas have been scarcely described. The majority of patients present with pruritic skin-colored papules on the labia majora.<sup>1</sup>

## ORCID iD

Pablo Vargas-Mora  <https://orcid.org/0000-0002-9388-2940>

## Reference

1. Huang Y-H, Chuang Y-H, Kuo T-tong, Yang L-C, Hong H-S, Kuo T. Vulvar syringoma: a clinicopathologic and immunohistologic study of 18 patients and results of treatment. *J Am Acad Dermatol.* 2003;48(5):735-739.

<sup>1</sup>Department of Dermatology, Hospital Clínic de Barcelona, Universitat de Barcelona, Spain<sup>2</sup>Department of Dermatology, Faculty of Medicine, Universidad de Chile, Santiago, Chile. **Corresponding Author:** Daniel Morgado-Carrasco, Department of Dermatology, Hospital Clínic de Barcelona, Universitat de Barcelona, Calle Villarroel 170, Barcelona 08036, Spain; Email: morgadodaniel8@gmail.com. The authors have no conflicts of interest regarding this article, and have received no funding for this work.