

Bernese periacetabular osteotomy: functional outcomes in patients with untreated intra-articular lesions

Joaquín Lara, Alan Garín*, Cristhián Herrera, Selim Abara, Javier Besomi, Diego Villegas, Hassan Neumann and Carlos Tobar

Orthopaedic Surgery Department, Facultad de Medicina, Hip Center, Clínica Las Condes, Universidad de Chile, Santiago, Chile.

*Correspondence to: A. Garín. E-mail: alangarin@gmail.com

Submitted 25 August 2019; revised version accepted 24 February 2020

ABSTRACT

Developmental dysplasia of the hip (DDH) has been recognized to be a condition leading to osteoarthritis. Periacetabular osteotomy (PAO) has showed good results on hip preservation treatment for these cases. Nevertheless, intra-articular damage may be responsible for persistent post-operative symptoms, so treat the articular damage before or during the PAO has emerged as an alternative to address it. The objective is to identify the prevalence of intra-articular damage, functional outcomes of patients undergoing PAO with untreated intra-articular lesions and the survivorship free total hip arthroplasty (THA) at long-term follow-up. A retrospective review of 103 hips in 92 patients, mean age 26 years old (19–31), 96% females. Mean follow-up 7 years (range: 3–16). Intra-articular damage was evaluated with high-resolution magnetic resonance imaging (MRI) previous to perform the PAO, the chondral damage was evaluated using International Cartilage Repair Society classification. Harris Hip Score (HHS) was obtained in all patients. One hundred per cent of the cases had labral tears on MRI, hypertrophic labrum in 80.8% and paralabral cysts in 20.8%. Acetabular chondral damage was Grade 2 in 88.5% of the hips. HHS was good and excellent in 94%. Survivorship free of THA at 15 years was 87%. Chondrolabral damage is a common finding in patients with DDH. Despite that, excellent results are obtained with PAO without labral repair. We think the focus should be in the biomechanical and anatomical correction of the hip in patients with DDH.

INTRODUCTION

Developmental dysplasia of the hip (DDH) has been assumed to be a pre-osteoarthritic condition leading to osteoarthritis (OA) of the hip. The morphologic deformities associated with DDH including acetabular, femoral and soft tissue alterations lead to a decreased load-transferring articular area, abnormal stress distribution on the articular cartilage and elevated joint contact pressure leading in structural instability [1, 2].

Structural instability of the hip joint increases stress on soft tissue structures including cartilage, labrum and ligamentum teres. Decreased contact area on the joint surface results in increased contact stress on the cartilage with adaptive hypertrophy of the acetabular labrum and

ligamentum teres, which act as secondary stabilizers in the setting of deficient bony coverage [3].

Due to these changes, intra-articular damage is a common finding in patients with symptomatic acetabular dysplasia [4].

There are several types of redirection osteotomies for correcting the acetabular position. The Birmingham Interlocking Pelvic Osteotomy [5], Rotational Acetabular Osteotomy [6] and the Bernese periacetabular osteotomy [7, 8] (PAO) are options for addressing the goal of correct acetabular architecture before the onset of degenerative changes through the multi-planar reorientation of the articular surface.

The osteotomies have shown satisfactory long-term results. The Birmingham Interlocking Pelvic Osteotomy

[5] has a survivorship with a total hip arthroplasty (THA) as endpoint of 76% at 10 years and 57% at a mean of 17 years. The Rotational Acetabular Osteotomy [6] has shown a survivorship with radiographic signs of progression of OA as the endpoint of 82% at 20 years and, with conversion to THA as the endpoint with a rate of 94% at 20 years. According to the Bern group, the survivorship of PAO is 60.5% and 29% at 20 and 30 years of follow-up, respectively [7, 8]. Wells *et al.* [9] evaluated a group of 99 patients (121 hips) with a follow-up of 18 years, the survivorship with total hip replacement as endpoint was 74%, 26% were symptomatic and 53% of the hips remained asymptomatic and did not meet any failure criteria at last follow-up.

Recently, the literature has focused on the intra-articular pathologic findings present at the time of PAO, because these lesions may be responsible for persistent postoperative symptoms [10, 11]. Based on this concept, to address the intra-articular lesions through an arthroscopy prior to PAO or an open capsulotomy during at time of the PAO have emerged as a complementary surgery [10] in patients with symptomatic dysplasia of the hip. Currently, the role of the arthroscopy to treat intra-articular lesions of DDH before the PAO remains controversial [12].

The purpose of our study is to evaluate medium- and long-term clinical outcomes of patients undergoing PAO with untreated intra-articular lesions evidenced by previous magnetic resonance imaging (MRI). Determine the prevalence and characteristics of the intra-articular lesions by MRI. Evaluate the satisfaction, postoperative clinical score of patients undergoing PAO with untreated intra-articular lesions and the long-term survivorship of the hips with total hip replacement (THA) as endpoint.

MATERIALS AND METHODS

Retrospective study of patients who underwent PAO by the first author for symptomatic DDH. Dysplasia was defined with a lateral centre-edge angle (LCEA) $<25^\circ$ and/or Tönnis angle $>10^\circ$. Exclusion criteria were previous hip surgery, osteoarthritis Tönnis >2 (joint space <2 mm) on radiographs, any prior hip disease and absence of pre-operative MRI.

The group included 103 hips in 92 patients, mean age 26 years old (19–31), 96% females. Mean follow-up 7 years (range: 3–16) (Table I).

The surgical technique is a modification of approach of the original Bernese PAO [13] (Fig. 1).

Before the surgery, the patients were evaluated with X-rays and MRI 1.5 and 3 T. The parameters evaluated were signs of osteoarthritis, presence of labrum damage,

Table I. Demographic characteristics

Variables	N
Hips	103
Patients	92
Gender	Female 96%, male 4%
Mean age	26 years old (range: 19–31)
Follow-up	7 years (range: 3–16)

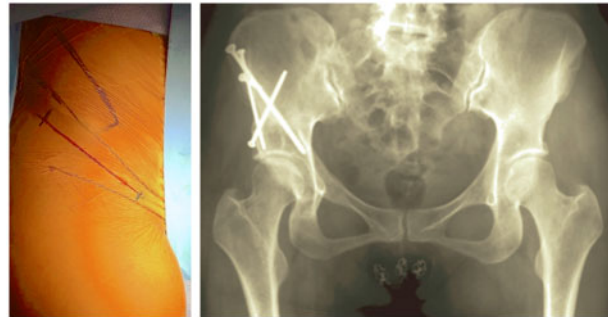

Fig. 1. Modified Ganz periacetabular osteotomy.

presence of cysts, chondral damage in the acetabulum and femoral head and ligamentum teres tears according International Cartilage Repair Society classification. All the images were evaluated by three musculoskeletal radiologists. Patients reported outcome scores, including the overall satisfaction and Harris Hip Score (HHS), were obtaining in all the patients before the surgery and at the last follow-up. The intra-class correlation coefficient with 95% confidence interval was used to measure the inter-observer and intra-observer agreements. The observer agreement was considered substantial for all the parameters evaluated. The survivorship was analysed by Kaplan–Meier curve. Data analysis was performed with SPSS (v21; IBM Corp). Institutional review board approval was obtained before this study began.

RESULTS

The preoperative X-ray showed and an average LCEA of 15° (-12.1° to 24.7°), Tönnis angle of 18° (10 – 35.5°) and an extrusion index of 67% (37.7–80%). The postoperative LCEA was 32° (18 – 48°), Tönnis angle 3° (-5° to 20°) and the extrusion index 85% (66–100%), the amount of correction was statistically significant in all the parameters ($P < 0.05$).

The MRI showed the presence of labral tears in 100% and hypertrophic labrum in 80.8%. Paralabral cysts were

found in 20.8% of the hips with absence of ligamentum teres tears (Table II).

The acetabular chondral damage was Grade 2 in 88.5% of the hips. The cartilage damage in the femoral head was Grade 1 in 65.4% of the cases (Fig. 2).

Regarding the clinical outcomes, 98% of the hips at the last follow-up had normal range of motion (flexion $>100^\circ$, adduction $>20^\circ$, abduction $>30^\circ$ and extension $>10^\circ$ painless) with 71% of the patients satisfied or very satisfied with the surgery.

The HHS before the surgery was poor in 57%, fair in 36% and good in 7% of patients. The HHS after the surgery at medium-term follow-up was fair in 6%, good in 19% and excellent in 75% of the patients ($P < 0.05$) (Table III).

We did not have major complications (mortality, neurological and deep vein thrombosis). Regarding minor complications, related to the wounds, we had 15.4% of

Table II. MRI findings

Findings	Percentage
Labrum tears	100%
Hypertrophic labrum	80.8%
Paralabral cysts	20.8%
Ligamentum teres tear	0%

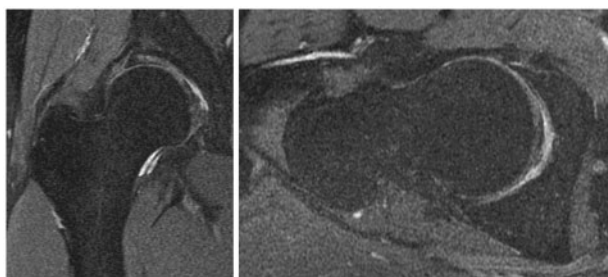


Fig. 2. Chondral damage. Coronal and axial view.

Table III. Harris Hip Score before and after surgery

Grading	Before (% of patients)	After (% of patients)
Poor	57%	0%
Fair	36%	6%
Good	7%	19%
Excellent	0%	75%

hypertrophic scars, 17.7% of hyperpigmentation, dehiscence 4% and 4.4% of depressed scars. We have to note that the patients underwent different incisions according to the curve of the main author (original modified incision, straight and shortened, 'Z' shape and oblique inguinal).

Kaplan–Meier analysis with THA as the endpoint revealed a survival rate of 98% (95% confidence interval [CI] 91–99%) at 5 years, 94% (95% CI 81–98%) at 10 years and 87% (65–96%) at 15 years (Fig. 3).

DISCUSSION

This study shows that PAO with untreated intra-articular lesions achieved good and excellent clinical outcomes at medium-term follow-up with a high overall satisfaction with the procedure. Besides, the main finding is the long-term survivorship free of total hip replacement.

The presence of intra-articular damage in patients with DDH is described in the literature. Ross *et al.* [14] evaluated this damage with arthroscopy in 73 hips of patients with acetabular dysplasia associated with mechanical symptoms in whom the hip arthroscopy was performed prior to PAO. They found labral tear in 65.8% of the hips with a presence of a hypertrophic labrum in 63% of the total hips; 68.5% of the hips showed acetabular chondromalacia. Some alteration in ligamentum teres was evidenced in 30.1% of the hips. The functional outcome of the patients was not evaluated during the follow-up of this combined management.

Domb *et al.* [15] performed an arthroscopy in patients with mechanical symptoms and labral pathology identified in MRI concomitant to PAO in 17 hips. According to the imaging study, 16 of 17 hips presented a labral injury. In the arthroscopic evaluation, 82% of the hips presented a labral tear. Ninety-four per cent presented chondral lesions,

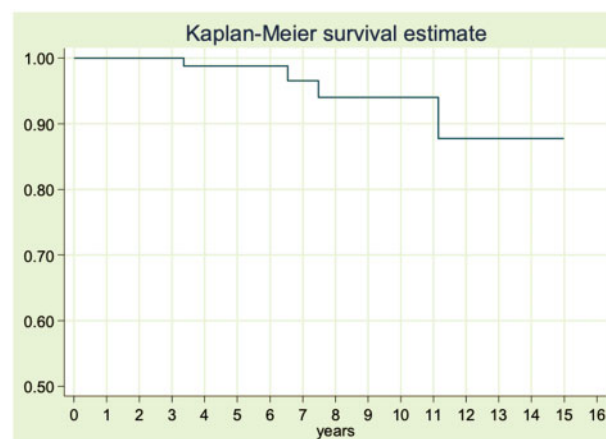


Fig. 3. Survivorship free total hip arthroplasty.

acetabular cartilage injury was found in 82% of the cases. The CAM type FAI signs were found in 58% of the hips and ligamentum teres pathology presented in 88%.

Hagio *et al.* [10] performed a retrospective review of 75 hips in 72 patients with acetabular dysplasia who underwent curved periacetabular osteotomy (CPO) in whom MRI scans of the hip were undertaken pre-operatively for the assessment of labral pathology. Patients were divided into three groups based on whether they had labral tears, and how they were treated. Labral tears were diagnosed pre-operatively in 47 hips (45 patients). Of these, 27 (25 patients) underwent CPO alone and were classified as the labral tear alone (LT) group. The remaining 20 hips (20 patients) which had a labral tear underwent CPO with an additional arthrotomy and femoral head-neck osteochondroplasty. It showed that there was no significant difference between groups for the progression of osteoarthritis, no patient required conversion to THA and the rate of reoperation did not differ significantly between the three groups. They concluded based on their results at least in the short term, labral tears do not appear to have an adverse effect on the function of hip, the progression of osteoarthritis or the need for further surgery in these patients, so the surgeons should consider the use of PAO to treat acetabular dysplasia regardless of the existence of labral tears.

In our series, 100% of the hips presented labral tears, with presence of a hypertrophic labrum in 81% of the patients, with a high prevalence of chondral lesions in the acetabulum. The high prevalence of intra-articular injuries in dysplastic hips is similar, such as reported in the literature. It is important to remark that on our study the prevalence of intra-articular lesions was assessed by MRI, not by hip arthroscopy or open capsulotomy.

The results of the series of patients in whom an arthroscopy before the PAO or as only treatment was performed are contradictory. Byrd and Jones [16] published the results of 48 hips that were followed for 27 months. It showed an improvement in modified HHS from 57 to 83 points, with two failures in which an arthroplasty had to be performed. Domb *et al.* [17] published the results in 22 hips with borderline dysplasia (lateral centre-edge angle $\geq 18^\circ$ and $\leq 25^\circ$) in which a capsular plication was performed together with the arthroscopic labral repair, the HHS improved from 69 to 82.6 with a patient satisfaction of 9.4 at 27.5 months follow up.

Conversely, some authors have reported poor results in patients with dysplasia undergoing a treatment for intra-articular damage. Matsuda and Khatod [18] reported two cases of patients with severe dysplasia who progressed quickly to hip arthritis despite arthroscopic labral repair.

Despite the possible benefits of hip arthroscopy in cases of mild or borderline dysplasia, the authors believe that arthroscopy should not be performed with PAO in cases of severe dysplasia. Although arthroscopic surgery is much less invasive and more popular among hip surgeons, arthroscopic labral repair fails in the medium term to provide symptomatic improvement and even it may compromise the performance of a PAO due to the progression to significant osteoarthritis.

Parvizi *et al.* [19] reported the 3.45 years follow-up of 36 dysplastic hips in which an arthroscopic labral debridement was performed. The results showed that there was an improvement in the scores in the sixth post-operative week but decreased after 2 years. 66% of the scopes failed to control the symptoms. Three patients had to undergo a new hip arthroscopy 1 year after the procedure, which also failed. At 34 months of follow-up, 38% of the hips had accelerated osteoarthritis or migration of the femoral head after arthroscopy. 47% of the patients of the cohort, due to the continuous pain and functional alterations, were submitted to an open surgery, such as a PAO, femoroacetabular plasty or THA. All these patients improved their function with total pain relief. The authors concluded that treatment of the labral tear in isolation without addressing the underlying morphologic problem in the case of retroversion leads to failure and they suggest not to perform labral debridement in patients with dysplasia without addressing the underlying morphologic abnormality because it is very likely that patients with DDH and labral pathology have also chondral lesions that are likely contributing to symptoms. Debridement of torn labrum and/or chondral lesions without addressing the abnormal biomechanical function that led to these problems is likely to lead to further deterioration of the remaining labrum and articular cartilage and finally causing progressive hip arthritis.

The Anchor group [20] in a multi-centre study found that the prevalence of a prior failed ipsilateral arthroscopic hip procedure in patients undergoing a subsequent PAO for the correction of symptomatic acetabular dysplasia has increased 192%, from 2008 to 2015 (5.1–10%). While the incidence of ipsilateral surgery, other than hip scope, prior to PAO remained constant over the duration of the study, the proportion of prior hip surgeries that are arthroscopic procedures have more than tripled. Their findings illustrate that younger age, female gender and mild radiographic dysplasia were associated with higher rates of utilization of isolated arthroscopic hip surgery in the presence of acetabular dysplasia. The authors argued that the patients that tend to be misdiagnosed are those with mild dysplasia. The point is that while these patients have mild acetabular dysplasia,

as determined by standard radiographic criteria, the early outcomes with isolated arthroscopy are variable. Thus, the appropriateness of isolated arthroscopy in this patient population must be questioned.

In a matched-cohort study of the Anchor group [21], evaluating the patient-reported outcomes between patients with primary PAO and patients with previous failed hip arthroscopy, the findings were that the patients who underwent PAO after failed hip arthroscopy exhibited worse pain, function and quality of life and lower level of physical activity as measured by lower mHHS (57 versus 62; $P=0.04$), lower Western Ontario and McMaster Osteoarthritis Index (WOMAC) pain scores (53.5 versus 60.5; $P=0.04$), lower 12-item Short Form (SF-12) physical component scores (34 versus 40; $P=0.001$) and lower University of California, Los Angeles (UCLA) activity scores (5 versus 7; $P=0.001$) compared with the non-previous arthroscopy cohort.

There are other reports published showing worse results in patients with DDH treated with arthroscopy. Fukui *et al.* [22] described 5/28 patients (18%) underwent conversion to THA, 2 (7%) underwent a PAO and 2 (7%) required a revision hip arthroscopy for an overall proportion of 32% failure of arthroscopic treatment for mild-to-moderate dysplasia (LCEA 15–19°).

The clinical outcomes of our study show that the HHS was good and excellent in 94% of the patients. These results are similar to those published by Beulé *et al.* [23] on 67 patients (72 hips) undergoing PAO for hip dysplasia with a minimum 1-year follow-up. Of the 41 patients who had completed 5 post-operative years, 39 (95%) were available for follow-up. Overall, the WOMAC improved from 54 to 74, the SF-12 physical component score improved from 37 to 45, with no change in the mental component, and the UCLA activity score improved from 5 to 7. All these improvements were statistically significant. There was one conversion to THA (1.4%) at 86-month post-operatively. The authors also performed osteochondroplasty of the head and neck junction using an arthrotomy in 68% of patients concurrent with the PAO. A higher pre-operative alpha angle was the only factor associated with lower post-operative WOMAC scores. The authors alluded to the presence of increased cartilage damage in the presence of the cam lesion as a potential cause of poorer outcomes, and they suggested addressing it along with intra-articular pathologic features as a topic of further research.

Finally, the survivorship without THA of 87% at 15 years follows a similar survivorship curve of the Bern Group published by Steppacher *et al.* [7] of 60% at

20 years and the results published by Wells *et al.* [9] of 74% at 18 years with joint preservation.

Our study has some limitations. First of all, the study is a retrospective one of a group composed only by patients who underwent PAO alone without a control group. Second, there is a risk of selection bias due to the retrospective nature of the study. During the recruitment of the cases, we dismissed the cases without all the pre-operative studies. In addition, the range of motion data was recorded by different authors, without a reliability testing between the measurers, so there is a risk of measurement error and assessment bias. We did not evaluate all the complications during the follow-up of the PAO, we focused only in the total hip replacement as endpoint and failure of the osteotomy. Finally, we decided to use the HHS as a clinical outcome based in its validity and reliability but it has the limitation that it does not evaluate the function during sports/recreation activities neither the hip-related quality of life. However, this study is the first one publishing the intra-articular damage, not only labral tears, in patients with hip dysplasia by MRI previous to perform a PAO. Moreover, the study makes evident strong data at medium- and long-term follow-up related to functional outcomes and survivorship free total hip replacement.

In summary, patients with symptomatic hip dysplasia have good and excellent results at medium and longterm follow-up performing a PAO without treating the intra-articular lesions with a survivorship of 87% at 15 years free THA. Because there is no evidence of better outcomes addressing the articular damage previous to PAO, we recommend to perform a PAO as the initial treatment and treat the intra-articular lesions only if they are symptomatic during the follow-up.

ACKNOWLEDGEMENT

All authors agree that this work is original and not previously published.

CONFLICT OF INTEREST STATEMENT

None declared.

REFERENCES

1. Ganz R, Klaue K, Vinh TS *et al.* A new periacetabular osteotomy for the treatment of hip dysplasias: technique and preliminary results. *Clin Orthop Relat Res* 1988; **232**: 26–36.
2. Hartofilakidis G, Karachalios T, Stamos KG. Epidemiology, demographics, and natural history of congenital hip disease in adults. *Orthopedics* 2000; **23**: 823–7.

3. Leunig M, Siebenrock KA, Ganz R. Rationale of periacetabular osteotomy and background work. *Instr Course Lect* 2001; **50**: 229–38.
4. Fujii M, Nakashima Y, Noguchi Y *et al.* Factors associated with severity of intra-articular lesions in patients with severe hip dysplasia. *Arthroscopy* 2016; **32**: 1581–9.
5. Mei-Dan O, Jewell D, Garabekyan T *et al.* The Birmingham Interlocking Pelvic Osteotomy for acetabular dysplasia: 13- to 21-year survival outcomes. *Bone Joint J* 2017; **99-B**: 724–31.
6. Yasunaga Y, Ochi M, Yamasaki T *et al.* Rotational acetabular osteotomy for pre- and early osteoarthritis secondary to dysplasia provides durable results at 20 years. *Clin Orthop Relat Res* 2016; **474**: 2145–53.
7. Steppacher SD, Tannast M, Ganz R *et al.* Mean 20-year followup of Bernese periacetabular osteotomy. *Clin Orthop Relat Res* 2008; **466**: 1633–44.
8. Lerch TD, Steppacher SD, Liechti EF *et al.* One-third of hips after periacetabular osteotomy survive 30 years with good clinical results, no progression of arthritis, or conversion to THA. *Clin Orthop Relat Res* 2017; **475**: 1154–68.
9. Wells J, Millis M, Kim YJ *et al.* Survivorship of the Bernese periacetabular osteotomy: what factors are associated with long-term failure? *Clin Orthop Relat Res* 2017; **475**: 396–405.
10. Hagio T, Naito M, Nakamura Y *et al.* Do labral tears influence poor outcomes after periacetabular osteotomy for acetabular dysplasia? *Bone Joint J* 2016; **98-B**: 741–6.
11. Dwyer MK, Lee JA, McCarthy JC. Cartilage status at time of arthroscopy predicts failure in patients with hip dysplasia. *J Arthroplasty* 2015; **30**: 121–4.
12. Lodhia P, Chandrasekaran S, Gui C *et al.* Open and arthroscopic treatment of adult hip dysplasia: a systematic review. *Arthroscopy* 2016; **32**: 374–83.
13. Lara J, Villegas D, Besomi J *et al.* Oblique inguinal incision in Bernese periacetabular osteotomy: surgical technique. *JAAOS Glob Res Rev* 2017; **1**: e061.
14. Ross JR, Zaltz I, Nepple JJ *et al.* Arthroscopic disease classification and interventions as an adjunct in the treatment of acetabular dysplasia. *Am J Sports Med* 2011; **39**: 72–8S.
15. Domb BG, Lareau JM, Baydoun H *et al.* Is intraarticular pathology common in patients with hip dysplasia undergoing periacetabular osteotomy? *Clin Orthop Relat Res* 2014; **472**: 674–80.
16. Byrd JW, Jones KS. Hip arthroscopy in the presence of dysplasia. *Arthroscopy* 2003; **19**: 1055–60.
17. Domb BG, Stake CE, Lindner D *et al.* Arthroscopic capsular plication and labral preservation in borderline hip dysplasia: two-year clinical outcomes of a surgical approach to a challenging problem. *Am J Sports Med* 2013; **41**: 2591–8.
18. Matsuda DK, Khatod M. Rapidly progressive osteoarthritis after arthroscopic labral repair in patients with hip dysplasia. *Arthroscopy* 2012; **28**: 1738–43.
19. Parvizi J, Bican O, Bender B *et al.* Arthroscopy for labral tears in patients with developmental dysplasia of the hip: a cautionary note. *J Arthroplasty* 2009; **24**: 110–3.
20. Haynes JA, Pascual-Garrido C, An TW *et al.* Trends of hip arthroscopy in the setting of acetabular dysplasia. *J Hip Preserv Surg* 2018; **5**: 267–73.
21. Novais EN, Coobs BR, Nepple JJ *et al.*; ANCHOR Study Group. Previous failed hip arthroscopy negatively impacts early patient-reported outcomes of the periacetabular osteotomy: an Anchor Matched Cohort Study. *J Hip Preserv Surg* 2018; **5**: 370–7.
22. Fukui K, Trindade CA, Briggs KK *et al.* Arthroscopy of the hip for patients with mild to moderate developmental dysplasia of the hip and femoroacetabular impingement: outcomes following hip arthroscopy for treatment of chondrolabral damage. *Bone Joint J* 2015; **97-B**: 1316–21.
23. Beaulé PE, Dowding C, Parker G *et al.* What factors predict improvements in outcomes scores and reoperations after the Bernese periacetabular osteotomy? *Clin Orthop Relat Res* 2015; **473**: 615–22.