

Early implant placement with or without alveolar ridge preservation in single tooth gaps renders similar esthetic, clinical and patient-reported outcome measures: One-year results of a randomized clinical trial

Brend P. Jonker¹  | Franz J. Strauss^{2,3}  | Nadja Naenni² | Ronald E. Jung²  | Eppo B. Wolvius¹ | Justin Pijpe^{1,4}

¹Department of Oral & Maxillofacial Surgery, Erasmus University Medical Center Rotterdam, Rotterdam, the Netherlands

²Clinic of Reconstructive Dentistry, Center of Dental Medicine, University of Zurich, Zurich, Switzerland

³Department of Conservative Dentistry, Faculty of Dentistry, University of Chile, Santiago, Chile

⁴Department of Oral & Maxillofacial Surgery, Catharina Hospital Eindhoven, Eindhoven, the Netherlands

Correspondence

Brend P. Jonker, Department of Oral- and Maxillofacial Surgery, Erasmus Medical Center, Dr. Molewaterplein 40, 3015 GD Rotterdam, the Netherlands.
Email: b.jonker@erasmusmc.nl

Funding information

Implants were provided by Straumann AG and biomaterials by Geistlich Pharma AG

Abstract

Objectives: To test whether early implant placement with alveolar ridge preservation (ARP) results in different esthetic, clinical and patient-reported outcome measures (PROMs) compared with early implant placement without ARP.

Material and methods: Seventy-five patients requiring single tooth extraction in the anterior maxilla were recruited. Following tooth extraction, the patients were randomly allocated to three groups: (a) ARP using demineralized bovine bone mineral containing 10% collagen (DBBM-C) covered by a collagen matrix (CM) ($n = 25$), (b) ARP using DBBM-C covered with a palatal graft (PG) ($n = 25$) and (c) spontaneous healing (control) ($n = 25$). Eight weeks after tooth extraction, a CBCT was taken and early implant placement was performed in all patients. Esthetic, clinical and PROMs were evaluated one year post-loading.

Results: A total of 70 patients were available for re-examination at one year post-loading. The median mid-facial mucosal margin change amounted to -0.02 mm (IQR -0.27 – 0.46) in the CM group, -0.13 mm (IQR -0.44 – 0.25) in the PG group and -0.14 mm (IQR -0.29 – 0.07) in the control group, with no significant differences between the groups. Mean PES scores amounted to 7.0 ± 1.4 in the CM group, 7.1 ± 1.5 in the PG group and 7.3 ± 1.7 in the control group without significant differences between the groups. Plaque, bleeding on probing and probing depth did not differ between treatment groups. PROMs in general revealed no significant differences between the groups.

Conclusion: Early implant placement with ARP using either a collagen matrix or a palatal graft rendered similar esthetic, clinical and PROMs to early implant placement without ARP. When a failing tooth can be replaced with an implant within 2 months after tooth extraction, the added value of ARP might be clinically negligible.

This is an open access article under the terms of the Creative Commons Attribution-NonCommercial-NoDerivs License, which permits use and distribution in any medium, provided the original work is properly cited, the use is non-commercial and no modifications or adaptations are made.

© 2021 The Authors. *Clinical Oral Implants Research* published by John Wiley & Sons Ltd.

KEYWORDS

alveolar ridge preservation, clinical trial, early implant placement, patient-centered outcomes

1 | INTRODUCTION

Following tooth extraction, the alveolar ridge undergoes evident horizontal reduction and vertical reduction leading to an alteration of the ridge profile (Schropp et al., 2003). This alteration of the alveolar ridge has been extensively studied and documented. Systematic reviews have revealed a reduction in the alveolar ridge by approximately 50% in the first 3–6 months, affecting mainly the buccal area (Couso-Queiruga et al., 2020; Tan et al., 2012). This substantial reduction may impede the replacement of missing teeth with dental implants in a prosthetically ideal position. Moreover, this may also yield unpleasant esthetic outcomes since the soft tissues are also affected (Grunder, 2000). In order to overcome these drawbacks, alveolar ridge preservation procedures have been introduced.

Alveolar ridge preservation (ARP) is a common and well-established procedure that aims at maintaining the alveolar ridge following tooth extraction to subsequently allow for the placement of dental implants in a prosthetically driven position (Avila-Ortiz et al., 2019; MacBeth et al., 2017). It should be noted that ARP cannot prevent the physiological ridge alterations after tooth extraction but it can limit the extent to which these occur (Avila-Ortiz et al., 2019). In addition, ARP can simplify implant placement procedure since it reduces the necessity of simultaneous guided bone regeneration (GBR) at early implant placement (4–8 weeks after tooth extraction) (Jonker et al., 2021; Thoma et al., 2020a). Despite these promising findings, there is still a lack of sound clinical evidence regarding the combination of ARP with early implant placement.

Early implant placement involves the placement of dental implants 4–8 weeks after tooth extraction (Hammerle et al., 2004; Tonetti et al., 2019). This surgical protocol takes place before most of the hard tissue alterations occur, but allows proper soft tissue healing. Early implant placement might offer a slightly increased stability of the peri-implant hard and soft tissues leading to more favorable esthetic outcomes than immediate implant placement (Graziani et al., 2019; Sanz et al., 2012). Recent studies have shown that ARP followed by early implant placement reduces the frequency of simultaneous GBR at implant placement, thereby simplifying the surgical procedure (Avila-Ortiz et al., 2019; Jonker et al., 2020). Therefore, it is reasonable to suggest that this approach might also optimize the clinical, esthetic and patient-reported outcome measures (PROMs). However, there is a lack evidence of whether ARP can improve the afore-mentioned outcomes applying an early implant placement protocol.

According to the Consensus Report of the XV European Workshop in Periodontology, clinical studies regarding early implant placement are lacking (Graziani et al., 2019). This is of utmost importance since it affects the decision-making process and limits the application of this treatment protocol in routine clinical practice.

Therefore, the aim of the present randomized controlled trial was to test whether early implant placement with ARP results in different clinical, esthetic, and PROMs than early implant placement without ARP after one year of loading.

2 | MATERIALS AND METHODS

2.1 | Study design

The study was designed as a RCT. The study protocol was approved by the medical ethical committee, the central committee on human subjects (MEC-2015-016; NL49965.078.14) and registered in the Dutch trial register (NL6497). This research was conducted according to the principles of the Declaration of Helsinki. The CONSORT statement was used for reporting (Moher et al., 2010).

Study design with inclusion and exclusion criteria, together with the results of the soft tissue contour and radiographic evaluation at implant placement, has been previously reported in detail (Jonker et al., 2021). In brief, after tooth extraction patients were randomly allocated to one of the following treatment modalities:

1. CM: Demineralized bovine bone mineral with 10% collagen (DBBM-C, Geistlich Bio-Oss® Collagen, Geistlich Pharma) and covered with a collagen matrix (CM, Geistlich Mucograft® Seal, Geistlich Pharma).
2. PG: DBBM-C covered with an autogenous soft tissue “punch” graft (PG) harvested from the palate.
3. Control: Spontaneous healing.

2.2 | Study population

Fully dentate patients in the anterior maxilla requiring a single tooth extraction in the anterior zone (incisor, canine, or first/second premolar) leading to a single tooth gap were considered for inclusion. Patients were referred for implant placement by their general practitioner. Patients exhibiting ongoing periodontal disease, smoking, uncontrolled diabetes, current chemotherapy, or a history of radiotherapy in the head-and-neck region were excluded. Before tooth extraction, clinical parameters including Plaque Index (PI), modified bleeding index (mBI), Gingival Index (GI) and probing depth were assessed at 6 sites per tooth (mesiobuccal, buccal, distobuccal, distolingual, lingual and mesiolingual). Furthermore, CBCT scans were taken at different time points. At first, a CBCT scan was taken after tooth extraction, and a second one, prior to implant placement (Jonker et al., 2021). All surgeries were performed by the same surgeon (JP).

2.3 | Surgical procedure

Tooth extraction was performed using a flapless approach and taking care of preserving the buccal bone plate as well as the surrounding soft tissues. After tooth extraction, the patients were randomly assigned to one of the treatment modalities. For CM, the socket was filled with DBBM-C up to the level of the lingual/palatal bone plate. The soft tissue borders of the alveolus were de-epithelialized using a rotating diamond burr, and a CM was placed on top and sutured to the gingival margins of the socket with interrupted sutures (6-0 Ethilon, Ethicon). For PG, a free epithelialized gingival graft of 4–5 mm thickness harvested with a biopsy punch was placed on top and sutured to the socket with interrupted sutures (6-0 Ethilon, Ethicon). The donor site was covered with a tissue adhesive (Histoacryl, Braun Medical B.V.). For the control group, a cross-mattress suture was performed allowing spontaneous healing.

All patients were instructed to rinse twice a day with 0.12% chlorhexidine and received pain medication (Ibuprofen) and antibiotics (Amoxicillin) for 5 days (Romandini et al., 2019). Sutures were removed after 1 week.

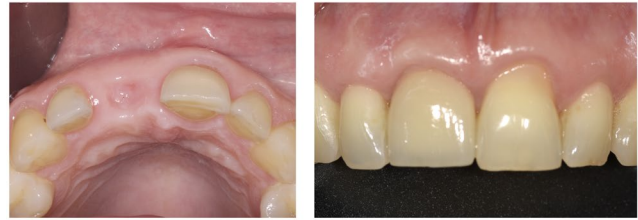2.4 | Implant placement

Eight weeks after tooth extraction, early implant placement was performed in all groups. The implants had a diameter of 3.3–4.1 mm and a length of 8–12 mm (Bone Level Tapered, SLActive, Roxolid, Institute Straumann AG) depending on the bone and space available. After raising a full-thickness flap, implant bed preparation took place according to the manufacturer's guidelines and implants were placed. In case of a thin peri-implant buccal bone thickness (PBT) (<2 mm) (Grunder et al., 2005; Monje et al., 2019; Spray et al., 2000) or a dehiscence at the buccal aspect, guided bone regeneration (GBR) was performed. This implied the coverage of the buccal aspect with locally harvested autogenous bone chips combined with DBBM granules (Bio-Oss®, Geistlich Pharma) and a resorbable membrane (Bio-Gide®, Geistlich Pharma). Primary tension-free flap closure was performed by means of single interrupted sutures.

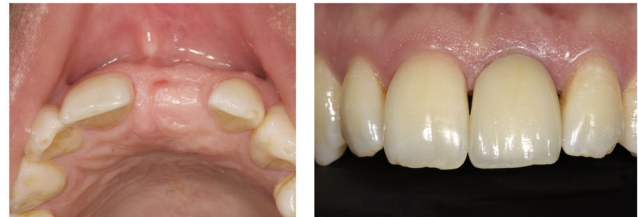2.5 | Follow-up

After the surgical procedures, the patients were referred to the dental office of the referring dentist for prosthetic treatment. Implants were restored with cemented or screw-retained fixed prosthesis according to the preference of the referring dentist. The patients were re-examined 1–4 weeks after crown delivery (baseline: BL), 6-month (FU-6m) and at one-year (FU-1) follow-up. Figure 1 shows a representative clinical case of each group before implant placement and at FU-1.

CM



PG



Control

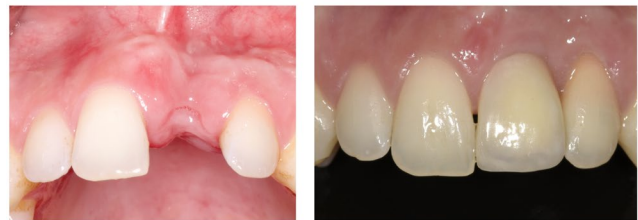

FIGURE 1 Representative cases of each treatment group; CM, PG and control group before implant placement and after 1 year of loading

2.6 | Outcome measurements

2.6.1 | Primary outcome

Change in the mid-facial marginal mucosal margin between BL and FU-1.

2.6.2 | Secondary outcomes

- Peri-implant esthetic score (PES) and white esthetic score (WES)
- Complications, implant survival and success
- Plaque Index (PI) (Loe, 1967)
- Modified bleeding index (mBI) (Mombelli et al., 1987)
- Gingival Index (Loe, 1967)
- Probing depth (PD) and bleeding on probing (BOP)
- Patient-reported outcome measures (PROMs)

2.7 | Change in the mid-facial mucosal margin

Alginate impressions were taken at BL, FU-6 and one-FU-1 of follow-up, and dental casts were fabricated. Cast models were scanned

with a 3D scanner (7Series Model). The obtained STL files were imported into an image analysis software (Swissmeda-Software) as previously described (Bienz et al., 2017; Pirc et al., 2020; Sanz Martin et al., 2016). Digital casts were superimposed automatically by the software and manually adjusted with the implant crown serving as the reference. Measurements were performed by a calibrated, blinded evaluator with access to the STL files only.

A longitudinal slice was selected dividing the crown mesiodistally into two equal parts (Figure 2). A line coinciding with the tooth axis was then drawn in the transversal images of the sections. Changes in mid-facial mucosal margin between BL and FU-1 of follow-up were assessed by calculating clinical crown height changes in mm in an apico-coronal direction from the incisal edge to the mucosal/gingival margin axis. In case of digitized casts with irregularities at the mid-facial mucosal margin, the longitudinal slice was slightly moved to allow a correct measurement. All the measurements were performed twice by the same blinded investigator with one week apart between the measurements.

2.8 | Esthetic outcomes

Esthetic outcomes were evaluated using the modified PES and WES (Belser et al., 2009; Fürhauser et al., 2005). The PES/WES scores were evaluated independently by two blinded researchers on the basis of digital photographs following a standardized protocol.

2.9 | Complications, implant survival and success

Mucosal dehiscence, swelling, infection, bleeding, allergic reactions and other complications were assessed at 2 weeks as well as at BL, FU-6m and FU-1. Implant survival was defined as implant in place and stable assessed by hand testing. Implant success was defined by the lack of all of the following: mobility, persistent subjective complaints, PD \geq 5 mm and BOP.

2.10 | Clinical parameters

PI, mBI, GI and PD were recorded at BL, FU-6m and FU-1 by two calibrated clinicians (JP/BJ) who were unaware of the treatment allocation.

2.11 | Patient-reported outcome measures (PROMs)

PROMs were assessed with questionnaires using a visual analogue scale (VAS 0–10) at BL, FU-6m and FU-1. The questionnaires focused on experienced pain, swelling and stress of surgery. Furthermore, patient satisfaction regarding the implant crown, the peri-implant soft tissues and the total dentition was also evaluated.

2.12 | Randomization and treatment allocation

According to the block randomization method (Urbaniak & Plous, 2013), patients were randomly allocated to one of the 3 treatment groups. The patient allocation sequence was concealed from the surgeon (JP) in opaque, sealed envelopes until the very last step of the surgical procedure. The patients were not blinded.

2.13 | Statistical analysis

The metric variables with mean, standard deviations, median and quartiles were described. Linear models using generalized estimation equations (GEE) were conducted to assess changes in esthetic, clinical and PROMs over time according to the treatment group. Wald's chi-square statistic was used to conclude about main effects and interactions. This methodological approach was used because of the within-subject correlation of repeated measurements through the follow-up. Post hoc tests were carried out correcting by Bonferroni's criteria. The sample size calculation of the present study was based on the change in the marginal gingival margin after 1 year of loading

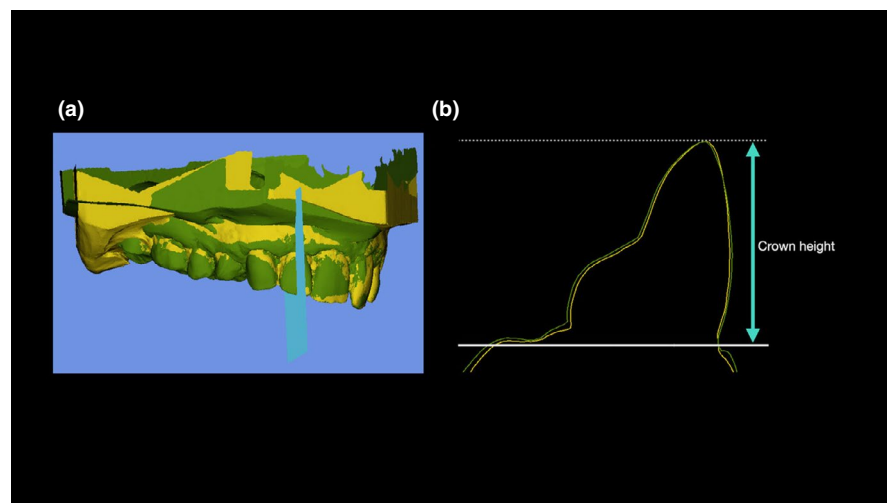


FIGURE 2 Measurement of the change in mid-facial mucosal margin via superimposition of STL models. (a) Superimposition of baseline STL model (yellow) and one-year follow-up (green). Blue slice indicates a longitudinal slice dividing the crown mesiodistally into two equal parts. (b) The length of the crown height was measured, and the change in the length between baseline and one-year follow-up was calculated

using an early placement protocol (Buser et al., 2009). Assuming a 0.5 mm difference in the marginal gingival margin as clinically relevant along with a common SD of 0.58 mm (Buser et al., 2009), with a power of 80% and a type I error rate of 5%, 21 participants per group were needed to find significant differences. To compensate for possible dropout, 25 participants per group were recruited.

3 | RESULTS

3.1 | Study sample

From the total of patients screened, 75 were included and randomized into one of the treatment groups (25 patients per group). Figure 3 shows the CONSORT flow diagram. One patient in the control group was not treated according to the randomization and was treated according to the PG protocol instead. This patient

was analyzed according to the randomization as suggested by the CONSORT guidelines. Five patients (two in CM, one in PG and 2 in control) were lost over the one-year follow-up. One patient in the control group had an early implant failure. Patient characteristics are shown in Table 1.

3.2 | Change in mid-facial mucosal margin

The median change in the mid-facial mucosal margin between baseline and FU-1 amounted to -0.02 mm (IQR -0.27 to 0.46) in CM group, -0.13 mm (IQR -0.44 to 0.25) in PG group and -0.14 mm (IQR -0.29 to 0.07) in control group, with no significant differences between the groups ($p = .136$). The negative numbers indicate a coronal migration of the mid-facial mucosal margin. This migration was statistically significant ($p = .046$), but the magnitude of this migration was similar between groups ($p = .336$).

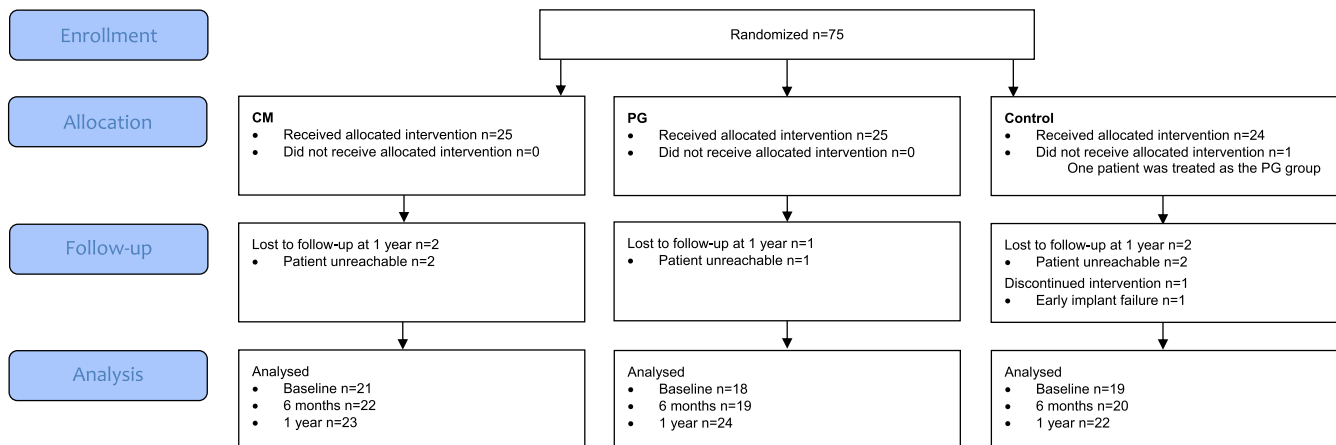


FIGURE 3 CONSORT Flow Diagram

TABLE 1 Patient characteristics

Group	CM	PG	Control
Number of patients included	25	25	25
Age (years)	49 ± 16	50 ± 13	44 ± 12
Gender (female/male)	13/12	11/14	18/7
Center (EMC/CZE)	17/8	16/9	17/8
Cause of tooth loss (fracture/infection/resorption)	17/6/2	17/8/0	17/6/2
Location of implant (I1, I2, C, P1, P2)	8/2/4/4/7	7/6/0/6/8	7/4/0/6/8
Implant length 8/10/12 mm	0/7/18	0/6/19	1/8/16
Implant diameter 3.3 / 4.1 mm	4/21	9/16	9/16
ARW at -1 mm	8.5 ± 1.2	8.1 ± 1.5	8.9 ± 1.5
ARW at -3 mm	9.5 ± 1.3	8.9 ± 1.5	9.6 ± 1.5
ARW at -5 mm	10.1 ± 1.5	9.4 ± 1.7	9.7 ± 1.5
Buccal bone height	10.1 ± 2.4	9.0 ± 3.9	9.6 ± 3.9
Palatal bone height	10.8 ± 2.1	10.4 ± 2.1	10.6 ± 2.7

Note: Frequencies of the actual values and the means ± SD.

Abbreviations: ARW, alveolar ridge width and buccal/palatal bone height measured on CBCT after tooth extraction; CM, collagen matrix group, CZE, Catherina Hospital Eindhoven; EMC, Erasmus Medical Center; PG, palatal graft group.

TABLE 2 Esthetic outcomes of the treatment groups via the modified pink esthetic index (PES) and the modified white esthetic score (WES) at baseline (BL), 6-month (FU-6m) and one-year (FU-1) follow-up

	CM	PG	Control	p-value (Treatment effect)	p-value (Interaction effect)	p-value (Time effect)
PES						
BL	6.3 ± 1.1 n = 18	6.2 ± 1.6 n = 18	6.1 ± 1.4 n = 19	.837	.479	<.001
FU-6m	6.8 ± 1.3 n = 20	6.8 ± 1.3 n = 18	7.0 ± 1.4 n = 19			
FU-1	7.0 ± 1.4 n = 22	7.1 ± 1.5 n = 22	7.3 ± 1.7 n = 21			
WES						
BL	7.2 ± 1.5 n = 18	7.7 ± 1.6 n = 18	7.6 ± 1.4 n = 19	.359	.682	.219
FU-6m	7.3 ± 1.4 n = 20	7.6 ± 1.5 n = 18	7.8 ± 1.0 n = 19			
FU-1	7.3 ± 1.7 n = 22	7.8 ± 1.3 n = 22	8.0 ± 0.9 n = 21			

Note: Mean ± SD of PES and WES using a scale from 0 to 10; changes over time and differences between the treatment groups were assessed using generalized estimation equations (GEE). Wald's chi-square statistic was used to conclude about main effects and interactions. PES index increased significantly over time ($p < .001$) and the increment was similar through all 3 treatment groups ($p = .479$). No differences in PES or WES index were found at any time points ($p > W.05$).

3.3 | Esthetic scores

Table 2 shows the mean PES and WES scores for the CM, PG and control groups. There were no significant differences between the groups ($p = .837$) at any time points ($p = .479$). From baseline to FU-1, the PES scores improved significantly ($p < .001$). The magnitude of this improvement was similar through all groups ($p = .479$). At FU-1, PES scores amounted to 7.0 ± 1.4 in CM group, 7.1 ± 1.5 in PG group and 7.3 ± 1.7 in control group. Four patients in the CM group, 6 patients in the PG group and 5 patients in the control group scored lower than 6 points for the soft tissue esthetics.

3.4 | Complications, implant survival and success

During the healing period, two patients in the CM group developed a cervical fistula without suppuration after placement of the crown at the referring dental office. These patients reported no subjective complaints nor any other signs of infection. Both sites were treated conservatively by flushing the fistula using a syringe with chlorhexidine 0.12%. As this did not resolve the fistula, the area was surgically explored; however, no more abnormalities were seen. The fistulas disappeared spontaneously, but at FU-1, a new fistula was seen in one of the patients. As this patient did not report any subjective complaints or showed signs of infection, the situation was monitored.

The implant survival rates were similar across the groups amounting to 100% in the CM and PG groups and to 95.7% in the control

group ($p = .657$) at FU-1. Only one patient in the control group had an early failure.

Implant success amounted to 95.7% in the CM group, 87.5% in the PG group and 91.4% for the control group at FU-1, without significant differences between the groups ($p = .865$). Two patients in PG presented one site with PD = 5 mm with BOP. One patient in the PG group and one patient in the control group presented one site with PD > 5 mm.

3.5 | The plaque, bleeding, gingiva index and the pocket probing depth

During the FU-1, PI, mBI, GI and the PD did not differ between treatment groups at any time points ($p > .05$) (Table 3). PD changed significantly over time ($p = .019$), and the changes were similar through all 3 treatment groups ($p = .353$). The mean PD values amounted 2.7 ± 0.6 mm in the CM group, 3.0 ± 0.7 mm in the PG group and 2.5 ± 0.8 for the control group at FU-1. The median values of mBI and PI amounted to 0 in all groups during the follow-up. Four patients showed mild inflammation (GI = 1), and two showed moderate inflammation (GI = 2) at FU-1.

3.6 | Patient-reported outcome measures (PROMs)

In general, PROMS were similar between the groups, with no significant differences at any time points ($p > .05$) (Table 4). Patients in the

TABLE 3 Periodontal clinical parameters at baseline (BL), 6-month (FU-6m) and one-year (FU-1) follow-up

	CM	PG	Control	p-value (Treatment effect)	p-value (Interaction effect)	p-value (Time effect)
PI						
BL	19/2/0/0	15/1/1/1	18/0/1/0	.464	.725	.995
FU-6m	18/4/0/0	16/2/0/1	19/0/1/0			
FU-1	21/0/1/0	21/1/1/1	21/0/1/0			
mB						
BL	15/4/2/0	13/5/0/0	15/4/0/0	.756	.833	.698
FU-6m	16/5/1/0	12/7/0/0	14/5/1/0			
FU-1	15/8/0/0	16/6/2/0	18/3/1/0			
GI						
BL	20/0/1/0	17/1/0/0	17/2/0/0	.849	.667	.464
FU-6m	21/0/1/0	18/1/0/0	18/2/0/0			
FU-1	21/0/2/0	21/3/0/0	21/1/0/0			
PD						
BL	2.7 ± 0.9	2.7 ± 0.7	2.4 ± 0.7	.092	.353	.019
FU-6m	3.1 ± 1.0	3.0 ± 0.6	2.6 ± 0.8			
FU-1	2.7 ± 0.6	3.0 ± 0.7	2.5 ± 0.8			

Note: Frequencies of the actual values (0/1/2/3) of the PI, BI and GI and mean ± SD of PD. Changes over time and differences between the treatment groups were assessed using generalized estimation equations (GEE). Wald's chi-square statistic was used to conclude about main effects and interactions. No differences in PI, mBI and GI were found at any time points ($p > .05$). PD changed significantly over time ($p = .019$), and the changes were similar through all 3 treatment groups ($p = .353$).

Abbreviations: CM, collagen matrix group; mBI, modified bleeding index; PD, probing depth; PG, palatal graft group; PI, Plaque Index.

PG group reported a higher swelling than the CM and control groups ($p = .038$). Patients were very satisfied with their implant crown and peri-implant soft tissues at all time points, with no significant differences between the groups ($p = .752$) (Table 4). The visual analogue score (VAS) for the satisfaction with the implant-supported crown amounted to 9.0 ± 1.2 (CM group), 8.8 ± 1.1 (PG group) and 9.1 ± 1.0 (control group) at FU-1. Similarly, VAS scores for the satisfaction with peri-implant soft tissues amounted to 8.0 ± 1.8 (CM group), 8.1 ± 1.7 (PG group) and 8.3 ± 1.5 (control group) at FU-1. Two patients in the CM group and two patients in the PG group experienced subjective complaints of the operated jaw (VAS >2) at FU-1. Only two patients in the CM group and one patient in the control group showed a score lower than 6 for peri-implant soft tissues satisfaction.

4 | DISCUSSION

The present RCT comparing early implant placement with and without ARP at one-year follow-up predominantly revealed: i. favorable and similar esthetic outcomes across the three treatment modalities, ii. comparable clinical outcomes between the two ARP groups and the control group and ii similar PROMs between the groups.

Supracrestal tissue height (mid-facial mucosal margin) changes were minimal and similar between the groups. The minimal changes indicate a stability of the buccal supracrestal tissue height when early implant placement is applied, which is consistent with previous

clinical data (Arora & Ivanovski, 2018; Belser et al., 2009; Lim et al., 2020). This stability might also be attributed to the performance of simultaneous GBR at implant placement, which was performed whenever a thin peri-implant buccal bone thickness (<2 mm) was found. Clinical studies (Grunder et al., 2005) and systematic reviews (Aizcorbe-Vicente et al., 2020) have recommended a minimum bone thickness of 2 mm to avoid vertical soft tissue changes. Interestingly, there was some supracrestal tissue height gain. One might speculate that a soft tissue graft and the soft tissue thickening induced by spontaneous healing in the control group may have stimulated a gain in the mid-facial mucosal margin (Chappuis et al., 2017; Clementini et al., 2020; Song et al., 2020). Even though these findings were positive, it should be emphasized that mid-facial mucosal margin changes have been assessed using different methods, thus undermining the comparison between studies (Graziani et al., 2019).

Esthetic outcomes including the peri-implant soft tissue conditions were similar between the two ARP groups and the control group, with no significant differences at any time points. The PES values were relatively within the range of the few available clinical studies on early implant placement after ARP. A recent RCT compared early implant placement versus late implant placement after ARP in periodontally compromised non-molar extraction sites (Lim et al., 2020). In that study, the median PES scores in the early implant placement group amounted to 5 at one year of loading (Lim et al., 2020). Those lower PES scores compared with the present findings are most likely explained by the lack of papillary tissues observed in that study resulting in decreased PES

TABLE 4 Patient-reported outcome measures (PROMS) of the treatment groups at baseline (BL), 6-month (FU-6m) and one-year (FU-1) follow-up

	CM	PG	Control	p-value (Treatment effect)	p-value (Interaction effect)	p-value (Time effect)
VAS: General satisfaction with dentition						
BL	8.1 ± 1.1	8.1 ± 2.3	8.3 ± 1.3	.753	.315	.348
FU-6m	7.8 ± 1.3	8.4 ± 1.9	8.4 ± 1.0			
FU-1	7.9 ± 1.4	8.0 ± 2.1	7.9 ± 1.4			
VAS: Impact of surgery						
BL	4.0 ± 2.5	4.8 ± 3.1	4.0 ± 2.2	.365	.514	.601
FU-6m	4.5 ± 2.7	5.2 ± 2.7	3.9 ± 2.2			
FU-1	3.9 ± 2.8	5.0 ± 2.8	4.7 ± 2.7			
VAS: Pain in the operated jaw						
BL	0.1 ± 0.3	0.9 ± 2.2	0.5 ± 1.5	.311	.776	.579
FU-6m	0.4 ± 1.7	0.9 ± 2.2	0.3 ± 1.3			
FU-1	0.2 ± 1.4	0.4 ± 1.0	0.2 ± 1.3			
VAS: Swelling in the surgical area						
BL	0 ± 0	0.7 ± 2.1	0.1 ± 0.3	.038	.146	.49
FU-6m	0.5 ± 1.8	0.7 ± 2.0	0.0 ± 0.2			
FU-1	0.4 ± 1.4	0.4 ± 1.1	0 ± 0			
VAS: Satisfaction with the implant-supported crown						
BL	9.1 ± 0.9	8.6 ± 2.4	9.1 ± 1.2	.752	.909	.978
FU-6m	9.0 ± 0.9	8.9 ± 1.6	9.0 ± 1.4			
FU-1	9.0 ± 1.2	8.8 ± 1.1	9.1 ± 1.0			
VAS: Satisfaction with the peri-implant soft tissues						
BL	8.1 ± 2.1	8.1 ± 2.4	8.5 ± 1.8	.785	.918	.994
FU-6m	8.1 ± 2.0	8.4 ± 1.5	8.3 ± 2.1			
FU-1	8.0 ± 1.8	8.1 ± 1.7	8.3 ± 1.5			

Note: Mean ± SD of PROMS using a visual analogue scale (VAS) from 0 to 10. Changes over time and differences between the treatment groups were assessed using generalized estimation equations (GEE). Wald's chi-square statistic was used to conclude about main effects and interactions. PG group showed significantly more swelling according to the VAS scale. No other significant differences in PROMS were found at any time points ($p > .05$).

Abbreviations: CM, collagen matrix group; PG, palatal graft group.

scores. In contrast, a recent case series applying early implant placement in 10 patients after ARP revealed a median PES score of 10 at one-year follow-up (Chen & Darby, 2020). Moreover, outcomes from a prospective study also revealed higher PES scores (Arora & Ivanovski, 2018). In that latter study, where early and immediate implant placement were compared, mean PES scores amounted to 9.3 in the early implant placement group at one year of loading (Arora & Ivanovski, 2018). The higher PES scores observed in these two studies as compared with the present values could be attributed to methodological differences in the PES evaluation. The present study applied the modified PES evaluation using a scale from 0 to 10 (Belser et al., 2009) whereas the other two studies (Arora & Ivanovski, 2018; Chen & Darby, 2020) applied the original PES evaluation score using a scale from 0 to 14, thereby increasing the PES scores (Furhauser et al., 2005).

The implant survival rates were similar across the groups amounting to 100% in the CM and PG groups, and to 95.6% in the control group. These survival rates are in line with earlier studies

where implants were placed following ARP (Cardaropoli et al., 2012, 2014, 2015; Kotsakis et al., 2014; Lim et al., 2020; Pang et al., 2014).

Periodontal parameters compatible with peri-implant health were observed across the groups up to one year after loading. This was indicated by the mean PD values around 3 mm, with no significant differences between the groups. The healthy conditions of the peri-implant tissues were further supported by the median values of mBI and PI which amounted to 0 in all groups. These findings are largely in agreement with previous reports (Cardaropoli et al., 2012, 2014, 2015; Cosyn et al., 2015; Lim et al., 2020).

PROMs revealed high levels of satisfaction in all groups without significant differences. These positive levels of satisfaction are consistent with a recent clinical report where early implant placement was applied (Arora & Ivanovski, 2018). In that study, the authors reported mean values of about 9 points at the different parameters using a VAS. Those values compare well with the present results. It should be noted, however, that clinical data about PROMs in ARP and early implant

placement are scarce, thus limiting the comparison with previous studies (Graziani et al., 2019). With respect to the patient's discomfort, there were no marked differences between the groups. Nonetheless, patients reported significantly more discomfort in the PG group. This observation was not unexpected as the PG group required a donor site for the harvesting of the autogenous soft tissue graft, which can be a painful procedure, particularly during the first days after surgery. (Burkhardt et al., 2015; Thoma et al., 2012). These drawbacks, nevertheless, can be easily overcome by using a collagen matrix (Thoma et al., 2020), thereby replacing an autogenous soft tissue graft without clinical disadvantages. The latter is supported by a recent systematic review revealing that no specific ARP procedure is superior (Avila-Ortiz et al., 2019).

The present findings indicate that early implant placement is optimal for short-term esthetic outcomes. Interestingly, these positive outcomes were also obtained without ARP, supporting the notion that when a failing tooth can be replaced with an implant within 2 months after tooth extraction, the added value of ARP might be clinically negligible (Jung et al., 2018). These observations might be related to the fact that 72% of the patients from the control group required simultaneous GBR at implant placement (Jonker et al., 2020) as opposed to the patients of the CM and PG groups who required significantly less GBR at implant placement ($p < .05$)—32% of the patients in the CM group and 24% in the PG group (Jonker et al., 2020). Another explanation for the lack of differences between the groups might be the shorter healing period (2 months) after ARP. ARP procedures traditionally involve a healing period of 4–6 months (Avila-Ortiz et al., 2019), and a shorter healing period may be insufficient for proper graft consolidation (Nelson & Mealey, 2020; Whetman & Mealey, 2016), thus weakening the added benefit of ARP. Notwithstanding, there has been an emerging clinical and research interest to reduce the healing period following ARP (Chen & Darby, 2020; Jonker et al., 2020; Lim et al., 2020; Thoma et al., 2020).

The present study has a number of limitations. A healing period of 8 weeks after ARP might be insufficient for proper graft consolidation, thereby hampering the possible added benefit of ARP (Nelson & Mealey, 2020; Whetman & Mealey, 2016). In terms of PROMs, the generalization of the present findings cannot be broadly generalized, since these types of outcomes have been commonly neglected (Graziani et al., 2019). Given the mucosal scarring that may occur at 5 years following implant placement with ARP (Wessels et al., 2020), the stability of the supracrestal tissue height and the lack of differences across the groups should be interpreted with caution. Finally, the keratinized mucosa width was not measured, thereby limiting the interpretations of the present findings.

Together with consideration of cost and patient preference, these findings can assist clinicians in the decision-making process in daily practice. Future multicenter RCTs are warranted to confirm and generalize the present observations.

5 | CONCLUSION

Early implant placement with ARP using demineralized bovine bone mineral with 10% collagen covered by either a collagen matrix or

a palatal graft rendered similar clinical, esthetics and PROMs compared to early implant placement without ARP after one year of loading.

CONFLICT OF INTEREST

All authors declare to have no conflict of interest.

AUTHOR CONTRIBUTIONS

Brend P. Jonker: Data curation (equal); Formal analysis (equal); Investigation (equal); Visualization (equal); Writing-original draft (equal). **Franz J. Strauss:** Formal analysis (equal); Investigation (equal); Software (equal); Visualization (equal); Writing-original draft (equal). **Nadja Naenni:** Conceptualization (equal); Investigation (equal); Supervision (equal); Writing-review & editing (equal). **Ronald E. Jung:** Conceptualization (equal); Supervision (equal); Writing-review & editing (equal). **Eppo B. Wolvius:** Funding acquisition (equal); Supervision (equal); Writing-review & editing (equal). **Justin Pijpe:** Conceptualization (equal); Funding acquisition (equal); Investigation (equal); Supervision (equal); Writing-original draft (equal).

ORCID

Brend P. Jonker  <https://orcid.org/0000-0003-0100-3871>

Franz J. Strauss  <https://orcid.org/0000-0002-5832-7327>

Ronald E. Jung  <https://orcid.org/0000-0003-2055-1320>

REFERENCES

- Aizcorbe-Vicente, J., Penarrocha-Oltra, D., Canullo, L., Soto-Penalzo, D., & Penarrocha-Diago, M. (2020). Influence of facial bone thickness after implant placement into the healed ridges on the remodeled facial bone and considering soft tissue recession: A systematic review. *International Journal of Oral and Maxillofacial Implants*, 35(1), 107–119. <https://doi.org/10.11607/jomi.7259>
- Arora, H., & Ivanovski, S. (2018). Immediate and early implant placement in single-tooth gaps in the anterior maxilla: A prospective study on ridge dimensional, clinical, and aesthetic changes. *Clinical Oral Implants Research*, 29(11), 1143–1154. <https://doi.org/10.1111/clr.13378>
- Avila-Ortiz, G., Chambrone, L., & Vignoletti, F. (2019). Effect of alveolar ridge preservation interventions following tooth extraction: A systematic review and meta-analysis. *Journal of Clinical Periodontology*, 46(Suppl 21), 195–223. <https://doi.org/10.1111/jcpe.13057>
- Belser, U. C., Grutter, L., Vailati, F., Bornstein, M. M., Weber, H. P., & Buser, D. (2009). Outcome evaluation of early placed maxillary anterior single-tooth implants using objective esthetic criteria: A cross-sectional, retrospective study in 45 patients with a 2- to 4-year follow-up using pink and white esthetic scores. *Journal of Periodontology*, 80(1), 140–151. <https://doi.org/10.1902/jop.2009.080435>
- Bienz, S. P., Sailer, I., Sanz-Martin, I., Jung, R. E., Hammerle, C. H., & Thoma, D. S. (2017). Volumetric changes at pontic sites with or without soft tissue grafting: A controlled clinical study with a 10-year follow-up. *Journal of Clinical Periodontology*, 44(2), 178–184. <https://doi.org/10.1111/jcpe.12651>
- Burkhardt, R., Hämmerle, C. H. F., & Lang, N. P., Research Group on Oral Soft Tissue Biology and Wound Healing. (2015). Self-reported pain perception of patients after mucosal graft harvesting in the palatal area. *Journal of Clinical Periodontology*, 42(3), 281–287. <https://doi.org/10.1111/jcpe.12357>
- Buser, D., Halbritter, S., Hart, C., Bornstein, M. M., Grutter, L., Chappuis, V., & Belser, U. C. (2009). Early implant placement with simultaneous

- guided bone regeneration following single-tooth extraction in the esthetic zone: 12-month results of a prospective study with 20 consecutive patients. *Journal of Periodontology*, 80(1), 152–162. <https://doi.org/10.1902/jop.2009.080360>
- Cardaropoli, D., Tamagnone, L., Roffredo, A., & Gaviglio, L. (2014). Relationship between the buccal bone plate thickness and the healing of postextraction sockets with/without ridge preservation. *International Journal of Periodontics and Restorative Dentistry*, 34(2), 211–217. <https://doi.org/10.11607/prd.1885>
- Cardaropoli, D., Tamagnone, L., Roffredo, A., & Gaviglio, L. (2015). Evaluation of dental implants placed in preserved and nonpreserved postextraction ridges: A 12-month postloading study. *International Journal of Periodontics and Restorative Dentistry*, 35(5), 677–685. <https://doi.org/10.11607/prd.2309>
- Cardaropoli, D., Tamagnone, L., Roffredo, A., Gaviglio, L., & Cardaropoli, G. (2012). Socket preservation using bovine bone mineral and collagen membrane: A randomized controlled clinical trial with histologic analysis. *International Journal of Periodontics and Restorative Dentistry*, 32(4), 421–430.
- Chappuis, V., Araújo, M. G., & Buser, D. (2017). Clinical relevance of dimensional bone and soft tissue alterations post-extraction in esthetic sites. *Periodontology* 2000, 73(1), 73–83
- Chen, S. T., & Darby, I. (2020). Alveolar ridge preservation and early implant placement at maxillary central incisor sites: A prospective case series study. *Clinical Oral Implants Research*, 31(9), 803–813. <https://doi.org/10.1111/clr.13619>
- Clementini, M., Castelluzzo, W., Ciaravino, V., Agostinelli, A., Vignoletti, F., Ambrosi, A., & De Sanctis, M. (2020). The effect of immediate implant placement on alveolar ridge preservation compared to spontaneous healing after tooth extraction: Soft tissue findings from a randomized controlled clinical trial. *Journal of Clinical Periodontology*, 47(12), 1536–1546. <https://doi.org/10.1111/jcpe.13369>
- Cosyn, J., Pollaris, L., Van der Linden, F., & De Bruyn, H. (2015). Minimally Invasive Single Implant Treatment (M.I.S.I.T.) based on ridge preservation and contour augmentation in patients with a high aesthetic risk profile: One-year results. *Journal of Clinical Periodontology*, 42(4), 398–405. <https://doi.org/10.1111/jcpe.12384>
- Couso-Queiruga, E., Stuhr, S., Tattan, M., Chambrone, L., & Avila-Ortiz, G. (2020). Post-extraction dimensional changes: A systematic review and meta-analysis. *Journal of Clinical Periodontology*, 48(1), 127–145. <https://doi.org/10.1111/jcpe.13390>
- Furhauser, R., Florescu, D., Benesch, T., Haas, R., Mailath, G., & Watzek, G. (2005). Evaluation of soft tissue around single-tooth implant crowns: The pink esthetic score. *Clinical Oral Implants Research*, 16(6), 639–644. <https://doi.org/10.1111/j.1600-0501.2005.01193.x>
- Fürhauser, R., Florescu, D., Benesch, T., Haas, R., Mailath, G., & Watzek, G. (2005). Evaluation of soft tissue around single-tooth implant crowns: The pink esthetic score. *Clinical Oral Implants Research*, 16, 639–644. <https://doi.org/10.1111/j.1600-0501.2005.01193.x>
- Graziani, F., Chappuis, V., Molina, A., Lazarin, R., Schmid, E., Chen, S., & Salvi, G. E. (2019). Effectiveness and clinical performance of early implant placement for the replacement of single teeth in anterior areas: A systematic review. *Journal of Clinical Periodontology*, 46(Suppl 21), 242–256. <https://doi.org/10.1111/jcpe.13092>
- Grunder, U. (2000). Stability of the mucosal topography around single-tooth implants and adjacent teeth: 1-year results. *International Journal of Periodontics and Restorative Dentistry*, 20(1), 11–17.
- Grunder, U., Gracis, S., & Capelli, M. (2005). Influence of the 3-D bone-to-implant relationship on esthetics. *International Journal of Periodontics and Restorative Dentistry*, 25(2), 113–119.
- Hammerle, C. H., Chen, S. T., & Wilson, T. G. Jr (2004). Consensus statements and recommended clinical procedures regarding the placement of implants in extraction sockets. *International Journal of Oral and Maxillofacial Implants*, 19(Suppl), 26–28.
- Jonker, B. P., Gil, A., Naenni, N., Jung, R. E., Wolvius, E. B., & Pijpe, J. (2020). Soft tissue contour and radiographic evaluation of ridge preservation in early implant placement: A randomized controlled clinical trial. *Clinical Oral Implants Research*, 32(1), 123–133. <https://doi.org/10.1111/clr.13686>
- Jonker, B. P., Gil, A., Naenni, N., Jung, R. E., Wolvius, E. B., & Pijpe, J. (2021). Soft tissue contour and radiographic evaluation of ridge preservation in early implant placement: A randomized controlled clinical trial. *Clinical Oral Implants Research*, 32(1), 123–133. <https://doi.org/10.1111/clr.13686>
- Jung, R. E., Ioannidis, A., Hammerle, C. H. F., & Thoma, D. S. (2018). Alveolar ridge preservation in the esthetic zone. *Periodontology* 2000, 77(1), 165–175. <https://doi.org/10.1111/prd.12209>
- Kotsakis, G. A., Salama, M., Chrepa, V., Hinrichs, J. E., & Gaillard, P. (2014). A randomized, blinded, controlled clinical study of particulate anorganic bovine bone mineral and calcium phosphosilicate putty bone substitutes for socket preservation. *International Journal of Oral and Maxillofacial Implants*, 29(1), 141–151. <https://doi.org/10.11607/jomi.3230>
- Lim, H. C., Seo, S., Thoma, D. S., Park, J. C., Hong, J. Y., & Shin, S. Y. (2020). Late implant placement following ridge preservation versus early implant placement: A pilot randomized clinical trial for periodontally compromised non-molar extraction sites. *Journal of Clinical Periodontology*, 47(2), 247–256. <https://doi.org/10.1111/jcpe.13223>
- Loe, H. (1967). The Gingival Index, the plaque index and the retention index systems. *Journal of Periodontology*, 38(6), 616. <https://doi.org/10.1902/jop.1967.38.6.610>
- MacBeth, N., Trullenque-Eriksson, A., Donos, N., & Mardas, N. (2017). Hard and soft tissue changes following alveolar ridge preservation: A systematic review. *Clinical Oral Implants Research*, 28(8), 982–1004. <https://doi.org/10.1111/clr.12911>
- Moher, D., Hopewell, S., Schulz, K. F., Montori, V., Gotzsche, P. C., Devereaux, P. J., Elbourne, D., Egger, M., & Altman, D. G. (2010). CONSORT 2010 explanation and elaboration: Updated guidelines for reporting parallel group randomised trials. *British Medical Journal*, 340, c869. <https://doi.org/10.1136/bmj.c869>
- Mombelli, A., van Oosten, M. A., Schurch, E. Jr, & Land, N. P. (1987). The microbiota associated with successful or failing osseointegrated titanium implants. *Oral Microbiology and Immunology*, 2(4), 145–151. <https://doi.org/10.1111/j.1399-302x.1987.tb00298.x>
- Monje, A., Chappuis, V., Monje, F., Munoz, F., Wang, H. L., Urban, I. A., & Buser, D. (2019). The critical peri-implant buccal bone wall thickness revisited: An experimental study in the beagle dog. *International Journal of Oral and Maxillofacial Implants*, 34(6), 1328–1336. <https://doi.org/10.11607/jomi.7657>
- Nelson, A. C., & Mealey, B. L. (2020). A randomized controlled trial on the impact of healing time on wound healing following ridge preservation using a 70%/30% combination of mineralized and demineralized freeze-dried bone allograft. *Journal of Periodontology*, 91(10), 1256–1263. <https://doi.org/10.1002/JPER.19-0610>
- Pang, C., Ding, Y., Zhou, H., Qin, R., Hou, R., Zhang, G., & Hu, K. (2014). Alveolar ridge preservation with deproteinized bovine bone graft and collagen membrane and delayed implants. *Journal of Craniofacial Surgery*, 25(5), 1698–1702. <https://doi.org/10.1097/SCS.0000000000000887>
- Pirc, M., Harbeck, O., Sapata, V. M., Husler, J., Jung, R. E., Hammerle, C. H. F., & Thoma, D. S. (2020). Contour changes of peri-implant tissues are minimal and similar for a one- and a two-piece implant system over 12 years. *Clinical Oral Investigations*, 25(2), 719–727. <https://doi.org/10.1007/s00784-020-03638-1>
- Romandini, M., De Tullio, I., Congedi, F., Kalemaj, Z., D'Ambrosio, M., Lafori, A., Quaranta, C., Buti, J., & Perfetti, G. (2019). Antibiotic prophylaxis at dental implant placement: Which is the best protocol? A systematic review and network meta-analysis. *Journal of Clinical Periodontology*, 46(3), 382–395. <https://doi.org/10.1111/jcpe.13080>

- Sanz, I., Garcia-Gargallo, M., Herrera, D., Martin, C., Figuero, E., & Sanz, M. (2012). Surgical protocols for early implant placement in post-extraction sockets: A systematic review. *Clinical Oral Implants Research*, 23, 67–79. <https://doi.org/10.1111/j.1600-0501.2011.02339.x>
- Sanz Martin, I., Benic, G. I., Hammerle, C. H., & Thoma, D. S. (2016). Prospective randomized controlled clinical study comparing two dental implant types: Volumetric soft tissue changes at 1 year of loading. *Clinical Oral Implants Research*, 27(4), 406–411. <https://doi.org/10.1111/clr.12579>
- Schropp, L., Wenzel, A., Kostopoulos, L., & Karring, T. (2003). Bone healing and soft tissue contour changes following single-tooth extraction: A clinical and radiographic 12-month prospective study. *International Journal of Periodontics and Restorative Dentistry*, 23(4), 313–323.
- Song, Y. W., Yoon, S. W., Cha, J. K., Jung, U. W., Jung, R. E., & Thoma, D. S. (2020). Soft tissue dimensions following tooth extraction in the posterior maxilla: A randomized clinical trial comparing alveolar ridge preservation to spontaneous healing. *J Clin Med*, 9(8), 2583. <https://doi.org/10.3390/jcm9082583>
- Spray, J. R., Black, C. G., Morris, H. F., & Ochi, S. (2000). The influence of bone thickness on facial marginal bone response: Stage 1 placement through stage 2 uncovering. *Annals of Periodontology*, 5(1), 119–128. <https://doi.org/10.1902/annals.2000.5.1.119>
- Tan, W. L., Wong, T. L., Wong, M. C., & Lang, N. P. (2012). A systematic review of post-extraction alveolar hard and soft tissue dimensional changes in humans. *Clinical Oral Implants Research*, 23, 1–21. <https://doi.org/10.1111/j.1600-0501.2011.02375.x>
- Thoma, D. S., Bienz, S. P., Lim, H. C., Lee, W. Z., Hammerle, C. H. F., & Jung, R. E. (2020). Explorative randomized controlled study comparing soft tissue thickness, contour changes, and soft tissue handling of two ridge preservation techniques and spontaneous healing two months after tooth extraction. *Clinical Oral Implants Research*, 31(6), 565–574. <https://doi.org/10.1111/clr.13594>
- Thoma, D. S., Sancho-Puchades, M., Ettlin, D. A., Hammerle, C. H., & Jung, R. E. (2012). Impact of a collagen matrix on early healing, aesthetics and patient morbidity in oral mucosal wounds - a randomized study in humans. *Journal of Clinical Periodontology*, 39(2), 157–165. <https://doi.org/10.1111/j.1600-051X.2011.01823.x>
- Tonetti, M. S., Jung, R. E., Avila-Ortiz, G., Blanco, J., Cosyn, J., Fickl, S., Figuero, E., Goldstein, M., Graziani, F., Madianos, P., Molina, A., Nart, J., Salvi, G. E., Sanz-Martin, I., Thoma, D., Van Assche, N., & Vignoletti, F. (2019). Management of the extraction socket and timing of implant placement: Consensus report and clinical recommendations of group 3 of the XV European Workshop in Periodontology. *Journal of Clinical Periodontology*, 46(Suppl 21), 183–194. <https://doi.org/10.1111/jcpe.13131>
- Urbaniak, G. C., & Plous, S. (2013). *Research Randomizer (Version Version 4.0)*. <http://www.randomizer.org>
- Wessels, R., Vervaeke, S., Seyssens, L., Eghbali, A., & Cosyn, J. (2020). A 5-year cohort study on early implant placement with guided bone regeneration or alveolar ridge preservation with connective tissue graft. *Clinical Implant Dentistry and Related Research*, 22(6), 697–705. <https://doi.org/10.1111/cid.12948>
- Whetman, J., & Mealey, B. L. (2016). Effect of healing time on new bone formation after tooth extraction and ridge preservation with demineralized freeze-dried bone allograft: A randomized controlled clinical trial. *Journal of Periodontology*, 87(9), 1022–1029. <https://doi.org/10.1902/jop.2016.160139>

SUPPORTING INFORMATION

Additional supporting information may be found online in the Supporting Information section.

How to cite this article: Jonker, B. P., Strauss, F. J., Naenni, N., Jung, R. E., Wolvius, E. B., & Pijpe, J. (2021). Early implant placement with or without alveolar ridge preservation in single tooth gaps renders similar esthetic, clinical and patient-reported outcome measures: One-year results of a randomized clinical trial. *Clinical Oral Implants Research*, 32, 1041–1051. <https://doi.org/10.1111/clr.13796>