

A comparison of the head and cervical posture between the self-balanced position and the Frankfurt method

S. ARMIJO-OLIVO*, X. JARA[†], N. CASTILLO[†], L. ALFONSO[†], A. SCHILLING[‡], E. VALENZUELA[‡], R. FRUGONE[§] & D. MAGEE[¶]
**Faculty of Rehabilitation Medicine, University of Alberta, Edmonton, Canada, [†]Physical Therapy Department, University Catholic of Maule, Chile, [‡]Health Faculty, Dentistry School, University of Talca, Chile, [§]Dentistry School, University of Chile, Chile and [¶]Physical Therapy Department, Faculty of Rehabilitation Medicine, University of Alberta, Edmonton, Canada*

SUMMARY Head and cervical posture evaluation has been a concern for many years, not only because of the purported relationship that exists between head and cervical posture in the presence of temporomandibular disorders, neck pain and headache, but also because of the biomechanical relationship between the head and cervical spine and dentofacial structures. Many methods have been suggested in an attempt to establish the best way to evaluate the position of the head using teleradiographs and cephalometric analysis. However, there is still no agreement as to which procedure is the best. The objective of this study was to evaluate the differences that exist between craniocervical measurements in lateral teleradiographs when comparing the position of the head in the self-balanced position to the position of the head using the Frankfurt method (Frankfurt plane parallel to the floor).

Sixty-eight subjects who sought dental treatment in community health centres in Talca, Chile participated in this study. Rocabado analysis was used to measure the craniocervical variables. The Cobb analysis was used to measure cervical lordosis. A paired student *t*-test was used to evaluate the differences between both procedures, using an α of 0.05 and a power of 0.90. The use of the cephalostat changed only the craniocervical angle ($P < 0.001$). However, this change was minimal. No changes related to gender and age were found. More studies are needed to determine the variation between different procedures and to define a good procedure for evaluating head posture.

KEYWORDS: head posture, teleradiographs, cephalostat, craniocervical variables, cervical lordosis

Introduction

Posture is defined as 'the relationship between a segment or part of the body related to other adjacent segments, and the relationship between all the segments to the human body' (1). It is an indicator of biomechanical efficacy, equilibrium, and neuromuscular coordination (2). Human beings require a stable and balanced posture for proper human movement. The neuromuscular system is responsible for maintaining the posture of the body and allowing movement to occur. Many factors control

the craniocervical posture, including the vestibular and visual apparatus, the proprioceptors of the neck, the hyoid position, and neuromuscular activity (3–5).

Head and cervical posture evaluation has been a concern for many years, not only because of the supposed relationship that exists between head and cervical posture with temporomandibular disorders (6–19), neck pain and headache (20), but also because of the biomechanical relationship between the position of the head and cervical spine and dentofacial structures (21–31).

Many procedures exist for measuring head posture, but there are three that are most popular. One procedure involves a clinical evaluation of posture, in which the evaluator observes and notes the position of the head and cervical spine with respect to the line of gravity and specific landmarks (2). A second method involves taking a lateral view photograph of the subject, and then taking measurements from the pictures using specific landmarks (8, 12, 13, 17). The final and most accurate method for measuring the head and cervical posture is the use of teleradiographs and cephalometric analysis (11, 32–40). Although this method is the most accurate, there is no agreement about a standardized method of positioning the head and neck for taking the teleradiographs in order to accurately evaluate the head position and the exact postural pattern of the patient (11, 18, 32–37, 39–42). The Frankfurt method consists of positioning the subject in the cephalostat with the Frankfurt plane [line from Porion to Orbitale (43)] parallel to the floor. The Frankfurt positioning method has been popular in clinical practice, even with the knowledge that what is measured is not the natural posture of the subject, because this method is more reproducible over time and provides a clearer view of the teleradiographs (37). Researchers have argued that the use of the cephalostat with positioning by the Frankfurt method enables better quality radiographs to be obtained as its use minimizes the projection error, and avoids head rotation in the vertical, anteroposterior and transversal axes (32, 44–46). Thus, the Frankfurt method makes the patient's head position reproducible over time, avoiding the overlapping of the images taken (37).

The self-balanced position is obtained when the subject is standing while maintaining a horizontal visual axis without any external intervention or modification of his/her posture (32, 47). The objective of this procedure is to obtain a posture of the head and cervical spine in the sagittal plane that is determined by the subject's own postural system. The natural head posture (NHP) with mirror [also called 'the mirror position' (38) is similar to the self balance position]. The only difference between the two is that subjects have to look into a mirror in front of them in order to maintain the horizontal visual axis for the mirror position. These methods (the self-balanced position and the NHP) supplement the conventional requirements for standardized cephalometric records using the Frankfurt method,

but do not replace it, as according to some authors (35, 37, 44) current methods of recording self balanced position and NHP are cumbersome and less reproducible than the Frankfurt method (37, 44). Nevertheless, Solow and Tallgren (38), reported that both the self balanced position and NHP methods can be reproduced without systematic error and with a low method error.

Lateral cephalograms and teleradiographs are elements of support in many disciplines that work in the craniocervical area. These techniques allow every patient to be evaluated for postural alterations in the sagittal plane in order to programme specific treatments. The Frankfurt method is more commonly used by clinicians who take teleradiographs to evaluate head posture in sagittal plane. However, it is believed that the Frankfurt method modifies the natural posture of the subject when teleradiographs are taken (33). The self balanced position and the 'mirror position' have been said to reproduce the natural postural pattern of the subject (32, 33, 38), however, because of their lack of reproducibility, they are not commonly used in the clinical practice. Therefore, it is necessary to determine if the teleradiograph using the Frankfurt method and the self-balanced position give the same or different information about head posture and craniocervical variables. Thus, the purpose of this research was to compare the following measurements: craniocervical angle [relation between the head and the cervical spine (head posture)]; cervical lordosis (measurement of cervical concavity); craniocervical spaces (distances between cranium–atlas and atlas–axis); and hyoid triangle (position of hyoid bone) when using the Frankfurt positioning method and the self-balanced position.

Materials and methods

Subjects

From a group of patients who sought dental treatment in a community health centre in Talca, Chile from 4 January to 4 February 1999, a sample of convenience of 68 patients, 39 female and 29 male subjects (aged 5–43 years, average: 14.26 years, s.d.: ± 9.1) who agreed to participate in this study, was obtained. Two teleradiographs were taken on each subject (136 in total). All teleradiographs were evaluated through cephalograms.

Sample size calculation was obtained using a paired *t*-test with a power of 0.90 at $\alpha = 0.05$, using the minimum value of 2.21 of difference between variables. Based on these criterion, approximately 50 patients were needed (48).

Inclusion criteria included the ability of subjects to maintain the standing position (i.e. no vestibular and/or equilibrium problems). Subjects with mental, cognitive, or physical incapacities, and face or spinal abnormalities such as torticollis, scoliosis, kyphosis were excluded.

All subjects who wanted to participate met the inclusion criteria and were informed of the nature of the study, and provided informed consent. The study was approved by the Ethics Committee of the Catholic University of Maule – Chile.

Variables

For this study, the independent variable was the use of a cephalostat to take the teleradiographs and the dependent variables were craniocervical angle (CCA), Cobb angle, cranium–atlas (C0–C1) distance, Atlas–axis (C1–C2) distance, and hyoid triangle [For details of method see Rocabado (5)]. For variables details, see Table 1.

Protocol for head posture

The first teleradiograph was taken with the head in the self-balanced position (32, 47). The self-balanced position was obtained by having each subject standing with his/her visual axis horizontal with no external intervention or modification of his/her posture (32, 47). The objective of this procedure was to obtain a posture of the head and cervical spine in the sagittal plane that is determined by the subject's own postural system. The subject was asked to be shoeless, in standing position, with the eyes looking forward and with the teeth in occlusion. It was necessary to describe the position of the feet as 'a comfortable distance apart and slightly diverging'. Each patient was asked to breath in deeply (inhale), and then exhale, a process which was repeated until the patient felt comfortable and relaxed in an habitual posture (without any external intervention). The patient was asked to maintain this self-balanced position without correcting it, and after an exhalation the teleradiograph was taken.

The second teleradiograph was taken using the Frankfurt method (Frankfurt plane parallel to the floor) (37). The subject performed the same procedures as with the teleradiograph in the self-balanced position, described previously, however, the head was

Table 1. Variables description for cephalometric analysis

Variable	Definition	Measurement
Craniocervical angle	Is the posterior inferior angle comprised of the intersection of the odontoid plane (plane comprised of the union of the anterior inferior point of odontoid and the apex of the odontoid) and McGregor plane (plane comprised of the union of the posterior nasal process point to the base of the occiput) This angle measures the position of the head related to the cervical spine (27)	$101 \pm 5^\circ$
Cobb angle	Cobb angle measures the cervical lordosis. This angle is the result of the intersection of the two perpendicular lines. One perpendicular to the inferior end plate of C6 (sixth cervical vertebrae) and the other perpendicular to the inferior endplate of C2 (axis) (50, 51)	36°
C0–C1 distance	This measurement shows the perpendicular distance between occiput and posterior arch of the atlas. The landmarks for this measurement are the base of the occiput and the most superior and posterior point of the posterior arch of the atlas (27)	4–9 mm
C1–C2 distance	This measurement shows the perpendicular distance between the posterior arch of atlas and the spinous process of C2. The landmarks are the most inferior and posterior point of the posterior arch of the atlas and the most superior and posterior point of the spinous process of axis (27)	4–9 mm
Hyoid Triangle height	This measurement shows the position of the hyoid bone. The landmarks are the retrognation more posterior inferior point of the jaw symphysis), the more superior and anterior point of the hyoid, and the more inferior and anterior point of C3 (third cervical vertebrae). To measure this triangle one line is drawn from retrognation to C3; a second line from C3 to hyoid; and a third line from the hyoid to the retrognation. The height of this triangle is measured from its base to its apex (27)	4 ± 0.6 mm

positioned by the radiologist using the Frankfurt method.

Radiographic technique

All head films were taken using an Ortopanthomograph, Model Ortophos -3*. The film distance to the X-ray tube was fixed at 160 cm; the film distance to mid-sagittal plane of the patient's head was 18 cm. The resulting magnification was 10%. The films were exposed at 68–70 kV and 12 mAs, and a filter of 2.5 mm aluminium equivalent was used (49). For all subjects, 24 × 30 cm film[†] was used. All teleradiographs were taken by the same trained radiologist, under the same conditions for all subjects.

Head and cervical cephalometric analysis

The cephalometric analyses were performed by hand, according to the literature protocols (5, 50, 51). The cephalometric analysis as described by Rocabado (5) for measuring the CCA, cranium–atlas distance (C0–C1 distance), atlas–axis distance (C1–C2 distance), and hyoid triangle was used (Fig. 1). The Cobb angle for measuring the cervical lordosis (Fig. 1), as describe by Loder (51) and Boswell *et al.* (50) was used. Transparent paper, a 0.5 mm pencil, and a metallic ruler calibrated in millimetres were used to measure the distance between C0–C1, and C1–C2, and the hyoid triangle. A protractor was used to measure the CCA and the Cobb angle. The measurements were performed by the same evaluator, following the same procedure for all teleradiographs. To evaluate the reliability of the evaluator, 10 teleradiographs were chosen randomly to repeat the measurements (power = 0.90, $\alpha = 0.05$ using intra class correlation coefficient) (48).

Statistical analysis

A paired *t*-test was used to evaluate the differences between measurements for teleradiographs using the self balanced position and Frankfurt method. An intraclass correlation coefficient (ICC) was used to evaluate the intrarater reliability of the measurements.

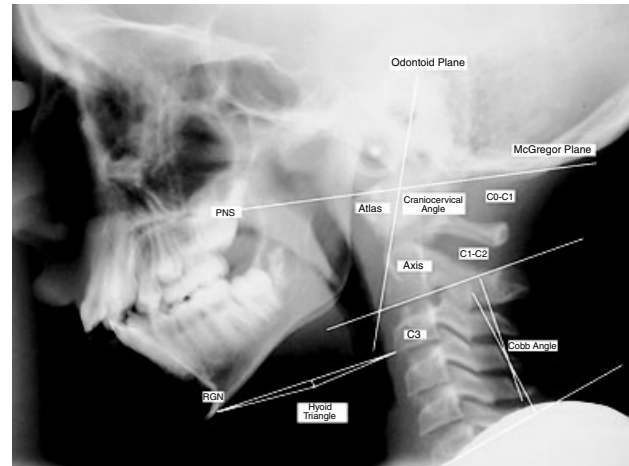


Fig. 1. Rocabado and Cobb analyses. PNS, posterior nasal spine; RGN, retrognathion; C3, third cervical vertebrae; CCA, craniocervical angle; 1, cranium–atlas distance; 2, atlas–axis distance.

The level of significance used was $\alpha = 0.05$. All data were analysed using SPSS version 11.0[‡].

Age and gender factor

According to some authors age and gender could have an effect on head and cervical posture (38). For this reason, data were analysed according to gender (female and male) and different age groups to see if any differences were found.

The age range for this study was 5–43 years. Extreme age range was determined as the highest or lowest age participating in this study. To ensure that younger and older ages did not influence the results, the analysis of all variables was performed considering all participants, and also when patients with at the extreme ages (5, 6, 7, 8, 9, 33, 37 and 43 years old) were not considered. Thus, statistical analysis was performed for every gender, with every age extreme eliminated, and with all participants.

Results

The reliability of the evaluator (intrarater reliability) for the different measurements was 0.98 for CCA, 0.98 for occipital–atlas distance, and 0.95 for the atlas–axis distance, 0.99 for the hyoid triangle, and 0.69 for the Cobb angle. Descriptive statistics for CCA, occipital–

*Siemens[®] AG, Munich, Germany.

[†]Kodak[®], Rochester, NY, USA.

[‡]SPSS Inc., Chicago, IL, USA.

atlas distance, atlas–axis distance, hyoid triangle, and Cobb angle for both procedures (self balanced-position and Frankfurt method) and also the results of the paired *t*-test analysis for the same variables can be found in Table 2.

The results showed that the occipital–atlas distance, atlas–axis distance, the hyoid triangle, and the Cobb angle were not statistically different ($P > 0.248$) for both head positioning procedures. However, the CCA did show a significant difference ($P < 0.001$), but this difference was clinically small.

When the data for women and men were analysed separately, there was no significant difference between the two groups for all measurements. When the age factor was analysed for all subjects and with extremes eliminated, no significant differences were found. Therefore, neither age nor sex affected the results of this current study.

Discussion

The objective of this study was to determine if there were any differences in some craniocervical variables when teleradiographs are taken in the sagittal plane using the Frankfurt positioning method and the self-balanced position. These results provide a basis to determine the accuracy of the Frankfurt method when evaluating the head posture and craniocervical variables, as the magnitude of the differences in CCA, head

posture, craniocervical spaces and cervical lordosis between the Frankfurt method and the self-balanced position have not been determined previously.

Our results showed that the only variable that significantly changed with both procedures was the CCA. This angle measures the relation between the head and the cervical spine. When the Frankfurt method was used, the position of the head in space changed slightly, altering the CCA. However, this change was so small as to be clinically insignificant. The remaining measurements (occipital–atlas distance, atlas–axis distance) followed a pattern towards posterior rotation of the head, which is in accordance with the variation of the CCA (5). These results indicate that there is a slightly tendency for posterior rotation of the head and a decrease of the cervical spine lordosis when positioning the head using the Frankfurt method. These results were also obtained by Ferrario *et al.* (36) who found that the position of the head using the Frankfurt method was more extended when compared with the NHP.

The results obtained in this study also are in agreement with those of Greenfield *et al.* (33), who studied 33 subjects with a different age ranges than the present study (22–40 years old). They also found a change in cervical inclination relative to the true horizontal (with ears rods) when comparing head posture with ear rods in and ear rods out. The angle between the cervical spine and the true horizontal tended to increase when

Table 2. Descriptive statistics and results of paired *t*-test analysis for all variables with both procedures (the self balanced position and the Frankfurt method)

Variables	Mean	Mean	s.d.	Paired differences		<i>t</i>	df	Significance	Units	<i>n</i>
				95% confidence interval of the difference						
				Upper	Lower					
Occipital–atlas distance with cephalostat	6.38	–0.20	1.547	–0.58	0.17	–1.09	67	0.280	mm	68
Occipital–atlas distance without cephalostat	6.59									
Atlas–axis distance with cephalostat	5.33	–0.16	1.417	–0.50	0.18	–0.94	67	0.350	mm	68
Atlas–axis distance without cephalostat	5.50									
Hyoid triangle with cephalostat	–0.29	0.00	2.596	–0.63	0.63	0.005	67	0.996	mm	68
Hyoid triangle without cephalostat	–0.29									
Craniocervical angle with cephalostat	101.11	–2.21	4.757	–3.36	–1.06	–3.83	67	0.000*	Degrees	68
Craniocervical angle without cephalostat	103.32									
Cobb angle with cephalostat	11.34	–1.08	7.621	–2.92	0.77	–1.16	67	0.248	Degrees	68
Cobb angle without cephalostat	12.42									

*Statistical significant $\alpha = 0.05$.

the ears rods were inserted into the external meatus, showing a straightening of the cervical spine (decrease in cervical lordosis). They also found that a consistent pattern of extension in the atlanto-occipital joints was seen when the ear rods were in place. The same result was found in the current study when using the Frankfurt method. The differences in the measurements for both methods in the Greenfield *et al.* study as well as in the present study were small. In the present study, only 2.21 degrees of difference between both procedures (the self balanced position and the Frankfurt method) for CCA and 1.53 degrees of difference between both procedures in the Greenfield *et al.* study for the angle of the inclination of the cervical spine to the true horizontal (CVT/HOR) were found. The remaining variables studied in the current study obtained small differences as well (occipital-atlas distance, 0.20°; atlas-axis, 0.16°; hyoid triangle, 0.00°; Cobb angle, 1.08°). All these values are too small to be clinically relevant as any treatment approach or any treatment decision making would not be based on the amount of change in these variables.

There were no differences between males and females in the analysed variables in the present study. However, these data differ with the results of Solow and Tallgren (38) who compared the self balance position with NHP. They found that boys tended to look up more in changing from the self balanced position to the mirror position when compared with girls. The explanation stated by the authors of this study was that the girls were encouraged socially to adopt a good upright posture and look straight ahead, and they adopted this posture even in the absence of any external eye reference. These results were also corroborated by Ferrario *et al.* (36) who found that males had a more extended position of the head than females.

Lundstrom and Lundstrom (37) investigated the variation of the Frankfurt line in two positions, NHP and natural head orientation [defined as the head position evaluated as 'natural' by observers experienced in such assessment (37)]. They demonstrated that the Frankfurt line had less variation in the natural head orientation than the NHP. Also, when subjects were positioned in the NHP and compared with this corrected position (natural head orientation), their heads had a tendency to be more flexed. These results are in agreement with our results because when subjects were in the self balanced position, they had a more

flexed head position when compared with the corrected position using the Frankfurt method in the current study.

Certainly, the Frankfurt method, as it is defined, creates a fixed position of the head, and probably cannot be used for longitudinal evaluations of the head position. Thus, a NHP assessment should be performed. According to Cooke and Wei (32), in order to allow reproducibility and good quality of the teleradiographs, the use of cephalostat and ear posts in NHP with mirror can reach both objectives as both positions (with and without cephalostat and ear rods) have no statistical differences and a good reproducibility.

All of the variables analysed in this study have not previously been analysed together in other studies, and similar studies have used different objectives and methodologies, making comparisons of the results more difficult (12, 18, 32, 34, 35, 40).

The sample used in this study was a convenience sample, but with an appropriate power (0.90). The age range was wide because the purpose of this study was to study the differences between the Frankfurt method and the self balance position regardless age. Even, when the age factor was analysed, taking out patients with age at the extreme (5, 6, 7, 8, 9, 33, 37 and 43 years old), the results did not change. Therefore, it was concluded that age did not influenced the measurements.

Intrarater measurement reliability was high except for the Cobb angle (ICC = 0.69). The Cobb angle has been noted to have more inter- and intra-variability in its measurements because the procedure lacks precision in the selection of the landmarks (52–54). However, at present, there is lack of well design methods to measure the cervical lordosis. Nevertheless, the remaining variables obtained a good reliability (ICC = 0.95–0.99), making the results consistent.

In summary, the hypothesis that the Frankfurt method significantly changes the head, cervical and craniocervical posture was not supported by the results of this study. The insertion of ear rods could by itself be argued as positioning the subject in an unnatural position, however, the results of this study failed to prove that this change was clinically significant. The small differences and the larger *P*-values for all of the variables measured are consistent with a small variation in the posture when the subject was positioned with cephalostat using the Frankfurt method.

Conclusion

Based on the results of this study, the following conclusions can be stated:

1. Overall, craniocervical variables and cervical lordosis were not significantly different when comparing the Frankfurt method and the self-balanced position. Therefore, the use of cephalostat did not significantly change the occiput-atlas distance, atlas-axis distance, cervical lordosis, or the hyoid position.
2. Only the CCA was significant different using the two procedures. However, this change was too small to be clinically significant. No gender and age related changes were found.

Acknowledgments

The authors would like to thank the dentists from the Community Health centers, Talca, Chile for helping with this project; to Martin Parfitt and Margie McNeely for their professional support; Silvia Ramos for helping us with technical support; and Dave Clyburn from Academic Support Center at the University of Alberta, and Dr Carlos Flores-Mir from the Faculty of Dentistry of the University of Alberta for their help in editing this article.

Susan Armijo-Olivo is supported by a Full-time Studentship from the Government of Chile.

References

1. Gonzalez HE, Manns A. Forward head posture: its structural and functional influence on the stomatognathic system, a conceptual study. *Cranio*. 1996;14:71–80.
2. Magee D. Assessment of posture. Orthopedic physical assessment, Chapter 15, 4th edn. St Louis: Elsevier Sciences; 2002:873–903.
3. White P, Panjabi M. Clinical biomechanics of the spine. In: White P, Panjabi M, eds. *Clinical Biomechanics of the Spine*. Philadelphia: Lippincott; 1990:1–25.
4. Kapandji I. Cervical spine. The physiology of the joints: annotated diagrams of the mechanics of the human joints, Chapter Three. Edinburgh (Scotland), New York: Churchill Livingstone; 1990.
5. Rocabado M. Biomechanical craniocervical analysis of lateral teleradiograph. *Revista Chilena de Ortodoncia*. 1984; 1:42–52.
6. Armijo S, Frugone R, Wahl F, Gaete J. Clinic and teleradiographic alterations in patients with anterior disc displacement with reduction. *Kinesiologia*. 2001;64:82–87.
7. D'Attilio M, Epifania E, Ciuffolo F et al. Cervical lordosis angle measured on lateral cephalograms; findings in skeletal class II female subjects with and without TMD: a cross sectional study. *Cranio*. 2004;22:27–44.
8. Lee WY, Okeson JP, Lindroth J. The relationship between forward head posture and temporomandibular disorders. *J Orofac Pain*. 1995;9:161–167.
9. Nicolakis P, Nicolakis M, Piehslinger E et al. Relationship between craniomandibular disorders and poor posture. *Cranio*. 2000;18:106–112.
10. Braun BL. Postural differences between asymptomatic men and women and craniofacial pain patients. *Arch Phys Med Rehabil*. 1991;72:653–656.
11. Solow B, Sandham A. Cranio-cervical posture: a factor in the development and function of the dentofacial structures. *Eur J Orthod*. 2002;24:447–456.
12. Visscher CM, De Boer W, Lobbezoo F, Habets LLMH, Naeije M. Is there a relationship between head posture and craniomandibular pain? *J Oral Rehabil*. 2002;29:1030–1036.
13. Chiao L, Guedes Z, Vieira M. Relationship between physical global posture and temporomandibular joint dysfunction: masticatory muscle overactivity. *Fisioterapia Brasil*. 2003;4:341–347.
14. Darlow LA, Pesco J, Greenberg MS. The relationship of posture to myofascial pain dysfunction syndrome. *J Am Dent Assoc*. 1987;114:73–75.
15. Fuentes R, Freesmeyer W, Henriquez J. Influence of body posture in the prevalence of craniomandibular dysfunction. *Revista Medica De Chile*. 1999;127:1079–1085.
16. Kritsineli M, Shim YS. Malocclusion, body posture, and temporomandibular disorder in children with primary and mixed dentition. *J Clin Pediatr Dent*. 1992;16:86–93.
17. Hackney J, Bade D, Clawson A. Relationship between forward head posture and diagnosed internal derangement of the temporomandibular joint. *J Orofac Pain*. 1993;7:386–390.
18. Sonnesen L, Bakke M, Solow B. Temporomandibular disorders in relation to craniofacial dimensions, head posture and bite force in children selected for orthodontic treatment. *Eur J Orthod*. 2001;23:179–192.
19. Huggare JA, Raustia AM. Head posture and cervicovertebral and craniofacial morphology in patients with craniomandibular dysfunction. *Cranio*. 1992;10:173–177.
20. Watson DH, Trott PH. Cervical headache: an investigation of natural head posture and upper cervical flexor muscle performance. *Cephalalgia*. 1993;13:272–284; discussion 232.
21. Gillies GT, Broaddus WC, Stenger JM, Taylor AG. A biomechanical model of the craniomandibular complex and cervical spine based on the inverted pendulum. *J Med Eng Technol*. 1998;22:263–269.
22. Gillies GT, Christy DW, Stenger JM, Broaddus WC. Equilibrium and non-equilibrium dynamics of the craniomandibular complex and cervical spine. *J Med Eng Technol*. 2003;27:32–40.
23. Makofsky H. The effect of head posture on muscle contact position: the sliding cranium theory. *Cranio*. 1989;7:286–292.
24. McLean LF, Brenman HS, Friedman MG. Effects of changing body position on dental occlusion. *J Dent Res*. 1970;52:1041–1045.

COMPARISON BETWEEN SELF-BALANCED POSITION AND FRANKFURT METHOD

25. Posselt U. Studies in the mobility of the human mandible. *Acta Odontol Scand Suppl.* 1952;10:1-153.
26. Rocabado M. Head and neck: biomechanics. In: Rocabado M, ed. *Head and neck: joint treatment.* Buenos Aires: Intermedica; 1979:1-71.
27. Rocabado M. Biomechanical relationship of the cranial, cervical, and hyoid regions. *Cranio.* 1983;1:61-66.
28. Yamabe Y, Yamashita R, Fujii H. Head, neck and trunk movements accompanying jaw tapping. *J Oral Rehabil.* 1999;26:900-905.
29. Yamada R, Ogawa T, Koyano K. The effect of head posture on direction and stability of mandibular closing movement. *J Oral Rehabil.* 1999;26:511-520.
30. Zuniga C, Miralles R, Mena B et al. Influence of variation in jaw posture on sternocleidomastoid and trapezius electromyographic activity. *Cranio.* 1995;13:157-162.
31. Solow B, Sandham A. Cranio-cervical posture: a factor in the development and function of the dentofacial structures. *Eur J Orthod.* 2002;24:447-456.
32. Cooke MS, Wei SH. The reproducibility of natural head posture: a methodological study. *Am J Orthod Dentofacial Orthop.* 1988;93:280-288.
33. Greenfield B, Kraus S, Lawrence E, Wolf SL. The influence of cephalostatic ear rods on the positions of the head and neck during postural recordings. *Am J Orthod Dentofacial Orthop.* 1989;95:312-318.
34. Cooke MS. Five-year reproducibility of natural head posture: a longitudinal study. *Am J Orthod Dentofacial Orthop.* 1990;97:489-494.
35. Lundstrom F, Lundstrom A. Natural head position as a basis for cephalometric analysis. *Am J Orthod Dentofacial Orthop.* 1992;101:244-247.
36. Ferrario VF, Sforza C, Germano D, Dalloca LL, Miani A Jr. Head posture and cephalometric analyses: an integrated photographic/radiographic technique. *Am J Orthod Dentofacial Orthop.* 1994;106:257-264.
37. Lundstrom A, Lundstrom F. The Frankfort horizontal as a basis for cephalometric analysis. *Am J Orthod Dentofacial Orthop.* 1995;107:537-540.
38. Solow B, Tallgren A. Natural head position in standing subjects. *Acta Odontol Scand.* 1971;29:591-607.
39. Solow B, Sonnesen L. Head posture and malocclusions. *Eur J Orthod.* 1998;20:685-693.
40. Peng L, Cooke MS. Fifteen-year reproducibility of natural head posture: a longitudinal study. *Am J Orthod Dentofacial Orthop.* 1999;116:82-85.
41. Usume S, Orhan M. Inclinator method for recording and transferring natural head position in cephalometrics. *Am J Orthod Dentofacial Orthop.* 2001;120:664-670.
42. Usume S, Orhan M. Reproducibility of natural head position measured with an inclinometer. *Am J Orthod Dentofacial Orthop.* 2003;123:451-454.
43. Lundstrom A, Lundstrom F, Le Bret LM, Moorrees CF. Natural head position and natural head orientation: basic considerations in cephalometric analysis and research. *Eur J Orthod.* 1995;17:111-120.
44. Raju NS, Prasad KG, Jayade VP. A modified approach for obtaining cephalograms in the natural head position. *J Orthod.* 2001;28:25-28.
45. Tng TT, Chan TC, Cooke MS, Hagg U. Effect of head posture on cephalometric sagittal angular measures. *Am J Orthod Dentofacial Orthop.* 1993;104:337-341.
46. Rojas I, Zuniga A, Aravena P, Glaria I. Assessment of a new method to study the natural posture of the head. *Revista Chilena de Ortodoncia.* 1996;13:106-115.
47. Sandoval P, Henriquez J, Fuentes R, Cabezas G, Roldan R. Cervical Curve: Cephalometric study in rest clinical position. *Revista Medica de Chile.* 1999;127:547-555.
48. Portney L, Watkins M. Power and sample size. In: Mehalik C, ed. *Foundations of clinical research.* New Jersey: Prentice Hall Health; 2000:705-730.
49. White SC, Heslop EW, Hollender LG, Mosier KM, Ruprecht A, ShROUT MK. Parameters of radiologic care: an official report of the American Academy of Oral and Maxillofacial Radiology. *Oral Surg Oral Med Oral Pathol Oral Radiol Endod.* 2001;91:498-511.
50. Boswell HB, Dietrich A, Shiels WE et al. Accuracy of visual determination of neutral position of the immobilized pediatric cervical spine. *Pediatr Emerg Care.* 2001;17:10-14.
51. Loder RT. The sagittal profile of the cervical and lumbosacral spine in Scheuermann thoracic kyphosis. *J Spinal Disord.* 2001;14:226-231.
52. Shea KG, Stevens PM, Nelson M, Smith JT, Masters KS, Yandow S. A comparison of manual versus computer-assisted radiographic measurement. Intraobserver measurement variability for Cobb angles. *Spine.* 1998;23:551-555.
53. Pruijs JE, Hageman MA, Keessen W, van der Meer R, van Wieringen JC. Variation in Cobb angle measurements in scoliosis. *Skeletal Radiol.* 1994;23:517-520.
54. Morrissy RT, Goldsmith GS, Hall EC, Kehl D, Cowie GH. Measurement of the Cobb angle on radiographs of patients who have scoliosis. Evaluation of intrinsic error. *J Bone Joint Surg Am.* 1990;72:320-327.

Correspondence: Susan Armijo-Olivo, Faculty of Rehabilitation Medicine, University of Alberta, Corbett Hall 2-50, T6G 2G4, Edmonton, Canada.
E-mail: sla4@ualberta.ca