

Spontaneous regeneration after juvenile ossifying fibroma resection: a case report

Sebastián A. Espinosa, DDS,^a Julio Villanueva, DDS, MS,^b Hans Hampel, DDS, MS,^a and Daniel Reyes, DDS,^a Santiago, Chile
UNIVERSITY OF CHILE

A case of unusual bone regeneration after resection of a juvenile ossifying fibroma (JOF) is presented. Secondary mandibular reconstruction with autogenous grafts was delayed due to the rapid bone formation. To the best of our knowledge there are no reports of this unusual response following JOF resection. (*Oral Surg Oral Med Oral Pathol Oral Radiol Endod* 2006;102:e32-e35)

Juvenile ossifying fibroma (JOF), has been distinguished from the rest of ossifying fibromas by the age in which it appears (younger than 15 years old), the zone that is involved, and its clinical behavior.¹ The tumor is normally asymptomatic, reaching a great size and being locally aggressive. It has been described in maxillary bones, paranasal sinuses, orbits, and the frontoethmoidal complex. It is thought that this tumor develops in the jaw from undifferentiated cells of the periodontal ligament in the premolar and molar regions.² It is often a radiographic finding, although it is commonly discovered by the expansion of cortical bones.³ Radiographically, it appears as circumscribed radiolucent areas that in some cases display central radioopacities.³

The associated complications are related to the compromise of the anatomical structures as a result of their growth. It is a nonencapsulated neoplasm, but well delimited by the adjacent bone. The differential diagnosis with other fibro-bony lesions are mainly determined by the characteristics of the calcified tissues.²

The gold standard treatment is, according to many authors, curettage of the injury. For recurrences, accelerated growth, and lack of delimitation between the lesion and the surrounding bone, resection is recommended.⁴ Reports describe a 30% to 50% recurrence.¹

This article presents the treatment of a JOF and a spontaneous regeneration of the bone after the tumor resection.

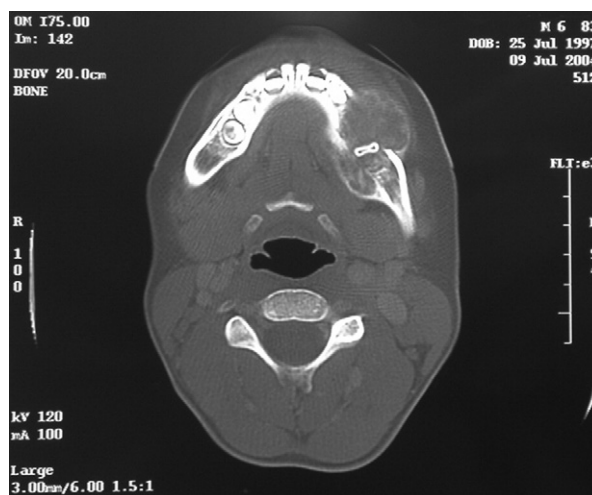

Fig. 1. Axial view of a CT scan of the lesion involving both cortical plates and a tooth in the center.

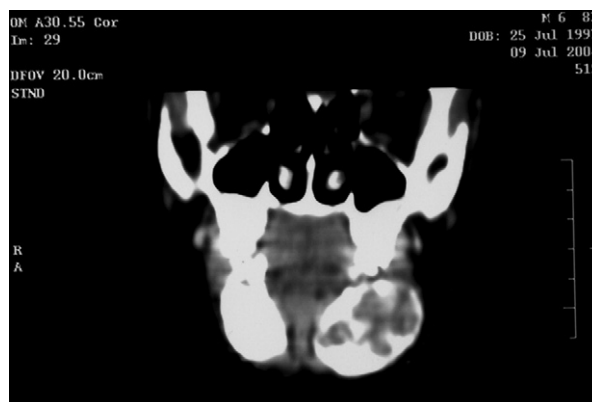

Fig. 2. Coronal view of the lesion. A mixed image is seen in the central zone of the lesion.

^aResident, Department of Oral and Maxillofacial Surgery, San Borja Arriaran Hospital, School of Dentistry, University of Chile, Santiago, Chile.

^bAssistant Professor, Department of Oral and Maxillofacial Surgery, San Borja Arriaran Hospital, School of Dentistry, University of Chile, Santiago, Chile

Received for publication Nov 29, 2005; returned for revision Feb 25, 2006; accepted for publication Mar 29, 2006.

1079-2104/\$ - see front matter

© 2006 Mosby, Inc. All rights reserved.

doi:10.1016/j.tripleo.2006.03.027

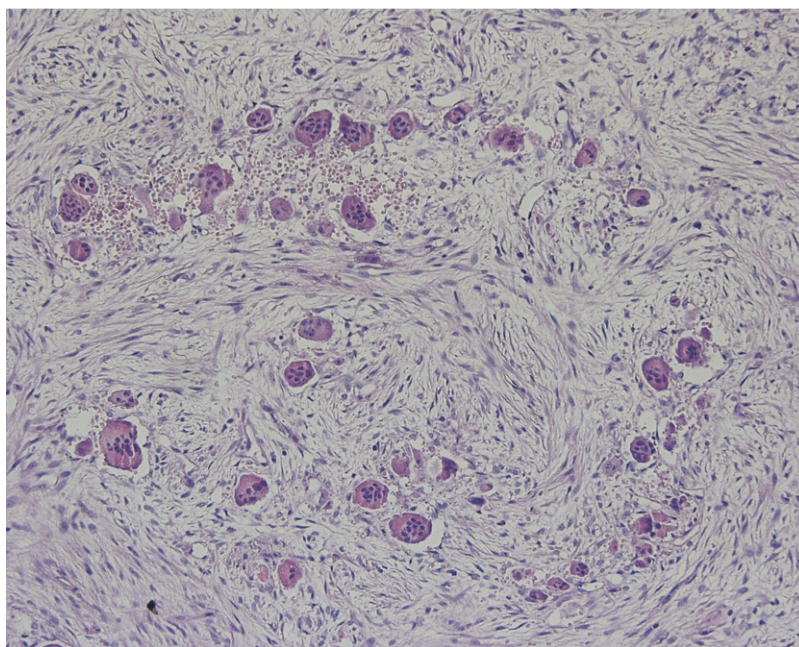


Fig. 3. Histology of the lesion with fibroblastic proliferation, newly centers of osteoid, and numerous multinucleated giant cells.

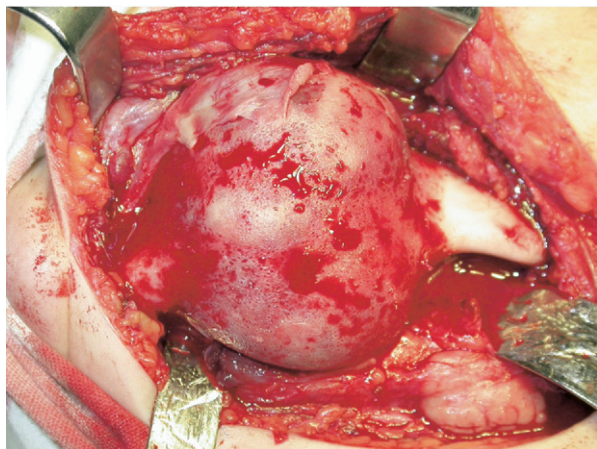


Fig. 4. Intraoperative view of the lesion, previous to resection.

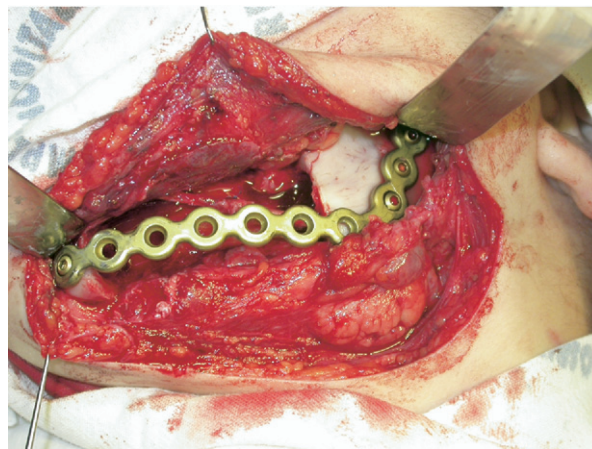


Fig. 5. Resection of the JOF and the 2.7-mm reconstruction plate adapted through stereolithographic models.

CASE REPORT

A 7-year-old boy was referred to the Maxillofacial Surgery Department of the San Borja Arriarán Hospital with a left mandibular swelling and the diagnosis of ameloblastoma or osteosarcoma. The tumor had existed for 6 months. The lesion was asymptomatic. The physical exam revealed a large, firm mass involving the left mandibular body, approximately 5 cm in diameter. No abnormalities of skin were present. Intraoral examination revealed buccal and lingual bone expansion in the

molar region. No tooth mobility or inflammatory signs were observed in the area.

Panoramic radiographs showed a well-circumscribed unilocular lesion with central opacities. There was root resorption in the adjacent molar tooth. Additionally, mandibular computed tomography (CT) confirmed the expansion of both bony corticals as well (Fig. 1), with mixed areas of central opacification (Fig. 2).

Biopsy of the lesion confirmed the diagnosis of juvenile ossifying fibroma corresponding to the World Health Organization (WHO) type. The histopathology

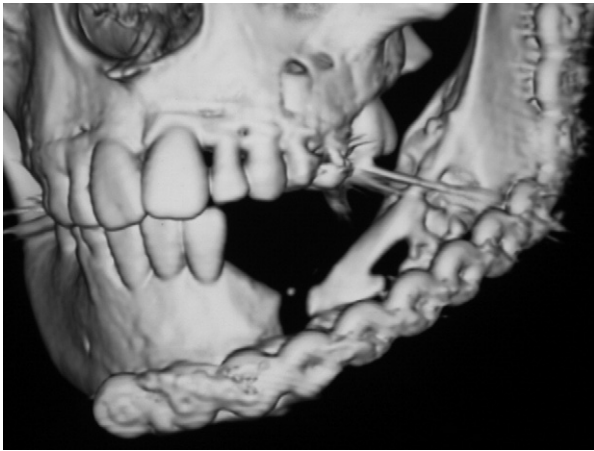


Fig. 6. Postoperative CT scan (6 months) showing spontaneous regeneration almost connecting both sides of the resection.

showed fibroblastic proliferation with newly centers of osteoid and numerous multinucleated giant cells (Fig. 3).

The tumor was resected through a submandibular approach with no communication to the oral cavity, leaving a 4.5-cm defect. The periosteum and the inferior alveolar nerve were preserved. The mandible was stabilized with a 2.7-mm reconstruction plate (Figs. 4 and 5). There were no complications encountered during this procedure. The plate was pre-adapted through stereolithographic models. Six months after surgery, ill-defined corticalized bone regeneration with spongy pattern on both sides of the surgical defect was observed (Figs. 6 and 7).

DISCUSSION

JOF is a rare fibro-osseous lesion that appears at an early age, but it has also been described in older patients (older than 15 years).⁵ Differential diagnosis can be established with cemento-ossifying fibroma (histological variant of the same lesion),⁵ osteofibrous dysplasia, and fibrous dysplasia¹. Among JOFs, there are 2 specific entities: the WHO type and the psamoma-like ossicles, the latter appearing in older patients and being subject of debate if it should be classified as a JOF.⁶ Its clinical behavior has been described as aggressive, which although not being malignant, quickly jeopardizes the neighboring bony tissues. This has been confirmed in our experience, where rapid growth of the tumor was observed, especially once a biopsy was performed. It is interesting to emphasize the absence of the inferior second premolar germ, also reported by Noffke⁷ and Rinaggio et al.,⁸ based on the theory that

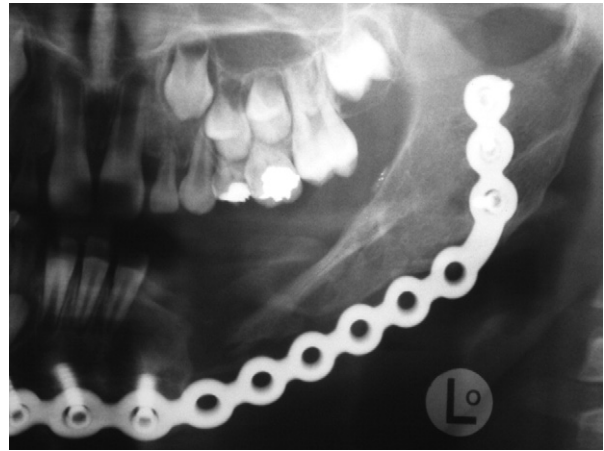


Fig. 7. Radiographic view after 6 months.

JOF would appear like an aberration during the odontogenesis.

Enucleation or curettage has been the treatment proposed for this lesion in many reports.^{5,8,9} This treatment was not chosen because of the size of the injury, the speed of growth, and the reports of recurrence (38% to 58%)⁵⁻⁸ in relation to this type of pathologies after conservative treatments.²⁻⁴ The use of the stereolithographic models was of great benefit, which diminished the operating time, blood loss, time of an open wound, and the patient's anesthesia exposure.

After 6 months, spontaneous bony regeneration was observed in the limits of the resection with irregular and slightly corticalized edges.

In our investigation, there are no reports of this behavior after a JOF resection.

This phenomenon may be explained because of the preservation of the periosteum and the age of the patient. It has been described by various authors,⁹⁻¹¹ giving great importance to periosteum as a membrane with osteogenic potential. They have even described bony regenerations in relation to other lesions and in irradiated tissues.⁹ This healing potential is very active in children.¹² Gosain et al.¹³ demonstrated that significant bone formation in a segmental gap can be achieved following acute mandibular resection and extended rigid fixation if the periosteum is preserved. Lemperle et al.¹⁴ propose macroporous protective sheets in the defects for preventing soft-tissue prolapse, allowing the migration of mesenchymal cells and the proliferation of blood vessels from the adjacent soft tissues into the bone defect for spontaneous regeneration. We believe that the preservation of the periosteum may serve to prevent the prolapse of the soft tissues as Gosain et al.¹³ speculate, but this leads to the question of whether allowing a membrane to prevent soft-tissue prolapse

may have been even more effective in the bone regeneration.

Initially we planned a second intervention for autogenous grafts, but given the observed behavior, we decided to wait for and evaluate bony regeneration through successive controls.

REFERENCES

1. Williams HK, Mangham C, Speight PM. Juvenile ossifying fibroma. An analysis of eight cases and a comparison with other fibro-osseous lesions. *J Oral Pathol Med* 2000;29:13-8.
2. Leimola-Virtanen R, Vabatalo K, Syrjanen S. Juvenile active ossifying fibroma of the mandible: a report of 2 cases. *J Oral Maxillofac Surg* 2001;59:439-44.
3. Neville B, Damm D, Allen C, Bouquot J, editors. *Oral and maxillofacial pathology*. United States of America: Philadelphia, PA: Saunders; 2002; p. 564-6.
4. Zama M, Gallo S, Santecchia L, Bertozzi E, De Stefano C. Juvenile active ossifying fibroma with massive involvement of the mandible. *Plast Reconstr Surg* 2004;113(3):970-4.
5. Waldron C. Fibro-osseous lesions of the jaws. *J Oral Maxillofac Surg* 1993;51:828-35.
6. Slootweg PJ, Panders AK, Koopmans R, Nikkels PGJ. Juvenile ossifying fibroma. An analysis of 33 cases with emphasis on histopathological aspects. *J Oral Pathol Med* 1994;23:385-8.
7. Noffke C. Juvenile ossifying fibroma of the mandible. An 8 year radiological follow up. *Dentomaxillo Rad* 1998;27:363-6.
8. Rinaggio J, Land M, Cleveland D. Juvenile ossifying fibroma of the mandible. *J Pediatr Surg* 2003;38:648-9.
9. Ruggiero SL, Donoff RB. Bone regeneration after mandibular resection: report of two cases. *J Oral Maxillofac Surg* 1991;49:647-52.
10. Nagase M, Ueda K, Susuki I, Nakajima T. Spontaneous regeneration of the condyle following hemimandibulectomy by disarticulation. *J Oral Maxillofac Surg* 1985;43:218-20.
11. Pramono C. Spontaneous bone regeneration after mandibular resection in a case of ameloblastoma: a case report. *Ann Acad Med Singapore* 2004;33(suppl):59S-62S.
12. Malizos K, Papatheodorou L. The healing potential of the periosteum. Molecular aspects. *Injury* 2005;36S:S13-9.
13. Gosain A, Kalantarian B, Shen Song L, Larson J, Jenkins C, Wilson C. Comparison of canine mandibular bone regeneration by distraction osteogenesis versus acute resection and rigid external fixation. *Plast Reconstr Surg* 2004;114:1490-9.
14. Lemperle S, Calhoun C, Curran R, Holmes R. Bony healing of large cranial and mandibular defects protected from soft-tissue interposition: a comparative study of spontaneous bone regeneration, osteoconduction, and cancellous autografting in dogs. *Plast Reconstr Surg* 1998;101(3):660-72.

Reprint requests:

Sebastián A. Espinosa, DDS
Department of Oral and Maxillofacial Surgery
School of Dentistry, University of Chile
7750-A Simon Bolivar, La Reina
Santiago, Chile,
sebastianespinosas@gmail.com