

Skeletodental Diagnosis Using a Geometric Morphometric Approach

Diagnóstico Dentoesequelal Mediante la Aplicación de un Enfoque Morfométrico Geométrico

Alejandro Díaz Muñoz^{*} & Germán Manríquez Soto^{**}

DÍAZ, M. A. & MANRÍQUEZ, S. G. Skeletodental diagnosis using a geometric morphometric approach. *Int. J. Odontostomat.*, 8(1):5-11, 2014.

ABSTRACT: In orthodontics and maxillofacial surgery, dentoesekeletal diagnosis is essential for treatment planning. Traditionally, this diagnosis is carried out using cephalometric analysis based on the comparison of distances and angle measurements. While this method successfully discriminates within group extreme types of malocclusions, it usually does not distinguish the intermediate ones, which leads to different diagnoses for the same phenotype. Moreover, the linear nature of cephalometric data does not allow to partition shape and size components. In order to study the variation of dentoesekeletal pattern in Chilean population, in the present study standard methods of geometric morphometrics to a sample of 150 lateral telerradiographs of classes I, II division 1 and III were applied. We found that classes I, II and III show statistically significant differences associated, to a greater degree, with a sagittal maxillo-mandibular relationship, and to a lesser degree with a vertical growth pattern, allowing positive discrimination of intermediate phenotypes. We conclude that tools of geometric morphometrics constitute a complementary and effective approach to address unresolved problems associated with conventional cephalometric analysis.

KEY WORDS: malocclusion, geometric morphometrics, cephalometry.

INTRODUCTION

Traditionally, malocclusions have been classified according to Angle (Graber, 1974). This classification represents a high degree of consensus among the occlusionists (Anderson, 1960; Canut, 1982). There is also a skeletal classification, using Class I, II and III as indicators. There is no total agreement on this last definition, which explains the large number of cephalometric analyses proposed by different authors over time (Aguila, 1996). Generally, the different cephalograms discriminate correctly when analyzing individuals with a marked skeletal pattern. However, accurate discrimination decreases as the skeletal pattern becomes less clear.

In this sense, cephalometry may be associated to important methodological problems such as: i) the ambiguity of diagnosis; ii) the absolute character of the measurements; and iii) the use of variables, not allowing analyzing the size and shape components

separately. With regard to the first point, decisions about diagnosis and adopted treatment planning may be contradictory (Arnett & Gunson, 2004; Cooke, 1990; Foster *et al.*, 1981) when analyzing individuals presenting similar phenotypes, due to the inconsistency of spatial information obtained from cephalometric measurements. Similarly, the absolute nature of the interlandmark measurements (linear values) poses problems associated with the absence of the necessary scaling to compare individuals having different cranial sizes. For example, in a typical cephalogram, the length of the anterior cranial base is interpreted as an absolute value regardless of its relationship with the other parts of the skull. Finally, although in cephalometric studies the use of angles is widely accepted to recognize the changes that affect the shape components, separate analysis of the angular values is insufficient to obtain spatial information of the anatomical structure as a whole (McIntyre & Mossey, 2003).

^{*} Facultad de Odontología, Universidad de Chile, Santiago, Chile.

^{**} Programa de Genética Humana, I.C.B.M., Facultad de Medicina, Departamento de Antropología, Facultad de Ciencias Sociales, Universidad de Chile, Santiago, Chile.

Geometric morphometrics constitutes an analytical set of tools and procedures recently introduced in odontological practice (Singh *et al.*, 1997a, 1997b, 1997c; Franchi *et al.*, 2001) that could overcome these limitations. This tool was developed after applying classical morphometric approach and transformation methods of Cartesian grids proposed by D'Arcy Thompson at the beginning of the 20th Century (Thompson, 1980). This new approach allows to describe, partition and analyze shape variation in populations of organisms, regardless of changes in scaling (size components). Specifically, geometric morphometrics studies the co-variation of shape components with their underlying causal factors, for example, size, age, sex, geographical origin, diet, etc. (Rohlf & Marcus, 1993). Geometric morphometrics also allows to partition shape components independently of size, leading to an increase of the predictive value of this method compared with conventional cephalometric analyses (McIntyre & Mossey). Despite being a well-developed approach in areas such as biology (Slice, 2007; Adams *et al.*, 2004), in dentistry, its use is still restricted. Therefore, it is relevant to highlight the studies conducted by Singh *et al.* (1997a), Halozonetis (2004) and Chang *et al.* (1992) among others, which contribute to a better understanding of craniofacial shape variation among individuals. Thus, the aim of this study is to show the contribution of the geometric morphometric approach to improve accuracy of skeletodental diagnosis.

MATERIAL AND METHOD

The sample consisted of 150 initial cephalometric radiographs from the Maxillofacial Surgery Unit of Hospital San Borja Arriarán, Santiago, Chile. Three groups of 50 people each who, according to architectural analysis of Delaire belonging to skeletal malocclusions I, II Division 1 and III respectively, were selected (Table I). No patient had received previous orthopedic or orthodontic treatment. The cephalometric radiograph was standardized in natural head position with focus distance of 1.52 m and an amplitude distortion of 10%. To record the raw data for geometric

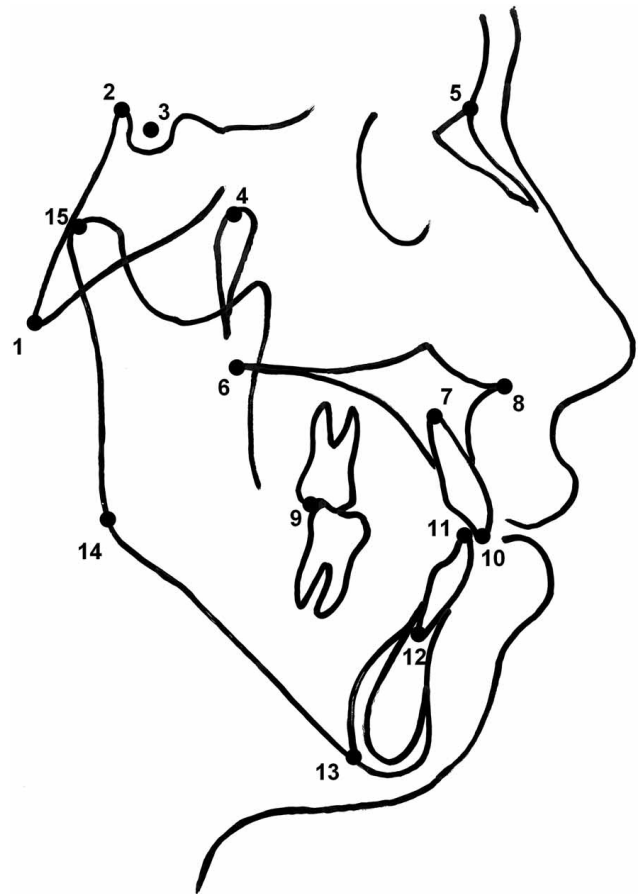


Fig. 1. Map of 15 anatomical landmarks: 1: Basion ; 2: Posterior Clinoid Process; 3: Sella; 4: Ricketts' point (postero-superior point on outline of pterygomaxillary fissure); 5: Nasion; 6: Posterior Nasal Spine; 7: Upper Incisor Apex; 8: Anterior Nasal Spine; 9: Posterior Molar Occlusion; 10: Upper Incisor Tip; 11: Lower Incisor Tip; 12: Lower Incisor Apex; 13: Menton; 14: Gonion; 15: Condylion.

morphometrics analyses following the criteria of Bookstein for landmark data (Bookstein, 1991) (Fig.1), a map of 15 anatomical landmarks (craniomandibular configuration) homology was constructed. These landmarks were directly digitized on the lateral cephalometry of each individual by means of Microscribe-3DX digitizer (Immersion Co.). To visualize the pattern of deformation and to determine the location of the different skeletal malocclusions into the

Table I. Skeletal Class and mean age of the sample used in this study.

	Class I		Class II		Class III	
	Women	Men	Women	Men	Women	Men
Sex						
n	25	25	25	25	25	25
Mean age (Years±SD)	16.8±3.92	15.1±4.06	17.7±2.68	16.1±2.37	17.08±3.56	17.16±2.54

morphometric space, the matrices were subjected to a Procrustes analysis according to the standard algorithm of TPSRelwarp software (V. 1.45) Rohlf (2007a). Only the two first relative warps, which explain the biggest shape variation, were considered.

The null hypothesis regarding size and skeletal malocclusions over the shape components was tested by regression analysis (TPSreg) Rohlf (2007b) available at: <http://life.bio.sunysb.edu/morph/>

The superimposition of aligned matrices of the consensus configurations was carried out by means of the application of graphic functions of Microsoft Office programs Excel 2003 and Microsoft Paint 5.1.

RESULTS

Relative warp analysis of craniomandibular configuration (Fig. 2) showed the presence of three groups, corresponding to the three skeletal malocclusions studied, clearly separated along the first component of shape variation ($x =$ relative warp 1). This corresponds to 46.6% of the overall explained variance. This axis reflects the variation of the sagittal maxillo-mandibular relationship, changes of cranial base rotation, changes of mandibular angle and rotation of

the ramus. The y-axis, which corresponds to the second component of shape variation (relative warp 2), comprises 12.4% of overall shape variation. It shows the variation of proportion between the anterior and posterior height of the face. The tendency towards convergence or divergence of the vertical pattern is also shown. Interestingly, Class I is located between the two remaining classes, closer to Class II, showing a morphological proximity with it. The extreme of Class II distribution shows, a maxillary and dental overjet, an anterior rotation of the cranial base, a posterior rotation of the ramus, and a mandibular angle closure. The extreme Class III distribution shows a maxillary and dental negative overjet, a posterior rotation of the cranial base, an anterior rotation of the ramus and an opening of mandibular angle. Regression analysis for skeletal class and centroid size against shape components were statistically significant ($F = 34.4650$, $df1 = 26$, $df2 = 3848$; $p < 0.001$, $F = 17.6343$, $df1 = 26$, $df2 = 3848$ $p < 0.001$, respectively).

To assess more accurately the morphological differences of the extreme of these skeletal malocclusions distribution (classes II and III), a superimposition of previously standardized craniomandibular consensus matrices was performed (Fig. 3). As a result, differences in maxillary protrusion, lower incisor protrusion, cranial base rotation and ramus rotation were observed.

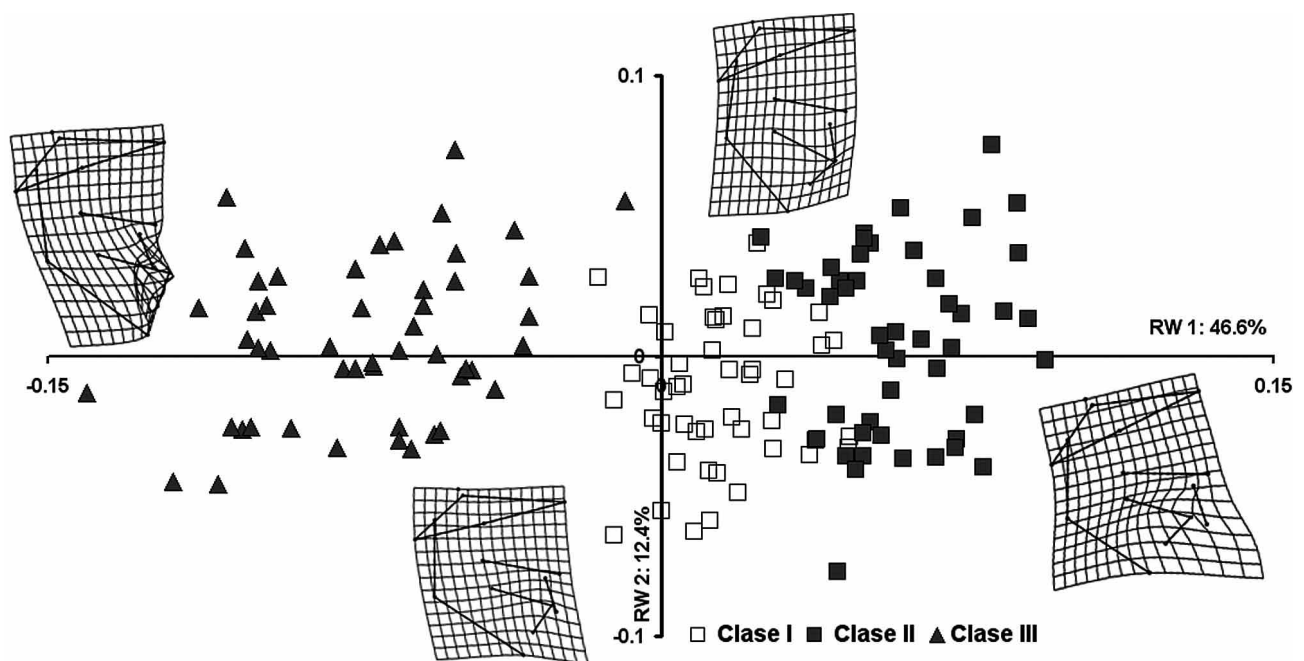


Fig. 2. Relative warp analysis of craniomandibular configuration belonging to the skeletodental malocclusions considered in the present study. Note that class I individuals share a same phenotypic space with class II but not class III.

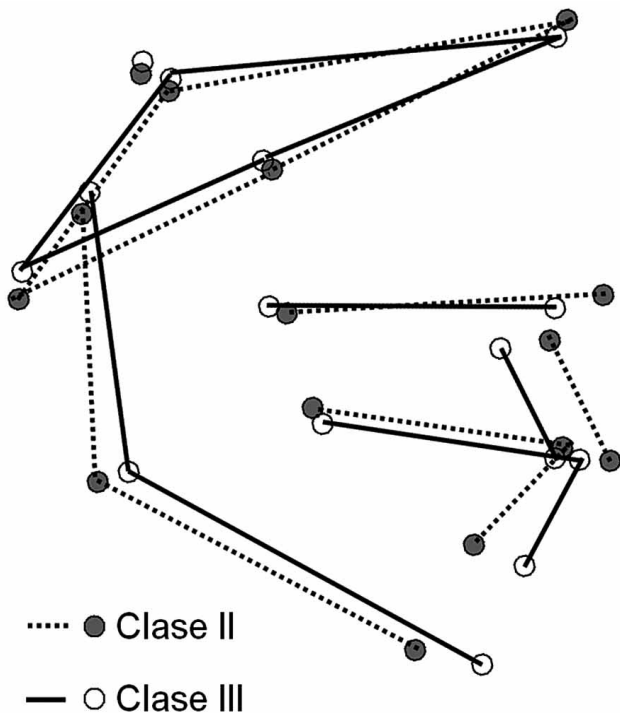


Fig. 3. Superimposition of the craniomandibular aligned consensus matrices obtained from individuals belonging to skeletal classes II, and III. In class II individuals a cranial base anterior rotation, a maxillary protrusion as well as a lower incisor protrusion are clearly shown. The opposite is observed in class III individuals, i.e. a cranial base posterior rotation, a maxillary retrusion as well as a lower incisor retrusion.

DISCUSSION

The methodology used in this study helped us to determine the relative location of skeletal malocclusions into the morphometric space, expressed as a morphological continuous distribution of shape components, from one extreme of class II to an opposite extreme of class III. Such distribution is clearly visible along the first shape component (relative warp 1) expressing the greatest overall variance accumulated by craniomandibular structures considered in the homology map. Specifically, this methodology discriminates the skeletal class of the individuals. As a result of the standard relative warp analysis, a close morphological relationship between class I and class II is evidenced.

The changes observed along the first component of shape variation are complex, involving the craniofacial structure as a whole. These changes are expressed, from the extreme of class II to the opposite

extreme of class III, as a closure of the cranial base angle, posterior rotation of cranial base, expansion of the upper dentoalveolar molar area, contraction of the palatal bone, anterior rotation of the ramus, mandibular expansion, as well as the opening of mandibular angle and lower incisor retrusion.

Although the second component of shape variation (relative warp 2) showed no changes related to some specific skeletal class, this component helped to make the primary diagnosis of Class I, II and III more accurate, including the vertical characteristics of the face. Thus, this component reflects those changes occurring in vertical skeletal pattern, showing a hypodivergence on one extreme and a hyperdivergence on the other. The contribution of this second component to diagnosis has been well recognized in traditional cephalometry (Bishara, 2003).

Our results agree to a great extent with a similar study by Chang *et al.* (2005), who also use the geometric morphometric approach. These authors conclude that Class II is characterized by a palatal elongation accompanied by an antero-posterior mandibular contraction, whereas in Class III, the biggest observed changes are related to the palatal contraction and the mandibular expansion. Moreover, Singh *et al.* (1997b) compared mandibular shape in classes I and III using geometric morphometric tools, concluding that the elongation of mandibular body is the most representative difference between these two skeletal classes. In another Class III study, Singh points out that the maxilla suffers an antero-posterior contraction during its development (Singh *et al.*, 1997c).

On the other hand, Halozonetis, applying the same technique in Greek population, shows that the first relative warp is associated with changes in vertical skeletal pattern, while the skeletal class differences are more evident in the second axis. He did not consider the differences of sex, age or kind of malocclusion. This fact, as well as the kind of distribution observed (unimodal rather than bimodal) and the criterion of selection of the sample (random in the Greek population) could explain the differences between our results and those obtained by Halozonetis.

Geometric morphometrics considers an isotropic distribution model of landmarks, i.e. the probability of landmark change around the consensus landmark per individual will be the same (Bookstein). This allows for a better visualization of the anatomical changes, which may explain the observed differences. For example,

when considering the triangle Ba- S- Na, conventional cephalometry assumes that one side of this triangle (S-Na) or at least one point of it (S) is unchanged, with the angle differences explained due to the variation of other landmarks.

Taking this into consideration, we agree with Arnett, Cooke and Foster, who have indicated that diagnostic criteria based on cranial base references lead to misinterpretation of the morphological differences among individuals (Arnett & Gunson; Cooke; Foster *et al.*). This was clearly observed after applying relative warp analysis in our sample, where Class II shows that the segment S-Na appears very steep, while in Class III, this segment is more horizontal. We propose to call these differences rotations of the cranial base (anterior rotation in the case of Class II, posterior rotation in Class III). In fact, some authors had previously pointed out that changes in nasion landmark could explain certain misunderstandings in cephalometric interpretation (Rothstein & Yoon-Tarlie, 2000; Williams & Andersen, 1986; Goel *et al.*, 2004).

Our results, however, suggest that these discrepancies could be associated with the variation of not only one, but also all the landmarks defining the cranial base. There is some agreement that changes in cranial deflection angle could be associated with sagittal position of the temporomandibular joint (Delaire, 1978; Enlow, 1992). Moreover, Baccetti *et al.* (1997) and Giuntini *et al.* (2008) note that the glenoid fossa and condyle are in a significantly more posterior position in class II with respect to class III. However, our results (Fig. 3) show that in Class III, the condyle would be in a superior position in relation with Class II, but in the antero-posterior aspect, both classes have similar positions. This finding suggests that cranial base could not be considered an etiological agent on facial deformities.

Cephalometric analyses allow us to establish mandibular position criteria. These criteria are mainly based on angular measurements obtained after intracranial reference planes such as Frankfurt plane or cranial base, but as read before, these criteria may be unreliable (Arnett & Gunson; Foster *et al.*). Nevertheless, our results suggest that when a cephalogram is showing different mandibular positions, it is indirectly showing shape differences. For example, when a mandibular ramus is posteriorly rotated, we can assume that the mandible has a posterior position. Similarly, a ramus showing an anterior rotation, the mandibular position will also be considered anterior.

In this sense, our results coincide with those obtained by Björk, 1955 (Bjork, 1995), who recommends to place more emphasis on the analysis of mandibular shape rather than only on its position as an aid in diagnosis and growth prediction.

In orthodontics, skeletodental diagnosis is based on a comparative analysis between cephalometric values presented by a particular patient and the cephalometric mean values previously established by the different studies carried out on this issue (Aguila). This procedure is sometimes tedious and often complex. Moreover, it does not take into account the natural polymorphism present in any human population. Our results support the use of geometric morphometrics in clinical orthodontics to accurately locate the landmarks matrices of each of the individuals into morphometric space created around the consensus or average. The relative location in this space, defined by the two main components explaining the biggest shape variation within a given population, represents, in our opinion, the skeletodental diagnosis. Thus, the morphometric (Procrustes) distance of each case with respect to the consensus (at the intersection of the two principal axes) will be indicative of the clinical severity of the case. Therefore, each diagnostic case would have a precise location into the morphometric space in relation to its expression of skeletal malocclusion as well as its expression of skeletal vertical pattern (Díaz & Manríquez, 2007).

ACKNOWLEDGMENTS

We thank Claudia Trajtemberg (Programa de Inglés, Facultad de Medicina, Universidad de Chile), for improving the English version of this work. Partially funded by Grant Proyecto de Investigación Asociativa en Ciencia y Tecnología Conicyt Anillos ACT-096 (to GM).

DÍAZ, M. A. & MANRÍQUEZ, S. G. Diagnóstico dento-esquelético mediante la aplicación de un enfoque morfométrico geométrico. *Int. J. Odontostomat.*, 8(1):5-11, 2014.

RESUMEN: En ortodoncia y cirugía maxilofacial, el diagnóstico dento-esquelético es esencial para la planificación del tratamiento. Tradicionalmente, este diagnóstico se realiza mediante análisis cefalométricos basados en la comparación de distancias y ángulos. Si bien este método discrimina correctamente los tipos de maloclusiones extremas, por lo

general no distingue los tipos intermedios, lo que lleva a enunciar diagnósticos diferentes para el mismo fenotipo oclusal. Además, la naturaleza lineal de los datos cefalométricos no permite la partición de los componentes de tamaño y forma. Con el objetivo de estudiar la variación del patrón dentoalveolar en la población chilena, aplicamos metodología estándar de morfometría geométrica a una muestra de 150 telerradiografías laterales de clases I, II división 1 y III. Encontramos que las clases I, II y III muestran diferencias estadísticamente significativas asociadas, en un grado mayor, con la relación sagital máxilo-mandibular, y en un menor grado, con el patrón de crecimiento vertical, permitiendo una discriminación correcta de los fenotipos intermedios. Concluimos que las herramientas de morfometría geométrica constituyen un enfoque complementario y eficaz para hacer frente a los problemas no resueltos por el análisis cefalométrico convencional.

PALABRAS CLAVE: maloclusión, morfometría geométrica, cefalometría.

REFERENCES

- Adams, D. C.; Rohlf, F. J. & Slice, D. E. Geometric morphometrics: ten years of progress following the "revolution". *Ital. J. Zool.*, 71(1):5-16, 2004.
- Aguila, J. *Manual de Cefalometría*. Caracas, Actualidades Médico Odontológicas Latinoamericana C. A., 1996.
- Anderson, G. M. *Ortodoncia Práctica*. Buenos Aires, Mundi, 1960.
- Arnett, G. W. & Gunson, M. J. Facial planning for orthodontists and oral surgeons. *Am J. Orthod. Dentofacial Orthop.*, 126(3):290-5, 2004.
- Baccetti, T.; Antonini, A.; Franchi, L.; Tonti, M. & Tollaro, I. Glenoid fossa position in different facial types: a cephalometric study. *Br. J. Orthod.*, 24(1):55-9, 1997.
- Bishara, S. *Ortodoncia*. México D.F., McGraw-Hill-Interamericana, 2003.
- Bjork, A. Facial growth in man studied with the aid of metallic implants. *Acta Odontol. Scand.*, 13(1):9-34, 1995.
- Bookstein, F. L. *Morphometric Tools for Landmark Data: Geometry and Biology*. New York, Cambridge University Press, 1991.
- Canut, A. *Ortodoncia Clínica*. Barcelona, Salvat, 1982.
- Chang, H. P.; Kinoshita, Z. & Kawamoto, T. Craniofacial pattern of Class III deciduous dentition. *Angle Orthod.*, 62(2):139-44, 1992.
- Chang, H. P.; Lin, H. C.; Liu, P. H. & Chang, C. H. Midfacial and mandibular morphometry of children with Class II and Class III malocclusions. *J. Oral Rehabil.*, 32(9):642-47, 2005.
- Cooke, M. S. Five-year reproducibility of natural head posture: a longitudinal study. *Am. J. Orthod. Dentofacial Orthop.*, 97(6):489-94, 1990.
- Delaire, J. L'analyse architecturale et structurale cranio-faciale (de profil). *Rev. Stomatol. Chir. Maxillofac.*, 79(1):1-33, 1978.
- Díaz, A. & Manríquez, G. *Diagnóstico ortodóncico mediante morfometría geométrica*. Libro de resúmenes 53ª Reunión de la Sociedad Española de Ortodoncia. Cádiz, España, 2007.
- Enlow, D. *Crecimiento Máxilo Facial*. 3a ed. México D.F., Interamericana McGraw-Hill, 1992.
- Foster, T. D.; Howat, A. P. & Naish, P. J. Variation in cephalometric reference lines. *Br. J. Orthod.*, 8(4):183-7, 1981.
- Franchi, L.; Baccetti, T. & McNamara, J. A. Jr. Thin Plate Spline analysis of mandibular growth. *Angle Orthod.*, 71(2):83-9, 2001.
- Giuntini, V.; De Toffol, L.; Franchi, L. & Baccetti, T. Glenoid Fossa Position in Class II Malocclusion Associated with Mandibular Retrusion. *Angle Orthod.*, 78(5):808-12, 2008.
- Goel, S.; Bansal, M. & Kalra, A. Preliminary assessment of cephalometric orthodontic superimposition. *Eur. J. Orthod.*, 26(2):217-22, 2004.
- Graber, T. M. *Ortodoncia Teoría y Práctica*. México D.F., Interamericana, 1974.
- Halazonetis, D. M. Morphometrics for cephalometric diagnosis. *Am. J. Orthod. Dentofacial Orthop.*, 125(5):571-81, 2004.
- McIntyre, G. T. & Mossey, P. A. Size and shape measurement in contemporary cephalometrics. *Eur. J. Orthod.*, 25(3):231-42, 2003.
- Rohlf, F. J. & Marcus, L. F. A Revolution in Morphometrics. *Trends Ecol. Evol.*, 8:129-32, 1993.
- Rohlf, J. *Relative Warps* V. 1.45. Ecology & Evolution, SUNY at Stony Brook. New York, National Science Foundation Grant Deb-0212023, 2007a.
- Rohlf, J. *TPSReg* software V. 1.34. *Ecology & Evolution*, SUNY at Stony Brook. New York, National Science Foundation Grant Deb-0212023, 2007b.

Rothstein, T. & Yoon-Tarlie, C. Dental and facial skeletal characteristics and growth of males and females with class II, division 1 malocclusion between the ages of 10 and 14 (revisited)-part I: characteristics of size, form, and position. *Am J. Orthod. Dentofacial Orthop.*, 117(3):320-32, 2000.

Singh, G. D.; McNamara, J. A. Jr. & Lozanoff, S. Localisation of deformations of the midfacial complex in subjects with class III malocclusions employing thin-plate spline analysis. *J. Anat.*, 191(Pt. 4):595-602, 1997a.

Singh, G. D.; McNamara, J. A. Jr. & Lozanoff, S. Thin-plate spline analysis of the cranial base in subjects with Class III malocclusion. *Eur. J. Orthod.*, 19(4):341-53, 1997b.

Singh, G. D.; McNamara, J. A. Jr. & Lozanoff, S. Spline analysis of the mandible in humans subjects with class III Malocclusion. *Arch Oral Biol.*, 42(5):345-53, 1997c.

Slice, D. Geometric Morphometrics. *Ann. Rev. Anthropol.*, 36:261-81, 2007.

Thompson, D. *Sobre el crecimiento y la forma*. Madrid, Hermann Blume Ediciones, 1980.

Williams, S. & Andersen, C. E. The morphology of the potential Class III skeletal pattern in the growing child. *Am. J. Orthod.*, 89(4):302-11, 1986.

Correspondence to:
Germán Manríquez S.
Avda. Independencia 1027, Santiago
CHILE

Telephone : 056-02-9786451
Fax number: 056-02-7373158

Email: gmanriqu@med.uchile.cl

Received: 01-02-2013
Accepted: 17-11-2013