

Effects of chronic copper exposure during early life in rhesus monkeys^{1–3}

Magdalena Araya, Shannon L Kelleher, Miguel A Arredondo, Walter Sierralta, María Teresa Vial, Ricardo Uauy, and Bo Lönnerdal

ABSTRACT

Background: Whether infants regulate copper absorption and the potential effects of excess copper in early life remain poorly defined.

Objective: The objective of the study was to assess copper retention, liver copper content, and liver function in infant rhesus monkeys fed infant formula containing 6.6 mg Cu/L.

Design: From birth to 5 mo of age, infant rhesus monkeys were fed formula that was supplemented with copper (0.6 mg Cu/L; $n = 5$) or not supplemented ($n = 4$). In all animals, weight and crown-rump length (by anthropometry), hemoglobin, hematocrit, plasma ceruloplasmin activity, and zinc and copper concentrations were measured monthly (birth to 6 mo) and at 8 and 12 mo. When the animals were 1, 5, and 8 mo old, liver copper and metallothionein concentrations, liver histology (by light and electron microscopy), and the number of Küpffer cells were assessed, and ⁶⁷Cu retention was measured. Liver function was assessed by measurement of plasma alanine aminotransferase, aspartate aminotransferase, gamma-glutamyl transferase, and alkaline phosphatase activities and protein, albumin, bilirubin, and blood urea nitrogen concentrations.

Results: ⁶⁷Cu retention was 19.2% and 10.9% after 1 and 5 mo of copper treatment, respectively, compared with $\approx 75\%$ in controls at age 2 mo. At age 8 mo, ⁶⁷Cu retention was 22.9% in copper-treated animals and 31.5% in controls. Liver histology remained normal by light microscopy, with mild ultrastructural signs of cell damage at 5 mo. Liver copper concentration was 4711, 1139, and 498 $\mu\text{g/g}$ dry tissue at 1, 5, and 8 mo, respectively, in copper-treated animals and 250 $\mu\text{g/g}$ at 2 mo in controls. Measurements could not be completed in all animals.

Conclusions: No clinical evidence of copper toxicity was observed. Copper absorption was down-regulated; increases in liver copper content at ages 1 and 5 mo did not result in histologic damage. Ultrastructural changes at age 5 mo could signal early cellular damage.

KEY WORDS Copper load, rhesus monkey, neonate monkeys, copper absorption, liver

INTRODUCTION

Homeostatic mechanisms regulate copper absorption over a wide range of intakes in humans. Copper absorption in young adults measured by using ⁶⁵Cu retention, was found to change from 55.6% to 36.3% and to 12.4% when copper intake was 0.79, 1.68, and 7.53 mg/d, respectively (1). This suggests that copper absorption is dependent on copper intake over a wide range of

dietary exposures. Yet the limits of homeostasis—specifically, the amount of copper exposure that can result in early, detectable adverse consequences—remain unclear. Clinical controlled studies in infants (2) and community-based intervention studies in apparently healthy adults exposed to 3–10 times the customary copper intake (up to 9 mg Cu/d) have not shown significant changes in traditional indicators of copper status (3–5).

Data regarding copper absorption and its regulation during early life are limited. The assumptions are that copper accumulates in fetal liver during the third trimester of pregnancy (6, 7) and that stored copper will meet infant copper requirements during the breastfeeding period, while milk copper concentration is low (8). However, the risk of excess copper exposure in young infants fed formulas prepared with water containing high concentrations of copper remains a concern among pediatricians living in areas where drinking water may contain more than a few (1–2) milligrams of copper per liter of water. Our group (2) reported results from infants exposed to $80 \mu\text{g Cu} \cdot \text{kg}^{-1} \cdot \text{d}^{-1}$ for 14 d showing that copper absorption, studied by using stable isotopes, was similarly high at 1 and 3 mo of age, which suggests either that young infants cannot down-regulate copper absorption as has been observed in adults (1), or that the dose or duration (or both) of the load used for the study was insufficient to alter copper homeostasis, and therefore the copper did not trigger a compensatory response (2). To address this question, we report here the effects of controlled, chronic (from birth to 5 mo of age) copper exposure in an infant rhesus monkey (*Macaca mulatta*) model, with the use of a copper load based on estimations of the copper intake needed to induce Indian childhood cirrhosis (9). In addition, long-term consequences of high neonatal copper intake were addressed by monitoring liver histology and function up to 8 mo of age, ie, 3 mo after exposure to high copper had been discontinued.

¹ From the Institute of Nutrition and Food Technology (INTA), University of Chile, Santiago, Chile (MA, MAA, WS, and RU); the Departments of Nutrition and Internal Medicine, University of California, Davis, Davis, CA (SLK and BL); Unidad de Anatomía Patológica, Hospital San Borja Arriarán, Santiago, Chile (MTV); and Public Health Nutrition, London School of Hygiene & Tropical Medicine, London, United Kingdom (RU).

² Supported by an unrestricted grant from the Corporación Chilena del Cobre (COCHILCO, Chile) and the Corporación para la Nutrición Infantil (CINUT, Chile).

MATERIALS AND METHODS

Study design

This protocol was approved by the Animal Care and Resources Committee and the Radiation Use Authorization Committee at the University of California, Davis. Infant rhesus monkeys were obtained from the California National Primate Research Center (Davis, CA). Animals were kept indoors under the constant care of nursery and veterinary staff and were bottlefed ad libitum from birth to age 5 mo with a standard, commercially available infant formula (Enfamil; Mead Johnson Nutritionals, Evansville, IN; $n = 4$) containing 0.6 mg Cu/L ($n = 4$) or the same formula supplemented with CuSO₄ (an additional 6.0 mg Cu/L) ($n = 5$). From birth to 1 mo, the animals were individually housed in polycarbonate isolettes with a surrogate mother (a terrycloth dummy); from 1 to 5 mo of age, 2 animals were housed in each stainless-steel cage. Food intake was monitored daily. Monthly anthropometric measures (weight and crown-rump length) and fasting (>2 h after last feeding) venous blood samples were taken. At ages 6, 8, and 12 mo (1, 3, and 6 mo after discontinuation of the copper load), blood samples were drawn, and the measurements were repeated. At ages 1, 5, and 8 mo, copper absorption was measured after radioisotope administration (⁶⁷Cu), and a biopsy was performed of liver tissue from all animals unless otherwise stated.

Hematologic studies

Hemoglobin, hematocrit, and white blood cell differential (CD4/CD8) were quantified with an automated electronic cell counter (Baker 9010 Analyzer; Serono-Baker, Allentown, PA). Ceruloplasmin oxidase activity in plasma was assayed with the use of *o*-dianisidine dihydrochloride according to the method of Schosinsky et al (10).

Absorption studies

Copper retention was measured after radioisotope administration. Monkeys were fasted for 4 h before being fed the radiolabeled formula [$\approx 1 \mu\text{Ci } ^{67}\text{Cu}$ (Brookhaven National Laboratory, Brookhaven, NY)/3 mL diet] by orogastric intubation. Immediately after dosing, each animal was placed inside a whole-body counter (Institute of Toxicology and Environmental Health, University of California, Davis, Davis, CA) equipped with two 10 × 20-cm sodium iodide crystals and a multichannel analyzer (ND-66; Nuclear Data, Schaumburg, IL) for measurement of the amount of radioactivity administered. No food was given for 2 h after dosing. Radioactivity in the animals was recounted after 4 d to ascertain the amount of isotope retained. Whole-body copper retention was calculated as the amount of radioactivity retained after 4 d, and isotopic decay was taken into account.

Plasma mineral analysis

Samples were digested with 0.1% (by vol) ultrapure nitric acid as described by Clegg et al (11). Plasma copper and zinc concentrations were analyzed by flame atomic absorption spectrophotometry (Thermo Jarrell Ash, Franklin, MD). Bovine liver preparations were used as reference materials (Standard Reference Material 1577; National Institute of Standards and Technology, Gaithersburg, MD) to validate the mineral analyses.

Liver enzymes

Total protein, albumin, alanine aminotransferase, aspartate aminotransferase, gamma-glutamyl transferase, alkaline phosphatase, bilirubin, creatinine, and blood urea nitrogen were measured by the Veterinary Clinical Diagnostic Laboratory at the University of California, Davis, with the use of commercially available kits (Roche Diagnostics, Indianapolis, IN), and analyzed by using a Hitachi 1717 Clinical Chemistry Autoanalyzer (Roche Molecular Biochemicals, Indianapolis, IN).

Studies in biopsied liver tissue

Tissues for biopsy were obtained by suction of the liver with the use of a small (infant) needle, always in the right-side liver lobe and with the needle inserted in different directions at each insertin to avoid sampling only one area. The tissue samples were cut into pieces for light and electron microscopy and for measurement of tissue copper content. One piece was fixed in 4% formaldehyde for 8–12 h at room temperature and then washed twice in buffer and progressively dehydrated with graded ethanol and xylene. Tissue was embedded in paraffin, serially sectioned at 5 μm , and stained for hematoxylin and eosin and rhodamine, according to routine procedures. Specific monoclonal antibodies were used to assess metallothionein concentration and the number of K upffer cells by immunohistochemical techniques. For K upffer cell assessment, a semiquantitative scale was developed, defining 0 as absence of staining and +++ as the strongest staining observed. The number of K upffer cells and apoptotic cells were expressed as the mean number of cells per 5 fields. Two observers (MTV and MA) performed all histologic evaluations unaware of the animal assessed; their evaluations showed >95% agreement. The third piece of tissue was snap-frozen and maintained at -70°C until it was analyzed.

Electron microscopy studies

For transmission electron microscopy, tissue was fixed for 8–10 h in 4% paraformaldehyde plus 0.5% glutaraldehyde in phosphate buffer (0.1 mol/L; pH 7.4), at room temperature. After being washed 3 times in phosphate buffer, the tissue was dehydrated with graded ethanol and embedded in LR-Gold resin (EMS, Fort Washington, PA) as described previously (12). After peroxide-induced polymerization in cold, the resin blocks were cut in a Reichert ultramicrotome, the 70-nm thin sections were collected on formvar-coated 300 mesh grids (EMS) and then stained with uranyl acetate and lead citrate. The specimens were assessed with a CM100 electron microscope (Philips Electron Optics, Eindhoven, Netherlands) operating at 80 kV.

Measurement of copper content in biopsied liver tissue

The biopsied liver tissues were weighed and dried for 12 h at 200 $^\circ\text{C}$. The tissue was processed according to the Association of Official Analytical Chemists (13). Briefly, the tissue was digested with a mix of ultrapure nitric acid (2 mL) and sulfuric acid (2 mL) and boiled in a micro-Kjeldahl digestion unit (Labconco Corp, Kansas City, MO) for 15 min. The digest was cooled, perchloric acid (2 mL) was added, and the mixture was boiled again until the sample was colorless and transparent. The digest was diluted with 10 mL demineralized and double-distilled water. The copper content was measured by using an atomic absorption spectrometer equipped with graphite furnace (SIMAA

CHRONIC COPPER EXPOSURE IN EARLY LIFE

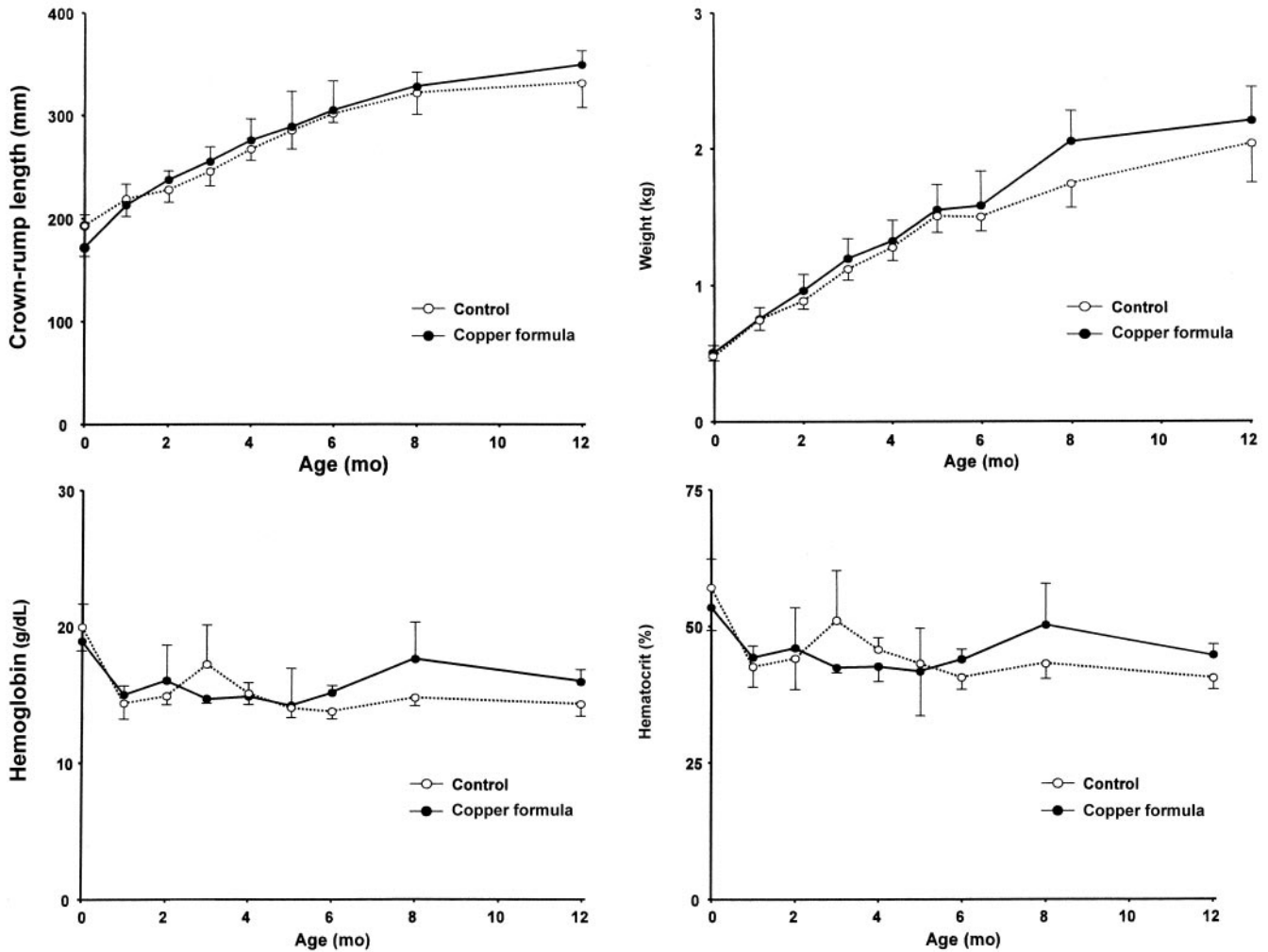


FIGURE 1. Mean (\pm SD) crown-rump length, weight, hemoglobin, and hematocrit during the first 12 mo of life in *Macaca mulatta* exposed (\bullet ; $n = 5$) or not exposed (\circ ; $n = 4$) to 6 mg CuSO_4/L . A trend was noted only for copper exposure and weight ($P = 0.06$).

6100; Perkin Elmer, Shelton, CT). MR-CCHEN-002 (*Venus antiqua*) and Dolt-2 (*Dogfish liver*) preparations were used as reference materials to validate the mineral analyses.

Statistical analysis

Values are given as mean (\pm SD). Statistical analysis was performed by two-factor repeated-measures analysis of variance with a Bonferroni posttest or t test (for ^{67}Cu retention, liver enzymes, and liver liver concentration) by using GRAPHPAD PRISM software (version 3.02; GraphPad, San Diego, CA). Main effects of copper treatment and the interaction between copper treatment and age were ascertained. Significance was set at $P = 0.05$.

RESULTS

The copper-supplemented formula was well accepted; food intake did not differ significantly between copper-treated and control animals (data not shown). There was a trend toward an age \times copper treatment interaction for weight that favored the high copper group, but the difference was not significant ($P = 0.06$) (Figure 1). There was no significant age \times copper treatment interaction for hemoglobin concentration, hematocrit, plasma copper concentration, or ceruloplasmin activity (Figure

1). The age \times copper treatment interaction for plasma zinc concentration was significant ($P < 0.05$). Copper-supplemented animals had significantly lower plasma zinc concentrations than did control animals during the copper supplementation period; however, after discontinuation of copper supplementation, plasma zinc concentrations returned to normal (Figure 2). There was no significant effect of copper treatment on liver aminotransferases or alkaline phosphatase. Retention of ^{67}Cu at ages 1 and 5 mo was $19.8 \pm 2.6\%$ and $10.9 \pm 2.0\%$, respectively, in the copper-treated animals ($n = 4$ animals/group). We were unable to evaluate ^{67}Cu retention in control animals at those ages because of the unavailability of ^{67}Cu at the specific times (ie, the production of the short-lived isotope at the intended age did not coincide with the availability of control animals at the UC Davis Primate Center), but data from our previous studies showed that $\approx 75\%$ of ^{67}Cu is retained in control animals at ages 1 and 5 mo (14). At age 8 mo—ie, 3 mo after cessation of copper supplementation—there was no significant effect of prior copper supplementation on ^{67}Cu retention (control animals: $31.5 \pm 13\%$; copper-treated animals: $22.9 \pm 5.6\%$).

A limitation to this study is that liver tissue for only one biopsy was obtained from each control animal, and that sample was

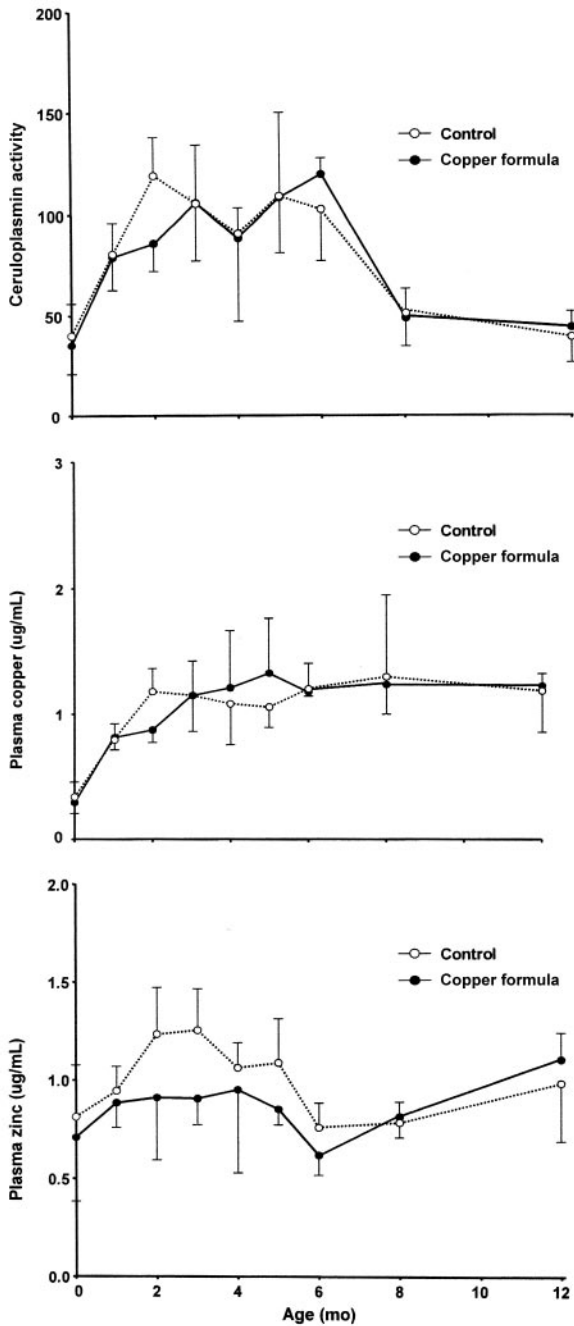


FIGURE 2. Plasma ceruloplasmin, copper, and zinc concentrations during the first 12 mo of life in *Macaca mulatta* exposed (●; n = 5) or not exposed (○; n = 4) to 6 mg CuSO₄/L. A significant decline in zinc during the first 5 mo (period of high copper exposure) was noted, and the zinc concentration × copper exposure interaction was significant (P < 0.05). No significant differences in copper and ceruloplasmin concentrations were noted.

obtained when the animals were 2 mo old; thus, comparison of experimental animals at ages 1 and 5 mo is made by contrasting those findings with these single samples of biopsied tissue. Architecture and histologic characteristics of copper-treated animals were normal as examined by light microscopy (Figure 3) and did not differ significantly from those observed in control animals at all ages. Signs of tissue scarring were not observed, which suggests that tissue samples for consecutive biopsies were

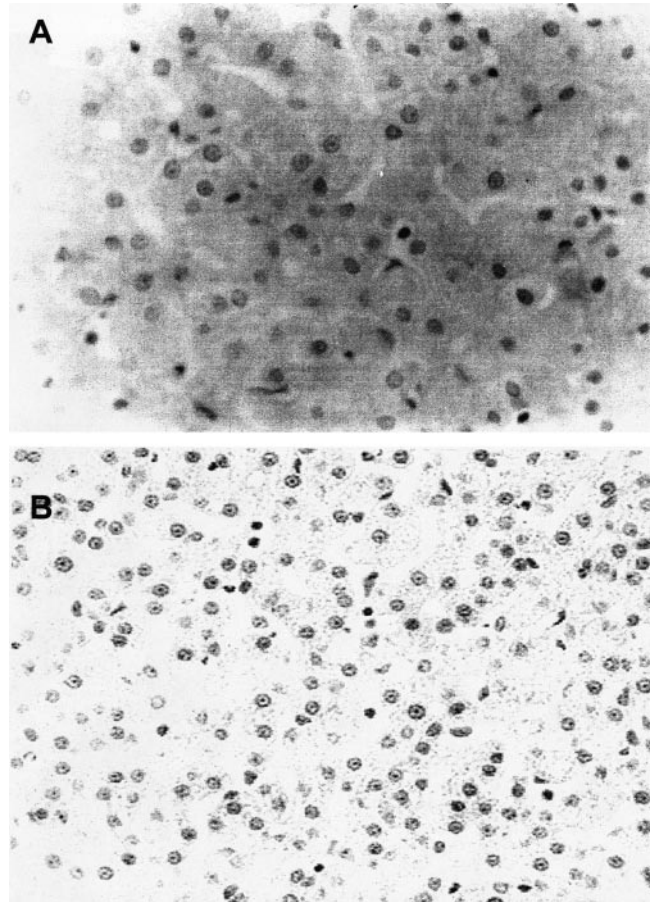


FIGURE 3. Light microscopy of liver biopsies in *Macaca mulatta* shows normal liver histology after 5 mo of feeding a milk formula containing 0.6 mg Cu/L (controls; A) or the same formula containing an additional 6.0 mg Cu/L (copper-supplemented animals; B). Multiplication: ×40.

obtained from different places. Rhodamine staining was negative in biopsied tissue obtained at age 1 mo; however, in that obtained at age 5 mo, fine, small cytoplasmic granules were seen in some areas, mainly around the central venules, in copper-treated animals (Table 1); in control animals, rhodamine staining was negative at all times. When the numbers of Kuppfer cells seen in the biopsied tissue obtained at 2 mo (the control biopsies) and in the biopsied tissue obtained at ages 1 and 5 mo, the copper-treated animals showed 70% and 49% more Kuppfer cells, respectively, than did the controls.

Positive metallothionein staining was found in both the cytoplasm and nuclei in controls and copper-treated animals at 1 mo, and the distribution was mainly around the central venule. Semi-quantitative analysis of metallothionein staining classified copper-treated animals as (+++), whereas controls were (+). Pyknotic nuclei and apoptotic cells were few in all animals, but, at age 5 mo, there were twice as many apoptotic cells in copper-treated animals as in control animals. At age 8 mo, all indicators measured were normal, and none differed significantly between treated and untreated animals. After 1 mo of copper treatment, irregularly shaped nuclei containing condensed chromatin were often seen on electron microscopy. Abundant, polymorphic mitochondria ranged in size from 0.5 to 1 μm and displayed visible cristae. Hepatocytes contained numerous secondary lysosomes, which were filled with electron dense material. In many cells,

CHRONIC COPPER EXPOSURE IN EARLY LIFE

TABLE 1

 Light microscopy findings in biopsied liver tissue from *Macaca mulatta* after 1 and 5 mo of receiving a controlled copper load and 3 mo after finishing the controlled exposure

	Control animals (age 2 mo) (<i>n</i> = 4)	Experimental animals (<i>n</i> = 4)		
		Age 1 mo	Age 5 mo	Age 8 mo
Histologic tests	Normal	Normal	Normal	Normal
Rhodamine staining	Negative	Negative	Fine, granular	Negative
Küpferr cells per 5 random fields	23 (21–28) ¹	39 (32–46)	35 (27–52)	22 (10–26)
Metallothionein				
Positive cells per 5 random fields (%)	15	80	50	60
Intensity of reaction ²	+	+++	++	++
Apoptosis in liver biopsy (% of animals)	25	25	50	<25
Copper content in liver (ug/g dry tissue)	250 (175–325)	4700 (3800–5600) ³	1100 (680–1600) ³	500 (360–630) ⁴

¹ \bar{x} ; range in parentheses (all such values).

² Reaction grading range: 0 to +++.

^{3,4} Significantly different from control animals (ANOVA adjusted by Dunnett's test for repeated measurements): ³*P* = 0.001, ⁴*P* = 0.005.

there were scanty glycogen rosettes and numerous small vesicles; in general, rough endoplasmic reticulum (RER) was prominent, but in cells that were rich in vesicles, the RER was somewhat distorted. At 5 mo, the cell ultrastructure of hepatocytes was normal in all animals, with well-defined mitochondria, regularly shaped nuclei, chromatin decondensation, abundant mitochondria of normal appearance with well-defined cristae, few secondary lysosomes, abundant glycogen rosettes, few or no vesicles, and profuse RER.

The limitation of obtaining only one liver tissue sample for biopsy from the control animals also applies to copper measurements in liver. After 1 mo of copper treatment, the liver copper concentration was 4711 $\mu\text{g/g}$ dry tissue weight (Table 1); this value decreased to 1139 $\mu\text{g/g}$ dry tissue weight at age 5 mo and then progressively decreased to 498 $\mu\text{g/g}$ dry tissue weight at age 8 mo. Yet, at age 8 mo, or 3 mo after discontinuation of copper treatment, copper-treated animals still had significantly higher liver copper concentrations than did control animals. If measurements in experimental animals at ages 1, 5, and 8 mo are compared with the single measurement performed at age 2 mo in the control animals, the differences are significant (*P* = 0.001, *P* = 0.001, and *P* = 0.005, respectively).

DISCUSSION

Indicators of copper status such as serum copper and ceruloplasmin concentrations remain unchanged in human infants consuming different amounts of copper (15–17). We observed similar results in infant monkeys, which suggests that blood copper homeostasis is tightly regulated. However, the effects of copper on small intestine and liver, tissues that play a dominant role in copper homeostasis, show evidence of regulatory responses. Mechanisms that control intestinal copper absorption are immature during early neonatal life in rats (18), which potentially places younger animals at greater risk for adverse consequences of high copper exposure. Copper supplementation of suckling rat pups resulted in small-intestine copper concentration that was significantly higher than that in control rats, but plasma copper concentration was not affected (19). In addition, young copper-treated rats accumulated more hepatic copper, had more severe liver changes, and had higher serum liver enzyme activities than did adult rats (20), which further suggests that the ability to regulate copper homeostasis is age-dependent. In our infant

monkeys, high copper intake during the first 5 mo of life was well tolerated and resulted in no evidence of clinical copper toxicity, whereas copper treatment did result in a progressive reduction in ⁶⁷Cu retention, which suggests that copper retention is indeed down-regulated in infant primates when dietary copper intake is high. Previous studies in human infants fed 80 μg Cu/kg/d did not detect changes in copper retention between 1 and 3 mo of age (2), but copper exposure in the current study was \approx 75 times higher than that in the study conducted in human infants, and it more adequately reflects the copper intake of infants fed infant formula that has been reconstituted with copper-contaminated drinking water (9).

Copper treatment induced detectable changes in the liver (Table 1). At 1 mo, liver copper concentration was significantly higher in copper-treated infants than in controls (4711 and 250 $\mu\text{g/g}$ dry tissue, respectively), and this difference was associated with a 70% increase in Küpferr cells, which suggests some form of stress or a trigger for inflammation. After birth and over the first months of life, these cells are thought to progressively increase in number, but no reference data are available from which to estimate the magnitude and the precise timing for this in humans or primates. Küpferr cells are the resident macrophages in the liver, and they are known to migrate rapidly and proliferate locally in response to various stimuli (21–23). Therefore, it is possible that the marked increase in the numbers of Küpferr cells found after 1 mo of copper treatment may be a tissue response to manage oxidative stress due to copper exposure rather than a result of age alone. However, these findings were not associated with evidence of hepatitis, which contrasts with observations made in Fisher rats by Fuentealba et al (20), who found multifocal hepatitis and widespread single-cell necrosis in copper-treated rats. Detection of metallothionein was markedly increased, and electron microscopy corroborated that copper was indeed deposited in hepatocytes and that at least part of the copper was retained in lysosomes, as reported by others (20). The fact that not all measurements could be done exactly as planned represents a limitation of this study.


At age 5 mo in these monkeys, liver copper content remained high, whereas copper retention had decreased from $19.8 \pm 2.6\%$ to $10.9 \pm 2.0\%$. Biliary excretion is immature at birth, and serum bile acid concentration is low as reflected by the low efficiency of intestinal fat absorption (24). Serum bile acid concentrations

increase after birth, and they remain significantly higher through the first 4 to 6 mo of life than they are in adults (25, 26). One can speculate that age-related improvement in biliary function may have contributed to the lower liver copper concentration we observed at age 5 mo than at age 1 mo, because bile is the primary route for copper excretion.

After 5 mo of copper loading, there were no signs of hepatitis and no further increase in the number of K upffer cells, but the proportion of cells in which apoptotic nuclei were observed was significantly greater at age 5 mo than at age 1 mo. This observation agrees with those of others in rats (20) and may reflect the duration of copper treatment. In contrast to the high copper concentration measured in the liver, only a light (fine, granular) positive rhodamine staining was detected in the liver, which suggests that copper may be sequestered in a form or compartment that does not react with rhodamine. It is interesting that, in children with biliary atresia, Wilson disease, and Indian childhood cirrhosis (in which excess copper is deposited in the liver), this staining is intensely positive (9, 27). It is particularly interesting that Wilson disease results from a mutation in the *ATP7B* gene, which encodes a copper-specific ATPase (28, 29). The normal *ATP7B* gene product (Atp7B) is localized to the *trans*-Golgi apparatus and, in cultured hepatocytes, relocalizes to a vesicular compartment to either sequester copper or facilitate copper excretion (30). The Wilson disease mutation is associated with a failure of Atp7B relocalization and thus restricts copper excretion via the biliary pathway, which facilitates hepatotoxicity. In rat pups, *ATP7B* is not appreciably expressed until late infancy (19), and, thus, copper transport mechanisms responsible for cellular copper excretion, in addition to immature biliary function, may not yet be fully mature in the rhesus monkey at age 1 mo. Thus, maturation in Atp7B localization may also play a role in the different patterns of rhodamine staining we observed in the animals at ages 1 and 5 mo.

Although no effects of copper treatment on indicators of copper status were observed, plasma zinc concentration was significantly lower in animals exposed to high dietary copper. The disappearance of this effect after discontinuation of copper treatment suggests it was a correctable, acute response to high copper intake. An interesting aspect of this study was the assessment of residual long-term consequences of early neonatal copper exposure. Three months after discontinuation of copper treatment (ie, when the animals were 8 mo old), while animals were receiving the recommended amount of dietary copper, retention 22.9%, as compared with 10.2% at age 5 mo. The higher value was still lower than the ⁶⁷Cu retention measured in the control animals (31.5%), which indicated that, 3 mo after discontinuation of the high copper intake, retention was still down-regulated. It is interesting that, at this time, the light-positive copper staining in the liver was no longer detected, and that liver copper concentration diminished further, to 250 μ g/g dry weight. Yet this concentration was still approximately twice that observed in controls. Histologic indicators evaluated by light and electron microscopy were all normal, which suggests that the changes previously detected were reversible.

In summary, in response to a high copper load, infant rhesus monkeys at age 1 mo efficiently down-regulated copper absorption; despite this, there was a remarkable increase in liver copper concentration, which was not associated with histologic evidence of hepatitis, although changes in cell ultrastructure were suggestive of early tissue damage. These changes disappeared 3

mo after discontinuation of copper treatment, which supports that reversibility of the changes. Additional interesting findings include an early increase in the number of K upffer cells, which may represent a tissue response to excess copper. The lack of intense rhodamine staining suggests that copper was complexed or compartmentalized in a way that was nonreactive to rhodamine. It is well known that neonates have a high liver copper concentration, sometimes even higher than the concentrations observed in patients with Wilson disease, without suffering adverse effects, and our findings support the idea that, during the first months of life, the liver is able to handle considerable amounts of copper without permanent histologic damage. 

MA, BL, SK, and RU wrote the manuscript with the assistance of the other authors. All authors contributed to the design and implementation of the study and to the analysis and discussion of the results, and they approved the final version of the manuscript. None of the authors had any financial or personal conflict of interest.

REFERENCES

1. Tumlund JR, Keyes WR, Anderson HL, Acord LL. Copper absorption and retention in young men at three concentrations of dietary copper by use of the stable isotope ⁶⁵Cu. *Am J Clin Nutr* 1989;49:870–8.
2. Olivares M, L nnerdal B, Abrams SA, Pizarro F, Uauy R. Age and copper intake do not affect copper absorption, measured with the use of ⁶⁵Cu as a tracer, in young infants. *Am J Clin Nutr* 2002;76:641–5.
3. Araya M, Olivares M, Pizarro F, Gonzalez M, Speisky H, Uauy R. Gastrointestinal symptoms and blood indicators of copper load in apparently healthy adults undergoing controlled copper exposure. *Am J Clin Nutr* 2003;77:646–50.
4. Araya M, Olivares M, Pizarro F, Gonz lez M, Speisky H, Uauy R. Copper exposure and potential biomarkers of copper metabolism. *Bio-metals* 2003;16:199–204.
5. Pizarro F, Olivares M, Araya M, Gidi V, Uauy R. Gastrointestinal effects associated with soluble and insoluble copper in drinking water. *Environ Health Perspect* 2001;109:949–52.
6. Epstein O. Liver copper in health and disease. *Postgrad Med J* 1983;59(suppl 4):88–94.
7. Reed GB, Uvt EM, Landing BH. Copper in childhood liver disease—a histochemical and chemical survey. *Arch Pathol* 1972;93:249–55.
8. Fransson G-B, L nnerdal B. Zinc, copper, calcium and magnesium in human milk. *J Pediatr* 1982;101:504–8.
9. Tanner MS, Portmann B, Mowat AP, et al. Increased hepatic copper concentration in Indian childhood cirrhosis. *Lancet* 1979;1:1203–5.
10. Schosinsky KH, Lehman HP, Beeler MF. Measurement of ceruloplasmin from its oxidase activity in serum by use of *o*-dianisidine dihydrochloride. *Clin Chem* 1974;20:1556–63.
11. Clegg MS, Keen CL, L nnerdal B, Hurley LS. Influence of ashing techniques on the analysis of trace elements in animal tissue. I. Wet ashing. *Biol Trace Elem Res* 1981;3:107–15.
12. Sierralta WD. Immunoelectron microscopy in embryos. *Methods* 2001;24:61–9.
13. Association of Official Analytical Chemist (AOAC). AOAC official methods of analysis. Washington, DC: AOAC, 1997.
14. L nnerdal B, Jayawickrama L, Lien EL. Effect of reducing the phytate content and of partially hydrolyzing the protein in soy formula on zinc and copper absorption and status in infant rhesus monkeys and rat pups. *Am J Clin Nutr* 1999;69:490–6.
15. Salmenper  L, Siimes MA, Nanto V, Perheentupa J. Copper supplementation: failure to increase plasma copper and ceruloplasmin concentrations in healthy infants. *Am J Clin Nutr* 1989;50:843–7.
16. Olivares M, Pizarro F, Speisky H, L nnerdal B, Uauy R. Copper in infant nutrition: safety of World Health Organization provisional guideline value for copper content of drinking water. *J Pediatr Gastroenterol Nutr* 1998;26:251–7.
17. Zietz BP, de Vergara JD, Dieter HH, et al. Copper concentrations in tap

CHRONIC COPPER EXPOSURE IN EARLY LIFE

- water and possible effects on infant's health—results of a study in Lower Saxony, Germany. *Environ Res* 2003;92:129–38.
18. Varada KR, Harper RG, Wapnir RA. Development of copper intestinal absorption in the rat. *Biochem Med Metab Biol* 1993;50:277–83.
 19. Bauerly K, Kelleher SL, Lönnerdal B. Functional and molecular responses of suckling rat pups and human intestinal Caco-2 cells to copper treatment. *J Nutr Biochem* 2004;15:155–62.
 20. Fuentealba IC, Mullins JE, Aburto EM, Lau JC, Cherian GM. Effect of age and sex on liver damage due to excess dietary copper in Fischer 344 rats. *J Toxicol Clin Toxicol* 2000;38:709–17.
 21. Johnson SJ, Hines JE, Burt AD. Macrophage and perisinusoidal cell kinetics an acute live injury. *J Pathol* 1992;166:351–8.
 22. McFee PJ, Schmidt EE, Groom AC. Evidence for Kupffer cell migration along the sinusoids, from high-resolution in vivo microscopy. *Am J Physiol* 1992;263:G17–23.
 23. Bouvens L, Baekeland M, Wisse E. Cytokinetic analysis of the expanding Kupffer cell population in rat liver. *Cell Tissue Kinet* 1986;19:217–26.
 24. Suchy FJ, Bucuvalas JC, Novak DA. Determinants of bile formation during development: ontogeny of hepatic bile acid metabolism and transport. *Semin Liver Dis* 1987;7:77–84.
 25. Itoh S, Onishi S, Isobe K, Manabe M, Inukai K. Foetal maternal relationship of bile acid pattern estimated by high pressure lipid chromatography. *Biochem J* 1982;204:241–5.
 26. Barbara L, Lazzari R, Roda A et al. Serum bile acids in newborns and children. *Pediatr Res* 1980;14:1222–5.
 27. Suchy FJ, Balistreri WF, Heubi JE, Searcy JE, Levin RS. Physiologic cholestasis. Elevation of primary bile acid concentrations in normal infants. *Gastroenterology* 1981;80:1037–41.
 28. Bull PC, Thomas GR, Rommens JM, Forbes JR, Cox DW. The Wilson disease gene is a putative copper transporting P-type ATPase similar to the Menkes gene. *Nat Genet* 1993;5:327–37.
 29. Tanzi RE, Petrukhin K, Chernov I, et al. The Wilson disease gene is a copper transporting ATPase with homology to the Menkes disease gene. *Nat Genet* 1993;5:344–50.
 30. Mercer JF, Llanos RM. Molecular and cellular aspects of copper transport in developing mammals. *J Nutr* 2003;133(suppl 1):1481S–4S.