

Applied nutritional investigation

# Serum folate and homocysteine levels in obese females with non-alcoholic fatty liver

Sandra Hirsch, M.D., M.Sc.<sup>a,\*</sup>, Jaime Poniachick, M.D.<sup>b</sup>, Maritza Avendaño, R.D., M.Sc.<sup>a</sup>, Atila Csendes, M.D.<sup>b</sup>, Patricio Burdiles, M.D.<sup>b</sup>, Gladys Smok, M.D.<sup>b</sup>, Juan C. Diaz<sup>b</sup>, María Pía de la Maza M.D., M.S.<sup>a</sup>

<sup>a</sup> *Institute of Nutrition and Food Technology, University of Chile, Santiago, Chile*

<sup>b</sup> *Hospital Clínico José Joaquín Aguirre, University of Chile, Santiago, Chile*

---

## Abstract

**Objective:** Folate depletion and hyperhomocysteinemia increase the risk for hepatic alcoholic damage and promote oxidative stress in animals. In addition, some investigators have reported an inverse association between serum folate and body mass index and a positive correlation between total homocysteine and fat mass. We investigated whether there is an association between serum folate and total homocysteine concentrations with the presence of non-alcoholic fatty liver disease (NAFLD) in obese subjects.

**Methods:** Forty-three obese (body mass index  $\geq 35$  kg/m<sup>2</sup>) patients who underwent bariatric surgery and hepatic biopsy were included. Serum total homocysteine, folate and vitamin B12 concentrations and hepatic enzymes were measured. Liver biopsies were graded for the presence of fat, inflammation, and fibrosis on a scale from 0 to 3. A total histologic score was calculated based on the sum of partial scores. Severe NAFLD was defined as a total score of at least 4 or severe steatosis (partial score for fat = 3).

**Results:** Severe NAFLD was present in 17 patients. Serum folate concentration was significantly lower in obese patients with NAFLD than in those with normal liver or minimal alterations ( $9.3 \pm 3.5$  versus  $12.2 \pm 3.1$  ng/mL,  $P = 0.005$ ). Serum total homocysteine and vitamin B12 concentrations were similar in both groups. An inverse correlation between serum folate concentration and body mass index was observed ( $r = -0.31$ ,  $P = 0.046$ ).

**Conclusions:** In this study, severe NAFLD in obese subjects was associated with lower serum folate concentrations and serum homocysteine and vitamin B12 concentrations were not associated with liver damage in obese subjects.

## Keywords:

Non-alcoholic fatty liver disease; Folate; Homocysteine; Obesity

---

## Introduction

Non-alcoholic fatty liver disease (NAFLD) and alcoholic liver disease have similar pathologic features, and the latter is more frequent in obese subjects [1]. Folate deficiency is a common nutritional alteration that occurs in alcoholic patients, especially those with liver disease [2,3]. In obese children and adolescents and in overweight and obese

women, serum folate levels correlate inversely with body mass index (BMI), fat mass, and insulin levels [4]. Moreover, folate nutritional status improves after surgery for morbid obesity [5].

Folate circulates as 5-methyltetrahydrofolate and serves as a methyl donor to homocysteine (Hcy), which is converted to methionine, in a reaction catalyzed by methionine synthase, a vitamin B12-dependent enzyme. This is one of the main reactions in the methionine cycle, a metabolic route that leads to the synthesis of S-adenosylmethionine through the enzyme methionine adenosyltransferase, which is expressed in the liver as methionine adenosyltransferase-1A and in other tissues as methionine adenosyltrans-

---

This study was supported by grants 1010571 and 1011057 from Fondecyt.

\* Corresponding author. Tel.: +56-2-6781495; fax: +56-2-221-4030.

E-mail address: shirsch@inta.cl (S. Hirsch).

ferase-2A. S-adenosylmethionine is the main methyl group donor in many transmethylation reactions (e.g., DNA, proteins and lipids), yielding S-adenosylhomocysteine. S-adenosylhomocysteine is hydrolyzed to Hcy, which can be remethylated to methionine by MS or betaine-Hcy methyltransferase in hepatic tissue. This last reaction requires choline as a precursor of betaine. Hcy can also be degraded with the transsulfuration pathway in which vitamin B6 participates and leads to glutathione synthesis [6].

As a consequence, folate deficiency disturbs hepatic methionine metabolism and causes impaired Hcy catabolism in the liver and other tissues by decreasing cystathionine, glutathione and S-adenosylmethionine syntheses, inhibiting Hcy remethylation, increasing S-adenosylhomocysteine, and decreasing hepatic choline and its precursors that could lead to liver damage [7].

In ethanol-fed micro pigs, folate deficiency amplified abnormal hepatic methionine metabolism, increased oxidative stress and DNA damage, and promoted early development of alcoholic liver damage [8].

In smooth muscle cells and liver stellate cells, Hcy impairs extracellular matrix breakdown by inducing the expression and synthesis of the tissue inhibitor of metalloproteinase-1 and  $\alpha_1$ -procollagen [9]. Alcohol-induced hyperhomocysteinemia in mice is associated with endoplasmic reticulum stress, leading to the activation of apoptotic and fat synthetic gene expression in the liver, which contributes to some of the pathologic features of alcoholic liver disease. The correction of hyperhomocysteinemia by betaine reverts these changes [10].

This study explored whether there was an association between serum folate and Hcy concentrations in obese subjects with and without NAFLD.

## Materials and methods

Obese female patients with a BMI value above 35 kg/m<sup>2</sup> who underwent bariatric surgery at the Clinical Hospital of the University of Chile (Jose Joaquin Aguirre Hospital, Santiago, Chile) between March 2000 and December 2002 were consecutively included. Inclusion criteria were no history of alcohol ingestion (defined as alcohol ingestion < 20 g/d, measured by ascertaining the number of drinks per week, which was verified through interview with relatives), negative markers of chronic liver disease or viral hepatitis, and normal renal function (creatinine  $\leq$  133  $\mu$ mol/L) to have a frozen serum sample stored and to have a wedge liver biopsy excised during surgery. These are routine diagnostic procedures for all patients admitted for bariatric surgery. The same surgical procedure was performed in all patients [11].

All subjects gave written informed consent to undergo bariatric surgery, liver biopsy, and store serum samples for future measurements. The protocol was approved by the institutional committees on ethical practice.

Serum total Hcy (tHcy), folate, vitamin B12 concentra-

tions, aspartate aminotransferase, alanine aminotransferase, bilirubin,  $\gamma$ -glutamyltransferase, alkaline phosphatase, glucose, and lipid profile were measured. Folate and vitamin B12 were determined by an ion capture technique using Abbott kits (IMX system folate and B12; Abbott Laboratories, Diagnostic Division, Abbott Park, IL, USA). Serum tHcy was measured with an Abbott kit (Abbott IMX), a procedure based on fluorescence polarization immunoassay technology. Glucose, lipid profile, and hepatic enzymes were measured by routine laboratory assays using Abbott kits. Liver biopsies were prepared for light microscopy. Histologic slides were stained with hematoxylin and eosin and Masson trichromic stain, coded, and read blindly by one of the authors (G.S.), an experienced gastrointestinal pathologist. Histopathologic scoring was performed according to guidelines of the American Gastroenterological Association [12]. Briefly, a minimum of 10 portal spaces was examined in each slide, and the presence of fat, inflammation, and fibrosis was recorded and graded on a scale from 0 to 3. Fat was graded 1 when macrovesicular steatosis constituted up to 30% of the hepatocyte, 2 with 30% to 70%, and 3 with more than 70%. Inflammation was graded 1 if small scattered intralobular foci or hypercellularity in portal tracts was found; 2 if dense hypercellularity or foci was found in all lobules; and 3 if inflammatory enlargement to portal tracts or confluent inflammation was found. Fibrosis was graded 1 when there was pericentral vein fibrosis; 2 if there was septa formation, central, periportal, or intralobular, without bridging; and 3 if there was prominent septa bridging with or without nodule formation. Total histologic scores were the sum of the partial scores. Normal liver or minimal alterations was defined by a total score no higher than 3 with a partial score for fat no higher than 2 (Fig. 1). Severe NAFLD was defined as a partial score of 3 for fat (Fig. 2) or a total score of at least 4 (Fig. 3). Statistical analysis was done with Statistica 4.5 for Windows (StatSoft Inc., 1993). Descriptive data are expressed as mean  $\pm$  standard deviation.

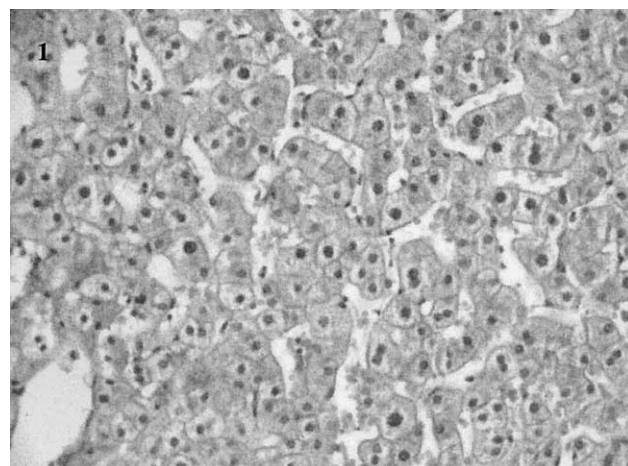


Fig. 1. Light microscopic appearance of the liver from obese females with normal liver, total score = 0 (magnification 100  $\times$ ).

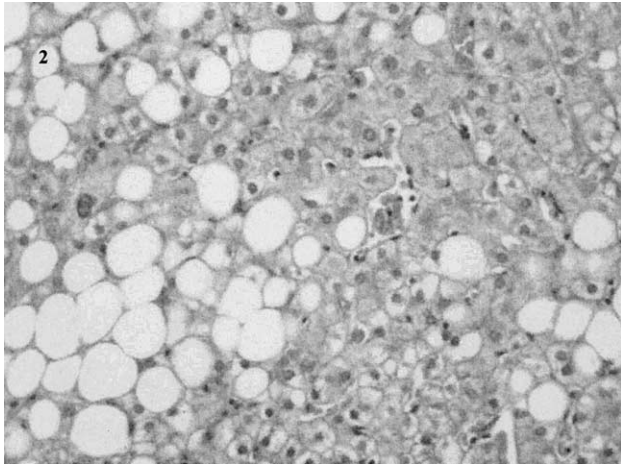


Fig. 2. Light microscopic appearance of the liver from obese females with severe steatosis, partial histological score for fat = 3, partial score for inflammation = 0, partial score for fibrosis = 0 total score = 3 (magnification 100 ×).

tion. Student's *t* test was used to compare differences between means. Associations between numerical variables were evaluated with Pearson's correlation coefficient and Spearman's correlation coefficient for non-continuous variables such as histopathologic scores.

## Results

Forty-three female patients were included. Twenty-six had normal or minimal alterations in liver biopsy (total score =  $1.6 \pm 1.32$ ) and 17 presented severe NAFLD (total score =  $5.4 \pm 1.40$ ).

Age, lipid profile, and serum glucose were similar in obese patients with or without liver alterations. However,

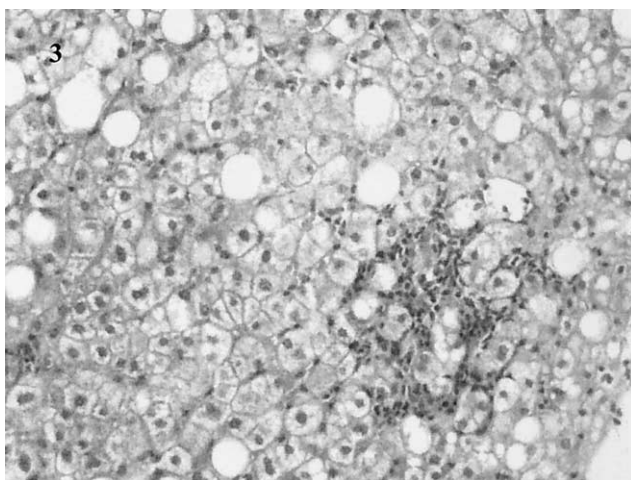


Fig. 3. Light microscopic appearance of the liver from obese females with severe non-alcoholic fatty liver disease, partial score for fat = 2, partial score for inflammation = 2, partial score for fibrosis = 0, total histological score = 4 (magnification 100 ×).

Table 1

General characteristics of patients with and without liver damage\*

	Normal liver ( <i>n</i> = 26)	NAFLD ( <i>n</i> = 17)	<i>P</i>
Age (y)	42.2 ± 11.0	37.4 ± 12.3	0.19
Body mass index (kg/m <sup>2</sup> )	41.3 ± 5.3	47.7 ± 7.5	0.013
Fasting glucose (mg/dL)	96.0 ± 16.3	116.4 ± 45.3	0.06
Total cholesterol (mg/dL)	195.0 ± 48.9	195.3 ± 43.4	0.98
HDL cholesterol (mg/dL)	43.7 ± 13.5	44.5 ± 8.2	0.82
Triacylglycerol (mg/dL)	166.7 ± 56.6	194.3 ± 127.6	0.37

HDL, high-density lipoprotein; NAFLD, non-alcoholic fatty liver

\* Values are mean ± standard deviation.

BMI was higher in those with severe NAFLD (Table 1). Liver enzyme, function tests, and histologic score are shown in Table 2. Patients with NAFLD had higher levels of aspartate aminotransferase and alanine aminotransferase than did patients with normal or minimal histologic liver alterations ( $P < 0.008$ ).

Serum folate concentration was lower in patients with severe NAFLD ( $21.1 \pm 7.9$  nmol/L) than in those with minimal damage or without liver damage ( $27.7 \pm 7.04$  nmol/L,  $P = 0.005$ ). Serum cobalamin and Hcy concentrations were similar in both groups (Table 3). BMI correlated inversely with serum folate concentration ( $r = -0.31$ ,  $P = 0.046$ ) and positively with total histologic score (Spearman's  $r = 0.33$ ,  $P = 0.026$ ). Fat score had a positive correlation with BMI (Spearman's  $r = 0.38$ ,  $P = 0.008$ ) and a negative correlation with serum folate concentration (Spearman's  $r = -0.31$ ,  $P = 0.03$ ). Total histologic score, inflammation, and fibrosis were not correlated with BMI, serum folate, or Hcy concentrations. Serum Hcy concentration was not associated with serum vitamin concentration or BMI.

## Discussion

In this study we found that obese patients with demonstrated severe NAFLD by liver biopsy had lower serum

Table 2

Histologic score, liver enzymes, and function test of patients with and without liver damage\*

	Normal liver ( <i>n</i> = 26)	NAFLD ( <i>n</i> = 17)	<i>P</i>
Total histologic score	1.6 ± 1.32	5.4 ± 1.40	<0.0001
Fat score	0.5 ± 0.84	3 ± 0	<0.0001
Fibrosis score	0.10 ± 0.32	0.73 ± 1.01	<0.0001
Inflammation score	0.5 ± 0.71	1.59 ± 1.11	<0.0001
Albumin (g/dL)	3.8 ± 0.42	3.9 ± 0.33	0.19
Bilirubin (mg/dL)	0.47 ± 0.2	0.63 ± 0.2	0.14
AST (IU/L)	23.4 ± 8.3	45.9 ± 25.0	0.0001
ALT (IU/L)	26.8 ± 9.9	52.8 ± 31.9	0.008
γ-Glutamyltransferase (U/L)	39.5 ± 44.9	73.2 ± 67.2	0.08
Alkaline phosphatase (U/L)	99.9 ± 59.6	102.1 ± 68.7	0.90

ALT, alanine aminotransferase; AST, aspartate aminotransferase; NAFLD, non-alcoholic fatty liver

\* Values are mean ± standard deviation.



Table 3  
Serum folate, homocysteine, and vitamin B12 concentrations in patients with and without liver damage\*

	Normal liver (n = 26)	NAFLD (n = 17)	P
Serum folate (nmol/L) <sup>†</sup>	27.7 ± 7.04 (12.5–47.9)	21.1 ± 7.9 (10.2–32.2)	0.005
Serum homocysteine (μmol/L) <sup>‡</sup>	9.65 ± 3.91 (5.5–21.7)	9.18 ± 2.40 (5.3–14.6)	0.23
Serum vitamin B12 (pmol/L) <sup>§</sup>	286.4 ± 144.1 (140.6–444.0)	300.5 ± 210.7 (159.1–767.4)	0.4

NAFLD, non-alcoholic fatty liver

\* Values are mean ± standard deviation (range).

<sup>†</sup> Normal value is higher than 6.8 nmol/L.

<sup>‡</sup> Normal value is lower than 15 μmol/L.

<sup>§</sup> Normal value is higher than pmol/L.

folate concentrations than did obese subjects with normal liver or minor liver alterations. Our results are consistent with previous demonstrations of the importance of folate deficiency in the development of other models of liver injury. Halsted et al. [8] demonstrated steatonecrosis in five of six folate-deficient ethanol-fed micropigs compared with minimal steatosis in two of six alcohol-fed animals with normal folate ingestion. Suzuki et al. [13] reported that increased serum hepatic aminotransferases during therapy of rheumatoid arthritis with small-dose methotrexate was independently associated with female sex, obesity, baseline aminotransferases, methotrexate dose, and gastrointestinal side effects. Even so, folate supplementation reversed the sustained increase in aminotransferases.

Folate depletion promotes oxidative stress in rat livers due to a deleterious effect in the antioxidant defense system. Glutathione synthesis declines, and copper-zinc superoxide dismutase and glutathione peroxidase activities decrease, but no effect on catalase activity in liver homogenates have been observed. Further, lipid peroxidation products, as measured by thiobarbituric acid-reactive substances and induced by additional H<sub>2</sub>O<sub>2</sub> or Fe<sup>2+</sup> treatments, increases significantly [14–16].

Several studies have associated overweight with low serum folate levels. Epidemiologic studies have demonstrated that obese people replace fruit and vegetables with fatty foods [17–19]. Moreover, obese women double the risk of bearing a child with neural tube defect [20]. Folate depletion also has been observed in 45% of obese patients before gastric bypass surgery [21]. This study is in accordance with these epidemiologic data, because we observed that serum folate concentration is inversely associated with BMI. Thus, lower serum folate concentration in the NAFLD group may have been due to their higher BMI. Another explanation is that, as the methionine cycle fails even in early stages of liver injury, requirements for folate increase in these patients as a protective mechanism. This could lower circulating folate concentrations, although within normal ranges, despite food fortification. This hypothesis developed from results in animal models, showing that, in moderately folate-depleted rats, hepatic S-adenosylmethionine decreases significantly [22].

The lack of correlation between folate and Hcy concentrations observed in this study does not have a clear expla-

nation. It could be due to a ceiling effect because these patients were not folate depleted [23]. The normal folate concentration found in this study is likely explained by the folic acid fortification of wheat flour with 220 μg of synthetic folic acid/100 g of wheat flour, a national program initiated in Chile in January 2000 to decrease women's risk of bearing a child with a neural tube defect [24]. It is also possible that our patients had previous folate deficiency during a long period and that after fortification serum folate and Hcy concentrations recovered, unlike liver histologic alterations. This is not surprising because tHcy recovers shortly after folate supplementation (4 to 8 wk) [25]. Feeding rats with folate-free diets during 4 wk, resulted in compromised hepatic antioxidant enzymatic defences and increased susceptibility to lipid peroxidation in the absence or presence of additional oxidative stress [26]. No data are currently available in humans. The absence of an association between serum folate and Hcy concentrations could also be attributed to a shift of the remethylation pathway from a folate dependence toward a betaine-dependent pathway after adequate ingestion of folate [27].

In conclusion, the association between obesity and lower serum folate concentrations may represent a risk factor for NAFLD. These novel findings deserve further investigation.

## References

- [1] Iturriaga H, Bunout D, Hirsch S, Ugarte G. Overweight as a risk factor or a predictive sign of histological liver damage in alcoholics. *Am J Clin Nutr* 1988;47:235–8.
- [2] Bunout D, Gattas V, Iturriaga H, Perez C, Pereda T, Ugarte G. Nutritional status of alcoholic patients: it's possible relationship to alcoholic liver damage. *Am J Clin Nutr* 1983;38:469–73.
- [3] Lindenbaum J, Roman MJ. Nutritional anemia in alcoholism. *Am J Clin Nutr* 1980;33:2727–35.
- [4] Gallistl S, Sudi K, Mangege H, Erwa W, Borkenstein M. Insulin is an independent correlate of plasma homocysteine levels in obese children and adolescents. *Diabetes Care* 2000;23:1348–52.
- [5] Updegraff TA, Neufeld NJ. Protein, iron, and folate status of patients prior to and following surgery for morbid obesity. *J Am Diet Assoc* 1981;78:135–40.
- [6] Selhub J. Homocysteine metabolism. *Annu Rev Nutr* 1999;19:217–46.
- [7] Pajares MA, Corrales F, Duran C, Mato JM, Alvarez L. How is rat liver S-adenosylmethionine synthetase regulated? *FEBS Lett* 1992; 309:1–4.

- [8] Halsted CH, Villanueva JA, Devlin AM, Niemela O, Parkkila S, Garrow TA, et al. Folate deficiency disturbs hepatic methionine metabolism and promotes liver injury in the ethanol-fed micropig. *Proc Natl Acad Sci USA* 2002;99:10072–7.
- [9] Garcia-Tevijano ER, Berasain C, Rodriguez JA, Corrales FJ, Arias R, Martin-Duce A, et al. Hyperhomocysteinemia in liver cirrhosis mechanisms and role in vascular and hepatic fibrosis. *Hypertension* 2001; 38:1217–21.
- [10] Ji C, Kaplowitz N. Betaine decreases hyperhomocysteinemia, endoplasmic reticulum stress, and liver injury in alcohol-fed mice. *Gastroenterology* 2003;124:1488–99.
- [11] Csendes A, Burdiles P, Jensen C, Diaz J, Cortés A, Rojas J, et al. Resultados preliminares de la gastroplastia horizontal con anastomosis en Y de Roux como cirugía bariátrica en pacientes con obesidad severa y mórbida. *Rev Med Chile* 1999;127:953–60.
- [12] Sanyal AJ, for the American Gastroenterological Association. AGA technical review on nonalcoholic fatty liver disease. *Gastroenterology* 2002;123:1705–25.
- [13] Suzuki Y, Uehara R, Tajima C, Noguchi A, Ide M, Ichikawa Y, Mizushima Y. Elevation of serum hepatic aminotransferases during treatment of rheumatoid arthritis with low-dose methotrexate. Risk factors and response to folic acid. *Scand J Rheumatol* 1999;28:273–81.
- [14] Henning SM, McKee RW, Swendseid ME. Hepatic content of S-adenosylmethionine, S-adenosylhomocysteine and glutathione in rats receiving treatments modulating methyl donor availability. *J Nutr* 1989;119:1478–82.
- [15] Henning SM, Swendseid ME, Ivandic BT, Liao F. Vitamins C, E and A and hemeoxygenase in rats fed methyl/folate-deficient diets. *Free Radic Biol Med* 1997;23:936–42.
- [16] Huang RF, Hsu YC, Lin HL, Yang FL. Folate depletion and elevated homocysteine promote oxidative stress in rat livers. *J Nutr* 2001;131: 33–8.
- [17] Ledikwe JH, Smiciklas-Wright H, Mitchell DC, Jensen GL, Friedmann JM, Still CD. Nutritional risk assessment and obesity in rural older adults: a sex difference. *Am J Clin Nutr* 2003;77:551–8.
- [18] Ganji V, Kafai MR. Third National Health and Nutrition Examination Survey. Demographic, health, lifestyle, and blood vitamin determinants of serum total homocysteine concentrations in the Third National Health and Nutrition Examination Survey, 1988–1994. *Am J Clin Nutr* 2003;77:826–33.
- [19] deGonzague B, Receveur O, Wedll D, Kuhnlein HV. Dietary intake and body mass index of adults in 2 Ojibwe communities. *J Am Diet Assoc* 1999;99:710–6.
- [20] Shaw GM, Velie EM, Schaffer D. Risk of neural tube defect-affected pregnancies among obese women. *JAMA* 1996;275:1093–6.
- [21] Boylan LM, Sugeran HJ, Driskell JA. Vitamin E, vitamin B-6, vitamin B-12, and folate status of gastric bypass surgery patients. *J Am Diet Assoc* 1988;88:579–85.
- [22] Kim YI, Christman JK, Fleet JC, Cravo ML, Salomon RN, Smith D, et al. Moderate folate deficiency does not cause global hypomethylation of hepatic and colonic DNA or c-myc-specific hypomethylation of colonic DNA in rats. *Am J Clin Nutr* 1995;61:1083–990.
- [23] Hirsch S, de la Maza P, Mendoza L, Petermann M, Glasinovic A, Paulinelli P, et al. Endothelial function in healthy younger and older hyperhomocysteinemic subjects. *J Am Geriatr Soc* 2002;50: 1019–23.
- [24] Hirsch S, De la Maza MP, Barrera G, Gattás V, Petermann M, Bunout D. The Chilean flour folic acid fortification program reduces serum homocysteine levels and masks vitamin B-12 deficiency in elderly people. *J Nutr* 2002;132:289–91.
- [25] Hirsch S, Pia De la Maza M, Yanez P, Glasinovic A, Petermann M, Barrera G, et al. Hyperhomocysteinemia and endothelial function in young subjects: effects of vitamin supplementation. *Clin Cardiol* 2002;25:495–501.
- [26] Huang RF, Hsu YC, Lin HL, Yang FL. Folate depletion and elevated homocysteine promote oxidative stress in rat livers. *J Nutr* 2001;131: 33–8.
- [27] Schwahn BC, Chen Z, Laryea MD, Wendel U, Lussier-Cacan S, Genest J Jr, et al. Homocysteine-betaine interactions in a murine model of 5,10-methylenetetrahydrofolate reductase deficiency. *FASEB J* 2003;17:512–4.