

# Anal sphincter trauma and anal incontinence in urogynecological patients

R. A. GUZMÁN ROJAS\*†, I. KAMISAN ATAN‡§, K. L. SHEK‡¶ and H. P. DIETZ‡

\*Departamento de Ginecología y Obstetricia, Facultad de Medicina, Clínica Alemana - Universidad del Desarrollo, Santiago, Chile;

†Departamento de Ginecología y Obstetricia, Hospital Clínico de la Universidad de Chile, Santiago, Chile; ‡Department of Obstetrics and Gynecology, Sydney Medical School Nepean, University of Sydney, Penrith, Australia; §Universiti Kebangsaan Malaysia Medical Centre, Kuala Lumpur, Malaysia; ¶Department of Obstetrics and Gynecology, Liverpool Hospital, University of Western Sydney, Sydney, NSW, Australia

**KEYWORDS:** 3D/4D ultrasound; anal incontinence; anal sphincter; anal sphincter trauma; fecal incontinence; transperineal ultrasound

## ABSTRACT

**Objectives** To determine the prevalence of evidence of residual obstetric anal sphincter injury, to evaluate its association with anal incontinence (AI) and to establish minimal diagnostic criteria for significant (residual) external anal sphincter (EAS) trauma.

**Methods** This was a retrospective analysis of ultrasound volume datasets of 501 patients attending a tertiary urogynecological unit. All patients underwent a standardized interview including determination of St Mark's score for those presenting with AI. Tomographic ultrasound imaging (TUI) was used to evaluate the EAS and the internal anal sphincter (IAS).

**Results** Among a total of 501 women, significant EAS and IAS defects were found in 88 and 59, respectively, and AI was reported by 69 (14%). Optimal prediction of AI was achieved using a model that included four abnormal slices of the EAS on TUI. IAS defects were found to be less likely to be associated with AI. In a multivariable model controlling for age and IAS trauma, the presence of at least four abnormal slices gave an 18-fold (95% CI, 9–36;  $P < 0.0001$ ) increase in the likelihood of AI, compared with those with fewer than four abnormal slices. Using receiver–operating characteristics curve statistics, this model yielded an area under the curve of 0.86 (95% CI, 0.80–0.92).

**Conclusions** Both AI and significant EAS trauma are common in patients attending urogynecological units, and are strongly associated with each other. Abnormalities of the IAS seem to be less important in predicting AI. Our data support the practice of using, as a minimal criterion,

defects present in four of the six slices on TUI for the diagnosis of significant EAS trauma. Copyright © 2015 ISUOG. Published by John Wiley & Sons Ltd.

## INTRODUCTION

Anal incontinence (AI) can affect substantially quality of life. This distressing condition is found in 2–24% of community-dwelling adults<sup>1</sup>. Obstetric anal sphincter injury (OASIS) is a well-known risk factor for AI in women<sup>2</sup> and may be much more common than previously assumed<sup>3–5</sup>. OASIS approximately doubles the risk of AI developing 6 months after a first delivery, but long-term outcomes are less well defined<sup>2</sup>. Since diagnosis in the delivery suite seems to be missed frequently, estimates of true prevalence, and hence any serious attempts at clinical audit or trials designed to improve clinical management, require diagnosis by imaging. Ultrasound findings appear to be related to the severity of AI, but studies to date have been limited by small numbers and short-term follow-up<sup>6,7</sup>. Endoanal ultrasound has been regarded as the gold standard imaging technique for detecting anal sphincter defects. However, the exoanal or transperineal approach has some advantages, such as lower cost and wider availability of equipment, which has led to an increase in its use for assessing anal sphincter abnormalities<sup>8,9</sup>.

The aim of our study was to determine the prevalence of evidence of residual anal sphincter trauma in a cohort of women attending a urogynecological unit and to determine its association with AI. It has been proposed that significant external anal sphincter (EAS) or internal anal sphincter (IAS) trauma should be diagnosed if defects

Correspondence to: Dr R. A. Guzmán Rojas, Clínica Alemana de Santiago, Avenida Vitacura 5951, Vitacura, Santiago 7650569, Chile (e-mail: rodrigoguzman.66@gmail.com)

Accepted: 7 March 2015

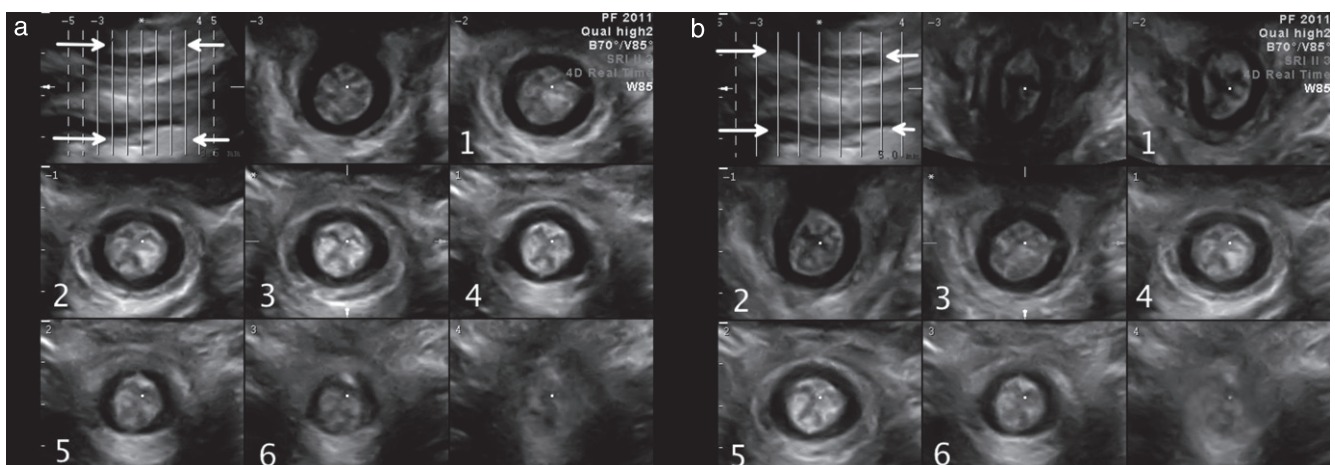
are found in 2/3 of the length of the EAS or IAS<sup>10</sup>. In an attempt to validate this proposition, we aimed to determine mathematically the minimal criteria for the diagnosis of significant EAS and IAS trauma as a predictor of AI. We used translabial four-dimensional (4D) ultrasound<sup>3</sup> as a novel, non-invasive technique to diagnose significant trauma of the anal sphincter complex.

## METHODS

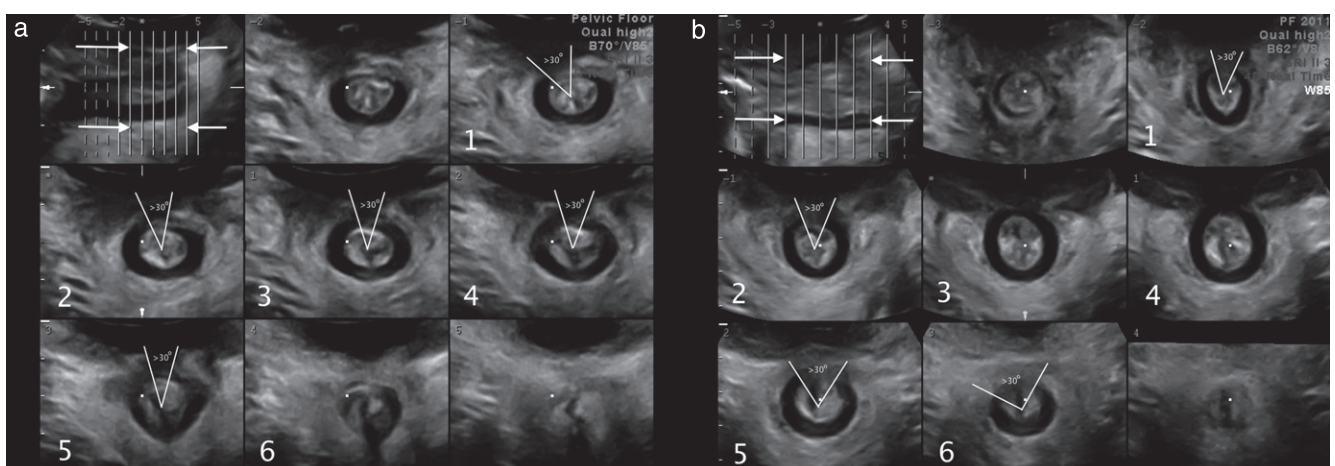
This was a retrospective study including all patients attending a tertiary urogynecological unit between March 2012 and April 2013. All patients underwent a standardized, physician-administered interview, including a St Mark's fecal incontinence score in those complaining of AI. In addition, patients underwent a clinical examination including the International Continence Society Pelvic Organ Prolapse Quantification system (POP-Q)<sup>11</sup>, and three-dimensional (3D)/4D translabial ultrasound using a GE Kretz Voluson 730 Expert system (GE Medical Systems, Zipf, Austria) as described previously<sup>12</sup>. Ultrasound was performed with the patient

in the supine position, after voiding, on maximal Valsalva maneuver and on pelvic floor muscle contraction (PFMC). During PFMC, the midsagittal plane was obtained for levator imaging and the transverse plane for sphincter imaging. Archived ultrasound volumes were analyzed at a later date by R.A.G.R., who was blinded to all clinical data and findings. The proprietary software 4D View v10 (GE Medical Systems) was used for post-processing analysis.

Tomographic ultrasound imaging (TUI) was used to evaluate EAS and IAS trauma on PFMC as described previously<sup>3</sup>. On TUI, a set of eight slices was obtained. We encompassed the entire EAS by placing one slice cranial to the EAS (at the level of the puborectalis muscle) and another caudal to the IAS (at the level of the anal verge), with variable distance between each slice depending on the length of the EAS, leaving six slices to delineate the entire muscle<sup>3</sup> (Figure 1a). The IAS was assessed similarly, with the first slice cranial to the IAS (at the level of the anorectal junction) and the most distal slice at the level of the subcutaneous portion of the EAS (Figure 1b). Interslice intervals were adjusted as necessary. Individual slices were rated as positive if there was a defect present over at least



**Figure 1** Three-dimensional translabial tomographic ultrasound images of normal external (a) and internal (IAS) (b) anal sphincters. Arrows indicate sphincter limits in the midsagittal plane. Note that IAS imaging requires a much wider distance between each slice.



**Figure 2** Three-dimensional translabial tomographic ultrasound images of anal sphincter, showing significant external anal sphincter defects in five of six slices (a) and internal anal sphincter defects in four of six slices (b).

**Table 1** Results of two separate logistic regression analyses for the prediction of anal incontinence based on the number of abnormal slices of the external (EAS) and internal (IAS) anal sphincters on tomographic ultrasound imaging ( $n = 501$ )

Abnormal slices (n)	OR (95% CI)	
	EAS	IAS
0	1 (reference)	1 (reference)
1	2.9 (0.8–11.3)	0.14 (0.0–1.0)
2	5.2 (1.7–16.1)	Not measurable
3	1.4 (0.2–16.1)	5.8 (2.7–12.2)
4	41.6 (14.8–117.1)	11.8 (5.6–24.5)
5	134.4 (31.9–565.7)	6.9 (1.8–26.5)
6	89.6 (23.9–335.8)	10.3 (0.6–171.8)

OR, odds ratio.

30° of the EAS and IAS circumference (Figure 2). A test–retest series ( $n = 20$ ) for the presence of a defect in single slices was carried out to assess agreement between observers.

### Statistical analysis

Statistical analysis was carried out with SAS v 9.3 (Cary CR: SAS Institute Inc., NC, USA) for PC. Univariable and multivariable modeling were undertaken using logistic regression techniques in order to define the optimal model for the prediction of AI, using positive findings in 0–6 slices for both EAS and IAS. We refined the EAS model by controlling for confounders such as age and IAS abnormalities and used receiver–operating characteristics statistics to determine the area under the curve (AUC) of the best model. The model was then applied to a subset of vaginally nulliparous patients in order to determine the likelihood of false-positive findings, given that the likelihood of significant EAS trauma in such women should be zero;  $P < 0.05$  was considered statistically significant. We did not perform power calculations owing to the absence of pilot data and the retrospective nature of this research. The study was approved by the local ethics committee (reference SWAHS HREC 13/16).

### RESULTS

The test–retest series ( $n = 20$ ) yielded a Cohen's kappa of 0.72 (95% CI, 0.60–0.85) for the presence of a defect in the EAS in a single slice on TUI and a Cohen's kappa of 0.68 (95% CI, 0.55–0.81) for an IAS defect, showing good interobserver repeatability. During the study period, 543 women were seen at the urogynecology unit. Ultrasound volumes were missing in 19 patients, and volume datasets were of insufficient quality for assessment in 23 patients. Therefore, 501 datasets were included in the analysis. Mean age was 55.8 (range, 18.4–87.4) years, mean body mass index was  $28.8 \pm 5.9$  kg/m<sup>2</sup> and mean parity was 2.5 (range, 0–9). Among the cohort, 435 (87%) were vaginally parous, 129 (26%) had had at least one previous operative vaginal delivery, 137 (27%) had had a previous hysterectomy and 113 (23%) had had

previous surgery for POP or incontinence. Two hundred and sixty (52%) patients suffered from symptoms of prolapse, 362 (72%) symptoms of stress incontinence, 354 (71%) symptoms of urge incontinence, 181 (36%) symptoms of voiding dysfunction, 132 (26%) from constipation and 318 (63%) from obstructed defecation symptoms. AI was reported by 69 (14%) patients, with a median St Marks' score of 10 (interquartile range, 7–14). Of the women reporting AI, six (9%) were nulliparous, 61 (88%) were vaginally parous, 25 (36%) had had at least one previous operative vaginal delivery and two (3%) had delivered only by Cesarean section.

On TUI analysis of the sphincter complex, six slices were scored for both EAS and IAS, resulting in a total of 6012 assessments. We diagnosed significant abnormalities of the EAS in any slice in 272 (54%) women, and of the IAS in 274 (55%) women. Such defects were found in at least four EAS slices in 88 (18%) women and in at least four IAS slices in 59 (12%) women. In 36 (7%) cases, defects were observed in both EAS and IAS in at least four slices. Table 1 shows the association between a given number of positive EAS and IAS slices and AI. It is evident that there is a marked threshold effect for the EAS, with defects in four to six slices being much more strongly associated with AI than defects in only one to three slices.

Not surprisingly, optimal prediction of AI was achieved by a regression model including at least four positive EAS slices. IAS defects were less likely to be associated with AI (Table 1). In a multivariable model of abnormal EAS slices for the prediction of AI, controlling for age and IAS trauma, the presence of at least four abnormal EAS slices on TUI gave an 18-fold (95% CI, 9–36;  $P < 0.0001$ ) increase in the risk of AI compared to those with fewer than four abnormal slices. This model yielded an AUC of 0.86 (95% CI, 0.80–0.92) for the prediction of AI. Using this cut-off for the sonographic diagnosis of significant EAS trauma, such abnormality was observed in only one out of 66 vaginally nulliparous patients, implying a low likelihood of a false-positive diagnosis.

### DISCUSSION

AI is common in the general female population, and obstetric anal sphincter trauma is one of the main risk factors<sup>13</sup>. Such trauma is commonly missed intrapartum<sup>3,4</sup>, and, even if diagnosed, the anatomical result of primary repair can be disappointing<sup>14</sup>. Until recently, diagnosis of anal sphincter trauma required endoanal ultrasound imaging, a modality that is not commonly available in obstetric units. This has hampered clinical progress in the diagnosis and primary repair of such trauma, as imaging follow-up with a simple, non-invasive method would be required for meaningful audit and prospective studies<sup>15</sup>. The recent development of exoanal translabial 3D/4D tomographic anal sphincter imaging now provides such a modality<sup>3,16,17</sup>. The imaging systems required for exoanal 3D-TUI of the anal sphincter are available in most perinatal ultrasound departments in the developed world. Standard abdominal 3D/4D

transducers used to image the fetus are highly suitable, provided harmonics are set to high and focal zones are optimized for the near field. In addition, the exoanal approach is less invasive for the patient and allows dynamic evaluation of the anal sphincter and mucosa on sphincter contraction, which seems to enhance the definition of muscular defects. This implies that exoanal tomographic sphincter imaging has the potential to become widely available and accepted by both patients and healthcare professionals. However, validation against endoanal ultrasound, the current gold standard for sphincter imaging, is limited to date<sup>18</sup>.

In this large series of women seen at a urogynecology clinic, we found a relatively high prevalence of both AI (14%) and EAS/IAS abnormalities. This may not be surprising since other forms of pelvic floor dysfunction, such as female POP, share common risk factors, such as forceps delivery. The findings are likely to be representative of urogynecological practice in developed countries with largely Caucasian ethnicity. However, it has to be acknowledged that our results may apply only to similar populations, which is an obvious limitation of the study. Findings in different ethnic groups and other subsets of the population may vary substantially. Second, it would have been preferable to obtain imaging information not just by exoanal, but also by endoanal ultrasound. This was not possible owing to the retrospective, opportunistic nature of the study. However, it may be difficult to recruit over 500 women for a prospective study using endoanal ultrasound, due to the invasive nature of this method. Third, one may object that our modeling was performed in a population largely free of AI, with only 14% reporting such symptoms. It is acknowledged that similar studies in a community cohort (with a lower prevalence of AI) or a group of patients presenting to a colorectal clinic (with a much higher prevalence) may yield different results. Finally, it is unfortunate that we have no detailed obstetric information on patients diagnosed with significant EAS trauma. In all likelihood, many of these tears were not diagnosed at delivery and therefore never repaired; in others, imaging appearances may have been influenced by attempts at primary or even secondary repair. It is probable that the association between symptoms and sonographic appearance would vary depending on attempts at surgical reconstruction.

We feel that this study has fulfilled its main purpose. It was designed to validate a definition for significant residual anal sphincter defect, proposed for endoanal ultrasound, namely, that two out of three slices or two-thirds of the EAS have to show a defect of  $\geq 30^\circ$  to be rated as abnormal<sup>10</sup>. Since the tomographic exoanal method produces a set of eight slices, with the most cranial and caudal slices not used for evaluation, the equivalent of the 2/3 rule would be 4/6 slices. We feel that our results validate this rule for use in exoanal TUI of the EAS. Logistic regression modeling suggests that 4/6 EAS slices should be required to show a defect of  $\geq 30^\circ$  for diagnosis of significant EAS trauma. An abnormality fulfilling

this definition was found in 88 (18%) patients, and was highly significantly associated with AI ( $P < 0.0001$ ), with an odds ratio of 18. The association between IAS abnormalities and AI was much weaker and more difficult to interpret. Hence it appears that the definition of significant EAS trauma on endoanal ultrasound can be applied in tomographic exoanal imaging. However, this definition needs to be further validated in patients after clinically diagnosed EAS tears, and in women presenting with AI as their primary complaint.

In conclusion, both AI and significant EAS trauma are common in urogynecological patients, and strongly associated with each other. In fact, significant EAS trauma seems to explain most fecal incontinence in our patients. Abnormalities of the IAS seem to be of lesser importance. In addition, our data strongly support the definition of significant EAS trauma as visible defects of at least  $30^\circ$  of the circumference in at least 4/6 tomographic slices.

## DISCLOSURE

H. P. Dietz and K. L. Shek received unrestricted educational grants from General Electric.

## REFERENCES

1. Macmillan AK, Merrie AE, Marshall RJ, Parry BR. The prevalence of fecal incontinence in community-dwelling adults: a systematic review of the literature. *Dis Colon Rectum* 2004; 47: 1341–1349.
2. Rao S. Pathophysiology of adult fecal incontinence. *Gastroenterology* 2004; 126: S14–S22.
3. Guzmán Rojas R, Shek K, Langer S, Dietz H. The prevalence of anal sphincter injury in primiparous women. *Ultrasound Obstet Gynecol* 2013; 42: 461–466.
4. Andrews A, Sultan A, Thakar R, Jones P. Occult anal sphincter injuries – myth or reality? *BJOG* 2006; 113: 195–200.
5. Oberwalder M, Connor J, Wexner SD. Meta-analysis to determine the incidence of obstetric anal sphincter damage. *Br J Surg* 2003; 90: 1333–1337.
6. Faltin DL, Boulvain M, Floris LA, Irion O. Diagnosis of anal sphincter tears to prevent fecal incontinence: a randomized controlled trial. *Obstet Gynecol* 2005; 106: 6–13.
7. Sultan AH, Kamm MA, Hudson CN, Bartram CI. Third degree obstetric anal sphincter tears: risk factors and outcome of primary repair. *BMJ* 1994; 308: 887–891.
8. Peschers UM, DeLancey JO, Schaer GN, Schuessler B. Exoanal ultrasound of the anal sphincter: normal anatomy and sphincter defects. *Br J Obstet Gynaecol* 1997; 104: 999–1003.
9. Valsky DV, Malkiel A, Savchev S, Messing B, Hochner-Celnikier D, Yagel S. 3D transperineal ultrasound follow-up of intrapartum anal sphincter tears and functional correlation with clinical complaints. *Ultrasound Obstet Gynecol* 2007; 30: 449.
10. Roos AM, Thakar R, Sultan A. Outcome of primary repair of obstetric anal sphincter injuries (OASIS): does the grade of tear matter? *Ultrasound Obstet Gynecol* 2010; 36: 368–374.
11. Bump RC, Mattiasson A, Bø K, Brubaker LP, DeLancey JO, Klarskov P, Shull BL, Smith AR. The standardization of terminology of female pelvic organ prolapse and pelvic floor dysfunction. *Am J Obstet Gynecol* 1996; 175: 10–17.
12. Dietz HP. Pelvic floor ultrasound in prolapse: what's in it for the surgeon? *Int Urogynecol J* 2011; 22: 1221–1232.
13. Sultan AH, Thakar R. Lower genital tract and anal sphincter trauma. *Best Pract Res Clin Obstet Gynaecol* 2002; 16: 99–115.
14. Shek KL, Guzman-Rojas R, Dietz HP. Residual defects of the external anal sphincter following primary repair: an observational study using transperineal ultrasound. *Ultrasound Obstet Gynecol* 2014; 44: 704–709.
15. Dietz HP, Pardey J, Murray H. Pelvic floor and anal sphincter trauma should be key performance indicators of maternity services. *Int Urogynecol J* 2015; 26: 29–32.
16. Valsky D, Cohen S, Lipschuetz M, Hochner-Celnikier D, Yagel S. Three-dimensional transperineal ultrasound findings associated with anal incontinence after intrapartum sphincter tears in primiparous women. *Ultrasound Obstet Gynecol* 2012; 39: 83–90.
17. van de Geest L, Steensma AB. Three-dimensional transperineal ultrasound imaging of anal sphincter injuries after surgical primary repair. *Ultrasound Obstet Gynecol* 2010; 36: 270.
18. Oom DM, West RL, Schouten WR, Steensma AB. Detection of anal sphincter defects in female patients with fecal incontinence: a comparison of 3-dimensional transperineal ultrasound and 2-dimensional endoanal ultrasound. *Dis Colon Rectum* 2012; 55: 646–652.