

Measuring the condylar unit in condylar hyperplasia: from the sigmoid notch or from the mandibular lingula?

R. Fariña¹, R. Bravo², R. Villanueva³,
S. Valladares⁴, A. Hinojosa²,
B. Martínez⁵

¹Department of Oral and Maxillofacial Surgery Hospital del Salvador, Department of Oral and Maxillofacial Surgery Hospital San Borja Arriarán, Oral and Maxillofacial Surgery Universidad de Chile, Santiago, Chile; ²Oral and Maxillofacial Surgery, Hospital del Salvador, Santiago, Chile; ³Oral and Maxillofacial Radiology, Pontificia Universidad Católica de Chile, Santiago, Chile; ⁴Oral and Maxillofacial Surgery, Hospital Clínico Metropolitano el Carmen, Maipú; Oral and Maxillofacial Surgery, Department of Oral Surgery, Pontificia Universidad Católica de Chile, Santiago, Chile; ⁵Oral and Maxillofacial Pathology, Universidad Mayor, Santiago, Chile

R. Fariña, R. Bravo, R. Villanueva, S. Valladares, A. Hinojosa, B. Martínez:
Measuring the condylar unit in condylar hyperplasia: from the sigmoid notch or from the mandibular lingula? Int. J. Oral Maxillofac. Surg. 2017; 46: 857–860. © 2017 International Association of Oral and Maxillofacial Surgeons. Published by Elsevier Ltd. All rights reserved.

Abstract. The objective of this study was to determine, in patients with active unilateral condylar hyperplasia, which is the most reliable point to measure the length of the condylar unit: from the sigmoid notch or from the mandibular lingula to the condylar head. On cone beam computed tomography, an observational cross-sectional study was designed for 20 patients with active unilateral condylar hyperplasia. We measured and compared ramus length (affected and healthy sides) and condylar length (measured from the mandibular lingula and from the mandibular sigmoid notch) on both sides. The average of all the differences in ramus height (D.1) was 7.97 mm; the average of all the differences in condylar heights measured from mandibular lingula (D.2) was 7.16 mm, and measured from the sigmoid notch (D.3) was 4.89 mm. No significant difference between D.1 and D.2 ($P = 0.818$). There was a significant difference between D.1 and D.3 ($P = 0.005$) and between D.2 and D.3 ($P = 0.0005$). It can be concluded that the mandibular lingula is the lowest point of the condylar skeletal unit and is therefore a stable parameter to be used in patients with condylar hyperplasia. On the other hand, the sigmoidal notch is not a stable parameter in patients with asymmetry due to condylar hyperplasia.

Key words: condylar unit; measure of condyle; sigmoid notch; condyle; mandibular lingula; condylar hyperplasia.

Available online 30 March 2017

Mandibular asymmetry is one of the main causes of facial asymmetry. It can be caused by a deficit or excess in the size of one of its components¹. Patients with facial asymmetry require a clinical and radiographic analysis that allow a proper diagnosis and in that way design an

appropriate treatment plan². The measurement of the size of the condyle is usually done from the highest point of the condylar head to the sigmoid notch (SN)^{2–4}.

During embryonic development, the mandibular body presents a membranous ossification guided by the Meckel

cartilage (primary cartilage), which subsequently retrogresses and completely disappears from the mandibular body, transforming itself into two bones of the medial ear, and the sphenomandibular ligament, which will shape the mandibular lingula (ML) through traction⁵. At the

same time, the coronoid process of the mandible appears due to traction of the temporal muscle⁵.

The sigmoid notch (SN) is the depression located between two skeletal units whose origins are secondary cartilages (condylar and coronoid cartilage) that appear on the ramus in the third month of intrauterine development⁶. They are called secondary because they appear at a later stage of development than the Meckel cartilage, and because their growth depends on the function⁶. The coronoid unit will develop based on the traction exercised by the tendon of the temporal muscle, whereas the condylar unit will do so based on the action of the lateral pterygoid muscle, which stimulates growth through the negative intra-articular pressure produced by suction and mandibular movements⁵.

Thus, it can be deduced that, embryologically, the mandibular body forms, guided by the Meckel cartilage, from the mental foramen to the ML (posterior contour of the body) and the formation of the condylar cartilage are secondary, occupying the space from the ML to the glenoidal cavity of the temporal bone. In that way, the uppermost point of the condylar unit is the condylar head and its lowest point is the ML^{7,8}.

That is why it is proposed that the evaluation of the condylar unit ought to include the ML as it is the lowest part. The SN is the depression between two mandibular skeletal units (coronoids and condyle) and could be affected if either of these units presents with an alteration of any kind. Thus, it would not be stable when evaluating condyle length.

Unilateral condylar hyperplasia is a complex pathology that causes serious alterations to facial functions and esthetics. It typically presents itself as a progressive facial asymmetry more frequently in females⁹. The diagnosis is essentially linked to the clinical progression of the disease. Radiological studies and the analysis of mandibular length are crucial for planning an optimal treatment^{10,11}.

Nuclear medicine studies, such as scintigraphy, and single photon emission computed tomography (SPECT) studies are used for diagnostic confirmation of the increased metabolic activity at the condylar affected side. Through the administration of radiomedicine (technetium Tc 99), multiplanar (SPECT) images are produced that show the distribution of this radioactive compound in the patient.

The SPECT study consists of three phases: an angiographic phase, a tissular perfusion phase, and an osseous phase.

This phase measures the degree of the existing metabolism and bone formation. The normal value (nonpathologic) is an average of $50\% \pm 5\%$ ².

The purpose of this study is to determine, in patients with active unilateral condylar hyperplasia (AUCH), which are the most reliable points to measure the length of the condylar unit: from the SN or from the ML to the condylar head.

Materials and Methods

An observational cross-sectional study was designed to compare, with CBCT, the development of the ML and SN in patients with AUCH, and which of those are the most reliable to measure the condylar length.

All 20 patients included in this study were selected from Dr. Rodrigo Fariña's private practice and from Department of Maxillofacial Surgery, Hospital del Salvador, during 2013 to 2015.

All CBCT was performed at a private radiological center (Cimex) in the city of Santiago, Chile, between 2013 and 2015. The images were obtained using a Kodak 9500 Cone Beam 3D System (Carestream Health Inc, Rochester, NY) tomograph operating at 90 kV, 10 mA, with a

0.2-mm³ voxel and a 9 × 15-cm field of vision (FOV). Volumetric reconstruction was calculated using the mathematical algorithms contained in the same company's software. The CBCT images were visualized using Kodak Dental Imaging Software 3D module version 2.4.

A cephalometric tracing of the mandibular ramus and condyle on both sides was done on the cone beam computed tomogram to determine their lengths according to a protocol established for this study (Fig. 1). All measurements were made by the same radiologist.

The inclusion criteria were AUCH (mixed with vertical and horizontal pattern) corroborated with positive bone scintigraphy findings for hyperplasia (hyperuptake of over 10% compared to healthy side in SPECT²), progressive mandibular asymmetry, with a facial midline that did not coincide with the lower dental midline and with center of the chin.

Patients with negative bone scintigraphy findings were excluded, as were patients with any other asymmetry that did not correspond to AUCH.

Variables in study included the following: ramus length on both sides (affected and healthy side); condylar length on both sides, measured from the ML; condylar

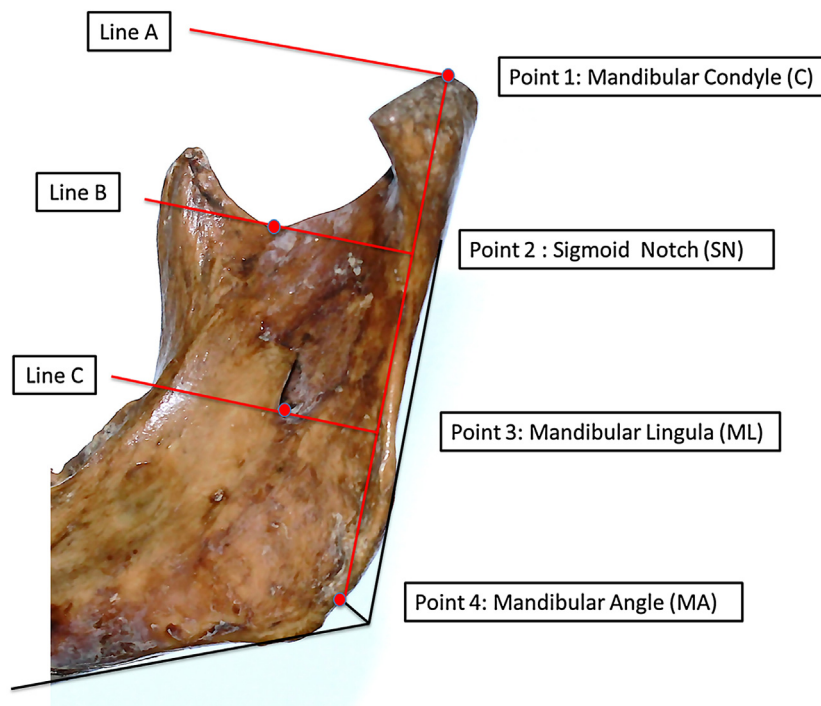


Fig. 1. Outline of the protocol for determining the length of the mandibular condyle. Point 1: upper point of mandibular condyle (C). Point 2: Sigmoid notch (lowest point of the depression in the sigmoid notch) (SN). Point 3: Base of the mandibular lingula (ML). Point 4: Mandibular angle (formed by the bisector of the parotid edge and the basilar edge) (MA). Line A: Line perpendicular to plane formed by points 1–4 at point 1 (condyle). Line B: Line perpendicular to plane formed by points 1–4 at point 2 (SN). Line C: Line perpendicular to plane formed by points 1–4 at point 3 (ML).

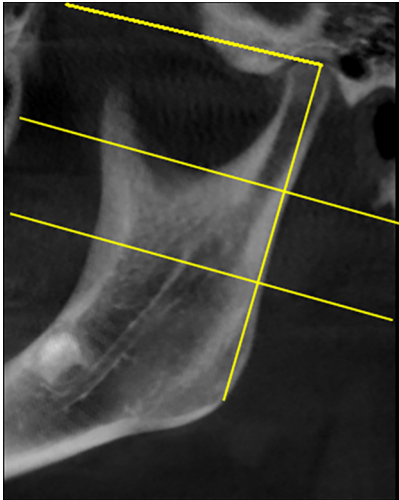

Fig. 2. Cephalometric points on cone beam computed tomography (CBCT).

length on both sides, measured from the mandibular SN.

A cephalometric tracing of the mandibular ramus and condyle on both sides was done on the CBCT to determine their lengths according to a protocol established for this study.

Cephalometric points and measurement protocol

The cephalometric points and measurement protocol (Figs. 1, 2) were as follows:

Point 1: Mandibular condyle (C): uppermost point of the mandibular condyle’s convexity.

Point 2: Sigmoid notch (SN): lowest point of the sigmoidal notch’s concavity.

Point 3: Mandibular lingula (ML): base of the mandibular lingula with relation to the mandibular foramen.

Point 4: Mandibular angle (MA): bisector formed by an angle of the tangent to the parotid edge and the tangent to the basilar edge.

With these four points identified, a connection plane is drawn from point 1 to point 4, which determines the length of the mandibular ramus. Then three lines are drawn perpendicularly to this plane, passing through points 1, 2, and 3, which are lines A, B, and C, respectively.

Once the four cephalometric points have been identified, the following measurements on both ramus sides were done and classified as the affected condyle (AC) and normal condyle (NC) measurements (Fig. 2).

- Ramus height: Distance from point C to MA
- Condylar height from SN: Distance from line C to SN

- Condylar height from ML: Distance from C to ML

The program Stata v 13.1 was used to analyze the results, applying a paired *t* test to compare results within a same group of patients. When more than two variables were compared, a Bonferroni-adjusted *P* value was used.

This study was approved by the Hospital del Salvador ethics board. Patient consent was not required.

Results

This research included 20 patients (15 females, 5 males) with an average age

of 21.6 (standard deviation [SD] 5.71) years (Table 1).

The average of all the differences of ramus heights (D.1) was 7.97; the average of all the differences in condylar heights measured from ML (D.2) was 7.16 mm, and measured from the SN (D.3) was 4.89 mm (Table 2)

There was no significant difference between D.1 (difference between affected condyle from C to MA with normal condyle from C to MA) and D.2 (difference between affected condyle from C to ML with normal condyle from C to ML) (*P* = 0.818) (Table 3).

There was a significant difference between D.1 (difference between affected

Table 1. Distribution of study groups according to age and gender.

Gender	Average age (y)	Standard deviation	95% Confidence interval	<i>P</i> -value
Female (n = 15)	20.73	5.49	17.68–23.77	0.2507
Male (n = 5)	24.2	6.18	16.52–31.87	
Total (n = 20)	21.6	5.71		

Table 2. Patients with Active Unilateral Condylar Hyperplasia.

Patient	Age (y)	Gender	AC		NC		D.1		D.2		D.3	
			MA	ML	MA	ML	AC-NC	AC-ML	AC-SN	NC-SN		
1	18	F	67.7	59.2	8.5	48.7	37.2	11.5	24.8	17.7	7.1	
2	14	F	58.3	56.4	1.9	39.2	35.2	4	20.8	16.2	4.6	
3	20	F	63.1	45.5	17.6	40.1	28.6	11.5	23.7	16.3	7.4	
4	15	F	60	56.6	3.4	37.8	33	4.8	27.6	24.8	2.8	
5	16	F	56.8	52.4	4.4	35.7	31.1	4.6	19.6	17.7	1.9	
6	30	M	68.1	65.4	2.7	42.2	36.8	5.4	23.8	19.5	4.3	
7	27	F	58.7	46	12.7	40.6	26.4	14.2	20.5	10.8	9.7	
8	28	M	69.4	65.8	3.6	43.4	41.4	2	22	20.8	1.2	
9	30	F	64	56.5	7.5	42.2	36	6.2	27	20.4	6.6	
10	14	M	70.3	64.7	5.6	45.8	37.5	8.3	22.9	19.6	3.3	
11	18	F	65	59.3	5.7	42.1	36.7	5.4	26.5	21.8	4.7	
12	24	M	64.2	58.9	5.3	39.6	37.6	2	21.8	18.3	3.5	
13	33	F	65.3	52.4	12.9	42.1	30	12.1	25.1	16.6	8.5	
14	21	F	53.9	52.2	1.7	37.2	31.8	5.4	22.2	20.1	2.1	
15	19	F	64.5	56.2	8.3	45.5	35.8	9.7	25.8	17.1	8.7	
16	17	F	61.2	57.5	3.7	38.8	36.6	2.2	21.4	23.8	-2.4	
17	24	F	68.7	54.3	14.4	41.6	33.4	8.2	24.6	19.8	4.8	
18	19	F	58.3	41.6	16.7	37.7	26.2	11.5	18.9	12.9	6	
19	25	M	65.7	53.5	12.2	43	34.3	8.7	23.9	16.8	7.1	
20	20	F	55.9	45.4	10.5	34.8	29.3	5.5	22	16.2	5.8	
X	21, 6				7.97			7.16			4.89	

AC, affected condyle; F, female; M, male; MA, mandibular angle; ML, mandibular lingula; NC, normal condyle; SN, sigmoid notch. D.1, difference between AC to MA with NC to MA; D.2, difference between AC to ML with NC to ML; D.3, difference between AC to SN with NC to SN.

Table 3. Description of the average of differences in three variables, with confidence intervals and *t*- and *P*-values.

Variable	Mean difference	95% Confidence interval		Standard difference	<i>t</i>	df	Bonferroni adjusted <i>P</i> -Value
		Lower limit	Upper limit				
D1	0.805	-2.297	0.687	3.187	-1.130	19.000	0.818
D2							
D1	3.080	-4.843	-1.317	3.766	-3.658	19.000	0.005
D3							
D2	2.275	-3.264	-1.286	2.112	-4.817	19.000	0.0005
D3							

condyle from C to MA with normal condyle from C to MA) and D.3 (difference between affected condyle from C to SN with normal condyle from C to SN) ($P = 0.005$) (Table 3).

Finally, there was a significant difference between D.2 (difference between affected condyle from C to ML with normal condyle from C to ML) and D.3 (difference between affected condyle from C to SN with normal condyle from C to SN) ($P = 0.0005$) (Table 3).

Discussion

The purpose of this study was to determine how the condylar unit should be measured in patients with AUCH.

CBCT is a means of radiographic examination that is used in various areas of dentistry. It produces three-dimensional high-definition and contrast images of dental and maxillary structures. In addition, in evaluating the hard tissues of the maxillofacial region, it is gradually replacing medical helical computed tomography because it produces images of adequate quality that are associated with low doses of radiation exposure^{12–14}.

You et al. and Park et al. reported that the mandibular body begins at the mental foramen and extends to the mandibular foramen, which suggests that the start of the condylar unit is from the ML to the condylar head^{7,8}.

In this series of patients with AUCH, it can be observed that, as in other publications, it was more frequent in females (75%)^{9–11}. In regard to average differences, there were no significant differences when comparing D1 with D2 ($P = 0.818$). However, there was a significant difference when comparing D1 with D3 ($P = 0.005$) and also when comparing D2 with D3 ($P = 0.0005$).

The changes in the length of condylar unit on the affected side altered the position of the SN, moving it to a more cranial position; therefore, if the condylar unit is measured using the SN in AUCH, it is possible that no differences will be found in length due to a change of position of the SN, when there really is a difference^{15,16}.

Therefore, if the condylar unit is measured from SN in a patient with AUCH, it could appear like a normal condyle be-

cause SN has moved upward, leading to an incorrect diagnosis.

The ML is a reliable and easy point to identify on panoramic radiographs; therefore it can be used with conventional radiology also.

In summary, according to this research, it can be concluded that the ML is the lowest point of the condylar skeletal unit and is therefore a stable parameter that is useful for making measurements in patients with condylar hyperplasia. Thus, it ought to be considered as the reference point for measuring condylar height, contributing to diagnosis and the planning of treatment. In contrast, the NS is not a stable parameter in patients with asymmetry due to condylar hyperplasia, so it cannot be used to measure the condylar unit.

Funding

None

Competing Interests

None

Ethical Approval

This study was approved by the Hospital del Salvador ethics board

Patient Consent

Not required

References

- Melnik A. Cephalometric study of mandibular asymmetry in a longitudinally followed sample of growing children. *Am J Orthod Dentofac Orthop* 1992;**101**:355–66.
- Fariña R, et al. Correlation between single photon emission computed tomography, AgNOR count, and histomorphologic features in patients with active mandibular condylar hyperplasia. *J Oral Maxillofac Surg* 2011;**69**:356–61.
- Ricketts R. Cephalometric analysis and synthesis. *Angle Orthodont* 1961;**31**:141–56.
- Ricketts R. *Técnica bioprogressiva de Ricketts*. Buenos Aires, Argentina: Médica Panamericana; 1983. Capítulo 4.
- Abramovich A. *Embriología de la región máxilo-facial*. Buenos Aires, Argentina: Médica Panamericana; 1997: 192–207.

- Petrovic A, Stutzmann J, Outdet C. Control processes in postnatal growth of mandibular condyle cartilage. *Rev Iberoam Ortod* 1986;**6**:11–58.
- You K-H, Lee K-J, Lee S-H, Baik H-S. Three-dimensional computed tomography analysis of mandibular morphology in patients with facial asymmetry and mandibular prognathism. *Am J Orthod Dentofac Orthop* 2010;**138**:540. e1–540.e8.
- Park W, Kim BC, Yu HS, Yi CK, Lee SH. Architectural characteristics of the normal and deformity mandible revealed by three-dimensional functional unit analysis. *Clin Oral Investig* 2010. [Epub ahead of print]. Oct 13, 2009.
- Nitzan DW, Katsnelson A, Bermanis I, Brin I, Casap N. The clinical characteristics of condylar hyperplasia: experience with 61 patients. *J Oral Maxillofac Surg* 2008;**66**: 312–8.
- Fariña R, Pintor F, Pérez J, Pantoja R, Berner D. Low condylectomy as the sole treatment for active condylar hyperplasia: facial, occlusal and skeletal changes. An observational study. *Int J Oral Maxillofac Surg* 2015;**44**: 217–25.
- Fariña R, Olate S, Raposo A, Araya A, Alister JP, Uribe F. High condylectomy versus proportional condylectomy: is secondary orthognathic surgery necessary? *Int J Oral Maxillofac Surg* 2016;**45**:72–7.
- De Vos W, Casselman J, Swennen GR. Cone-beam computerized tomography (CBCT) imaging of the oral and maxillofacial region: a systematic review of the literature. *Int J Oral Maxillofac Surg* 2009;**38**:609–25.
- Scarfe WC, Farman AG. What is cone-beam CT and how does it work? *Dent Clin North Am* 2008;**52**:707–30.
- Miracle AC, Mukherji SK. Cone beam CT of the head and neck, part 1: physical principles. *Am J Neuroradiol* 2009;**30**:1088–95.
- Momjian A. Reliability of computational measurement of the condyles on digital panoramic radiographs. *Dentomaxillofac Radiol* 2011;**40**:444–50.
- Di Blasio A, Pedrazzi G, Anghinoni M, Sesenna E. How does the mandible grow after early high condylectomy? *J Craniofac Surg* 2015;**26**:764–71.

Address:
Rodrigo Fariña S.
Av. Providencia 2330 appt 23
Santiago
Chile
cod post: 7510052
E-mail: rofari@gmail.com