

## CASE REPORT / ПРИКАЗ БОЛЕСНИКА

# Lateral periodontal cyst simulating a residual cyst

Daniela Adorno-Farias<sup>1,2</sup>, Frederico Sampaio Neves<sup>3</sup>, Bráulio Carneiro Júnior<sup>1</sup>, Jean Nunes dos Santos<sup>4</sup><sup>1</sup>Federal University of Bahia, School of Dentistry, Salvador, Bahia, Brazil;<sup>2</sup>University of Chile, School of Dentistry, Department of Oral Pathology and Medicine, Santiago, Chile;<sup>3</sup>Federal University of Bahia, School of Dentistry, Department of Oral and Maxillofacial Radiology, Salvador, Bahia, Brazil;<sup>4</sup>Federal University of Bahia, School of Dentistry, Department of Propaedeutics and Integrated Clinic, Surgical Pathology Laboratory, Salvador, Bahia, Brazil**SUMMARY**

**Introduction** Lateral periodontal cysts (LPC) are not frequent and the diagnosis is generally established by means of a routine radiological exploration.

The aim of this article is to report a case of LPC on edentulous area.

**Case outline** A 59-year-old man was referred with an extensive radiolucent cystic lesion on edentulous area of anterior maxilla, with a clinical and radiographic diagnosis of residual cyst. The histopathologic features exhibited a diagnosis of LPC.

**Conclusion** This is the third case of LPC reported in the literature, which describes a different clinical and radiographic aspect than proposed in the literature.

**Keywords:** lateral periodontal cyst; residual cyst; edentulous area

**INTRODUCTION**

Lateral periodontal cysts (LPC) comprise about 0.4% of all odontogenic cysts and since the last classification the World Health Organization (WHO) they have been defined as odontogenic cysts located beside or lateral to a vital tooth, whose inflammatory cause has been excluded [1–6]. This cyst originates from the remnants of odontogenic epithelium [4].

Histologically, it consists of a fibrous cystic wall lined by a nonkeratinized squamous cuboidal epithelium, comprising from one to five layers of cells [3–10]. It is also characterized by the presence of composite plaques epithelial cells and clear cells, rich in glycogen [5, 6, 7]. Some publications show a male predilection [2, 5–8]. These lesions are more common in adults during the fifth to seventh decades of life [8], and are located in the mandibular premolar area [1]. Radiographically, LPCs are mostly radiolucent, unilocular, oval- or teardrop-shaped lesions, located between the roots of vital teeth and are circumscribed by a sclerotic halo [7–11].

Although according to the WHO LPC must be adjacent the root of a tooth pulp vitality, we describe a case of residual LPC whose histopathology was essential for determining its nature [4].

**CASE REPORT**

A 59-year-old man was referred to us because of an asymptomatic lesion in the oral cavity

with a six-month history of evolution. The intraoral examination showed the presence of swelling in the edentulous part of the anterior left segment of the maxilla, 1 cm in size, of soft consistency. The periapical and panoramic radiographs (Figures 1 and 2) revealed a well-circumscribed unilocular ovoid radiolucent area, extending from periapical area, at the nasal cortical level, to the alveolar process, which approximately measured 2.3 × 1.5 cm in size. Erosion or expansion of the cortical bone was not observed. With these clinical and radiographic characteristics a presumptive diagnosis of residual cyst was reached. After excisional biopsy, the histopathologic features exhibited multiple cystic spaces lined by squamous atrophic epithelium, consisting mainly of cuboidal cells exhibiting vacuoles in the basal layer and some clear cells. The fibrous cystic wall showed subepithelial hyalinization and protrusions into the lumen (Figures 3 and 4). On the basis of these findings, a diagnosis of LPC was made.

**DISCUSSION**

Most publications about LPC are case or series reports with few patients, and studies of jaw cysts in the last ten years have still been reporting low frequency of this pathology, ranging 0.12–1.7%, with a slight male preference, in patients with a wide age range (21–82 years), predominantly located in the premolar area of the mandible [1, 2, 12–17]. Being a small cyst in clinical practice, diagnosed in many cases

Примљено • Received:

September 2, 2016

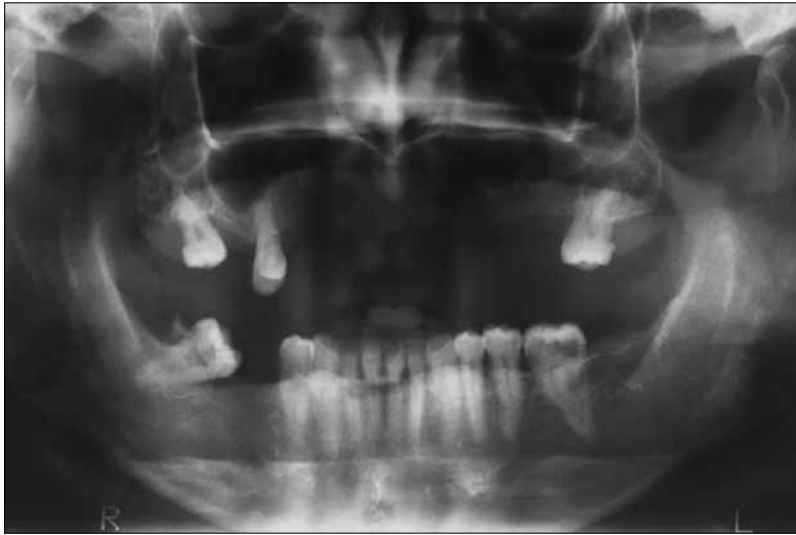Прихваћено • Accepted:

June 9, 2016

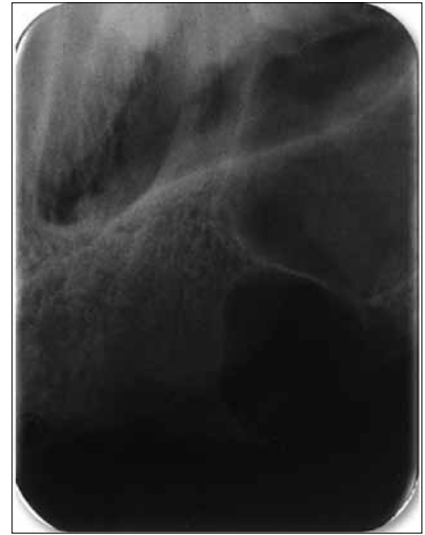Online first: June 13, 2017

Correspondence to:

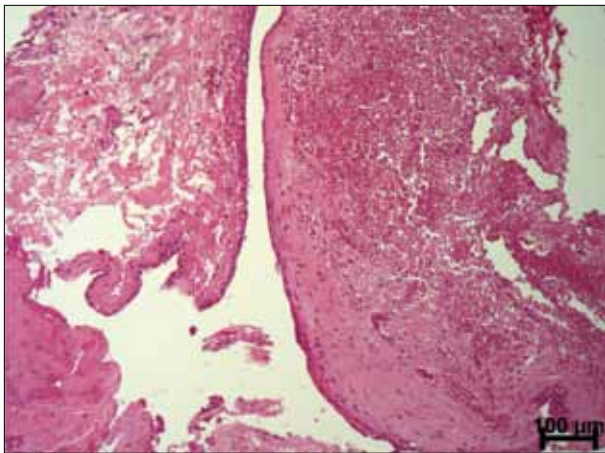
Daniela ADORNO-FARIAS  
Av. Araújo Pinho, 62 – 9º andar –  
Canela  
CEP: 40110-150 Salvador, Bahia  
Brasil  
[daniadorno@gmail.com](mailto:daniadorno@gmail.com)



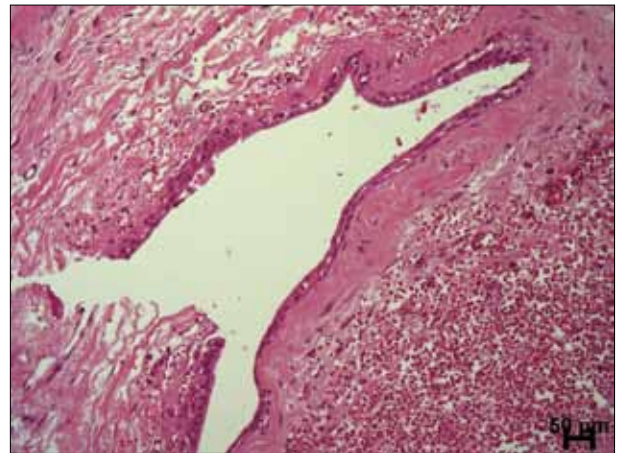
**Figure 1.** Panoramic radiographic view of a well circumscribed radiolucency in the anterior maxilla; a presumptive diagnosis of residual cyst was made



**Figure 2.** Detail of the radiolucent lesion, which extends to the cortical alveolar process



**Figure 3.** Cystic cavity lined by squamous epithelial cells, bleeding area in the fibrous wall and protrusion into the lumen



**Figure 4.** Presence of hyalinization of the capsule and a few clear cells

in a routine radiographic examination, this case differs from the WHO concept and previous studies because of the clinical and radiographic findings [1, 2–11].

To our knowledge, this case appears to be the second one reporting an LPC in the edentulous region, simulating residual cyst. The cyst presented in the maxilla differs from the previous study of Mendes and van der Waal [11] that showed two residual LPC in the mandible. Although the usual location of LPC is mandible, when they occur in the maxilla they show a predilection for the anterior region, as in the case presented [1, 4].

It is important to note that despite the LPC reported in this work was oval in shape, differing from the residual cysts, which tend to be circular, it was larger than reported in the literature, which described lesions smaller than 1 cm [1, 4, 8, 9]. LPC may in some cases exhibit different behavior, with great growth potential. In addition, the behavior of this cyst is difficult to determine because of its low frequency [8].

Histopathological aspects of this case fulfil the preconditions for the LPC diagnosis [1, 3–11]. Our attention was caught by the presence of hyalinization in the capsule and by protrusions into the cystic lumen (Figure 4), which are not seen in radicular cyst.

The most appropriate treatment for this cyst is a complete surgical enucleation with low tendency to recurrence [1, 4]. As the reported LPC is larger than usual, a follow-up checkup every six months was recommended, with radiographic monitoring, because of a possible tendency to recurrence of this particular case.

The LPC described here is in accordance with Mendes and van der Waal [11] in the sense that clinical and radiographic features should hold less importance than histological ones in future characterizations of this cyst in the literature, as histopathologic features were essential to the conclusion of this case.

## REFERENCES

1. Shear M, Speight PM. Cysts of the oral and maxillofacial regions. 4th ed. Oxford: Blackwell Munksgaard, 2007.
2. Jones AV, Craig GT, Franklin CD. Range and demographics of odontogenic cysts diagnosed in a UK population over a 30-year period. *J Oral Pathol Med.* 2006; 35(8):500–7.
3. de Andrade M, Silva AP, de Moraes Ramos-Perez FM, Silva-Sousa YT, da Cruz Perez DE. Lateral periodontal cyst: report of case and review of the literature. *Oral Maxillofac Surg.* 2012; 16(1):83–7.
4. Kramer IRH, Pindborg JJ, Shear M. WHO Histological Typing of Odontogenic Tumours. 2nd ed. Geneva: Springer-Verlag. 1992:34–118.
5. Kerezoudis NP, Donta-Bakoyianni C, Siskos G. The lateral periodontal cyst: aetiology, clinical significance and diagnosis. *Endod Dent Traumatol.* 2000; 16(4):144–50.
6. Cohen DA, Neville BW, Damm DD, White DK. The lateral periodontal cyst. A report of 37 cases. *J Periodontol.* 1984; 55(4):230–4.
7. Rasmusson KG, Magnusson BC, Borrmann H. The lateral periodontal cyst. A histopathological and radiographic study of 32 cases. *Br J Oral Maxillofac Surg.* 1991; 29(1):54–7.
8. Carter LC, Carney YL, Perez-Pudlewski D. Lateral periodontal cyst. Multifactorial analysis of a previously unreported series. *Oral Surg Oral Med Oral Pathol Oral Radiol Endod.* 1996; 81(2):210–6.
9. Siponen M, Neville BW, Damm DD, Allen CM. Multifocal lateral periodontal cysts: a report of 4 cases and review of the literature. *Oral Surg Oral Med Oral Pathol Oral Radiol Endod.* 2011; 111(2):225–33.
10. Formoso Senande MF, Figueiredo R, Berini Aytés L, Gay Escoda C. Lateral periodontal cysts: a retrospective study of 11 cases. *Med Oral Patol Oral Cir Bucal.* 2008; 13(5):E313–7.
11. Mendes RA, van der Waal I. An unusual clinicoradiographic presentation of a lateral periodontal cyst—report of two cases. *Med Oral Patol Oral Cir Bucal.* 2006; 11(2):E185–7.
12. Tekkesin MS, Olgac V, Aksakalli N, Alatlı C. Odontogenic and nonodontogenic cysts in Istanbul: analysis of 5088 cases. *Head Neck.* 2012; 34(6):852–5.
13. Nuñez-Urrutia S, Figueiredo R, Gay-Escoda C. Retrospective clinicopathological study of 418 odontogenic cysts. *Med Oral Patol Oral Cir Bucal.* 2010; 15(5):767–73.
14. De Souza LB, Gordón-Núñez MA, Nonaka CF, de Medeiros MC, Torres TF, Emiliano GB. Odontogenic cysts: demographic profile in a Brazilian population over a 38-year period. *Med Oral Patol Oral Cir Bucal.* 2010; 15(4):583–90.
15. Mosqueda Taylor A, Irigoyen Camacho ME, Diaz Franco MA, Torres Tejero MA. Odontogenic cysts. Analysis of 856 cases. *Medicina Oral.* 2002; 7(2):89–96.
16. Procktt AP, Schebela CR, Maito FD, Sant'Ana-Filho M, Rados PV. Odontogenic Cysts: Analysis of 680 Cases in Brazil. *Head and Neck Pathol.* 2008; 2(3):150–6.
17. Ochsenius G, Escobar E, Godoy L, Peñafiel P. Odontogenic Cysts: Analysis of 2.944 cases in Chile. *Med Oral Patol Oral Cir Bucal.* 2007; 12(2):85–91.

## Латерална периодонтална циста изгледа резидуалне цисте

Данијела Адорно-Фаријас<sup>1,2</sup>, Фредерико Сампаио Невес<sup>3</sup>, Браулио Карнеиро Жуниор<sup>1</sup>, Жеан Нунес дос Сантос<sup>4</sup>

<sup>1</sup>Државни универзитет Баије, Стоматолошки факултет, Салвадор, Баија, Бразил;

<sup>2</sup>Универзитет Чилеа, Стоматолошки факултет, Катедра за оралну патологију и медицину, Сантијаго, Чиле;

<sup>3</sup>Државни универзитет Баије, Стоматолошки факултет, Катедра за оралну и максилофацијалну радиологију, Салвадор, Баија, Бразил;

<sup>4</sup>Државни универзитет Баије, Стоматолошки факултет, Катедра за пропедевтику и Интегрисана клиника, Хируршка патохистолошка лабораторија, Салвадор, Баија, Бразил

### САЖЕТАК

**Увод** Латералне периодонталне цисте (ЛПЦ) нису честе, а дијагноза се поставља најчешће радиолошким прегледом. Циљ овог рада је да прикаже болесника са ЛПЦ у безубој регији.

**Приказ болесника** Код мушкарца старог 59 година нађена је велика цистична радиолуцентна промена у безубој регији у предњем делу горње вилице и постављена клиничка и

радиолошка дијагноза резидуалне цисте. Патохистолошки преглед је потврдио дијагнозу ЛПЦ.

**Закључак** Ово је трећи описани случај ЛПЦ, који по клиничким и радиографским аспектима одступа од претходно описаних случајева.

**Кључне речи:** латерална периодонтална циста; резидуална циста; безуба регија