

See discussions, stats, and author profiles for this publication at: <https://www.researchgate.net/publication/321377215>

Graftless Maxillary Sinus Lift Using Lateral Window Approach: A Systematic Review

Article in *Implant Dentistry* · November 2017

DOI: 10.1097/ID.0000000000000695

CITATIONS

2

READS

141

6 authors, including:



Marcelo Parra

Universidad de La Frontera

5 PUBLICATIONS **3** CITATIONS

[SEE PROFILE](#)



Claudia Atala-Acevedo

Universidad de La Frontera

6 PUBLICATIONS **8** CITATIONS

[SEE PROFILE](#)



Rodrigo Fariña

Hospital del Salvador, universidad de chile

55 PUBLICATIONS **108** CITATIONS

[SEE PROFILE](#)



Ziyad S Haidar

University of the Andes (Chile)

60 PUBLICATIONS **346** CITATIONS

[SEE PROFILE](#)

Some of the authors of this publication are also working on these related projects:



Oral Surgery [View project](#)



Nanoncology [View project](#)



Graftless Maxillary Sinus Lift Using Lateral Window Approach: A Systematic Review

Marcelo Parra, DDS,* Claudia Atala-Acevedo, DDS,† Rodrigo Fariña, DDS, MS,‡
Ziyad S. Haidar, DDS, MSc, MBA, PhD,§ Carlos Zaror, DDS, MS,¶ and Sergio Olate, DDS, MS, PhD||

The maxillary sinus lift, described by Tatum¹ and modified by Boyne et al,² is a recognized and versatile surgical technique in the treatment of the posterior region of the maxilla. Various accesses have been used to perform this procedure, with crestal approach and the lateral window approach being the most frequent.³

A wide variety of materials have been used as bone grafts in the maxillary sinus lift, shown similar success rates, both in the stability of the reconstruction and in the stability of the implants.⁴ Current analyses indicate that the success of the technique also is associated not only with the

Purpose: The aim was to determine the survival rate of dental implants installed in the posterior region of the maxilla after a graftless maxillary sinus lift via the lateral window approach and to identify the factors involved in the results.

Materials and Methods: A systematic search was done on MEDLINE, EMBASE, LILACS, Scopus, and Science Direct up to June 2016; additional studies were identified through an analysis of references. Primary studies in English, Spanish, Portuguese, and French were included; the selection and data extraction process was conducted by 2 investigators independently, and the methodological quality was evaluated by means of the Effective Public

Health Practice Project's Quality Assessment Tool.

Results: The combined search identified 232 articles. After the selection process, 11 articles were identified, 9 of which were prospective and 2 were retrospective. In all of them, the graftless maxillary sinus lift was done with the immediate installation of the implant. All the studies included presented a low methodological quality. The mean survival rate of the implants was 97% with an average new intrasinus bone formation of 6.2 mm.

Conclusion: This technique has a high implant survival although it is not possible to identify its correct indication and contraindication. (Implant Dent 2017;26:1–8)

Key Words: bone graft, dental implants, blood

*Student, Master in Dental Sciences Program, Department of Dentistry, Dental School, Universidad de La Frontera, Temuco, Chile.

†Research Assistant, Department of Pediatric Dentistry and Orthodontics, Faculty of Dentistry, Universidad de La Frontera, Temuco, Chile; Research Assistant, Center for Research in Epidemiology, Economics and Oral Public Health (CIEESPO), Faculty of Dentistry, Universidad de La Frontera, Temuco, Chile.

‡Assistant Professor, Department of Oral and Maxillofacial Surgery, Faculty of Dentistry, Universidad de Chile, Santiago, Chile. Consultant, Department of Oral and Maxillofacial Surgery, Hospital del Salvador, Santiago, Chile.

§Head, BioMATX Research Group, Dental School, Universidad de Los Andes, Santiago, Chile; Research Professor, Program in BioMedicine, CIB-PMI Faculty of Medicine, Universidad de los Andes, Santiago, Chile.

¶Assistant Professor, Department of Pediatric Dentistry and Orthodontics, Faculty of Dentistry, Universidad de La Frontera, Temuco, Chile; Head, Center for Research in Epidemiology, Economics and Oral Public Health (CIEESPO), Faculty of Dentistry, Universidad de La Frontera, Temuco, Chile; Assistant Research, Faculty of Dentistry, Universidad San Sebastián, Puerto Montt, Chile.

||Associated Professor, Center for Morphological and Surgical Research (CEMYQ), Universidad de La Frontera, Temuco, Chile.

Reprint requests and correspondence to: Sergio Olate, DDS, MS, PhD, Universidad de La Frontera, Claro Solar 115, Oficina 414-A, Temuco 4780000, Chile, Phone: +56 45 2325000, Fax: +56 45 2325001, E-mail: sergio.olate@ufrontera.cl

ISSN 1056-6163/17/02606-001

Implant Dentistry

Volume 26 • Number 6

Copyright © 2017 Wolters Kluwer Health, Inc. All rights reserved.

DOI: 10.1097/ID.0000000000000695

reconstruction material but also with other variables, such as the osteogenic potential of the sinus membrane⁵ and the bone characteristics of the zone.⁶ In this sense, techniques for the immediate or delayed implant installation have shown that the use of the autogenous bone graft or the use of biomaterials could be equally as efficient.⁷

In recent years, reports on new intrasinus bone formation without graft installation or bone substitute have increased since Lundgren et al,⁸ subsequent to the removal of an intrasinus

cyst, observed new bone formation in the space left without the installation of any type of material. Later, Lundgren et al⁹ performed maxillary sinus lifts on 11 patients with no type of bone graft, so that the space generated after lifting the sinus membrane would only be filled with the patient's blood, immediately installing 19 implants, all successfully.

Although there are clinical studies that use this technique, there are no analyses that assess the prognostic factors related to their survival. The

aim of this systematic review is to determine the survival rate of dental implants installed in the posterior region of the maxilla after a graftless maxillary sinus lift using the lateral window approach and to identify the factors involved in these results.

MATERIALS AND METHODS

Protocol and Eligibility Criteria

A systematic literature review was carried out to respond to the research question: What is the survival rate of dental implants installed in the posterior region of the maxilla simultaneously or after a graftless maxillary sinus lift, and what are the factors associated with their survival?

The inclusion criteria for the articles were: (1) primary studies, (2) published in English, Spanish, Portuguese or French, (3) performed on humans, and (4) evaluated maxillary sinus lifts performed with the lateral window approach. Secondary studies, case studies or series of cases with a sample of fewer than 5 individuals, studies that used autogenous bone or biomaterials in the sinus lift, and sinus lifts using other surgical techniques were excluded. The report was prepared according to the Preferred Reporting Items for Systematic reviews and Meta-Analyses.¹⁰

Sources of Information and Search Strategy

A systematic search was done on MEDLINE, EMBASE y LILACS, from January 1995 to June 2016. The search string used on MEDLINE was: (([maxillary sinus augmentation] OR maxillary sinus lift) OR "Sinus Floor Augmentation"[Mesh]) AND ([blood clot] OR "Blood"[Mesh] OR graftless). The search was complemented by a manual review of the references from the articles included.

Study Selection and Data Extraction

The title and abstract of the studies identified in the search were selected independently by 2 calibrated reviewers (M.P. and C.A.-A.). In case of differences between the reviewers, consensus was reached by discussion or in consultation with a third reviewer

(C.Z., S.O.). The reviewers were not blinded to the authors or journals.

The data were collected by 2 authors independently (M.P., C.A.-A.) using a predefined and standardized form of data extraction, including information on the study design, country where it was carried out, number of patients, presence or absence of adjacent teeth, installation time of the implants, number of implants installed, implant loading time, follow-up time, assessment method, number of successful implants, and new bone formation as a result of the maxillary sinus lift. A

pilot test was used to homogenize criteria between reviewers. Any discrepancy was resolved by discussion or in consultation with a third reviewer (C.Z., S.O.). Grey literature was not reviewed systematically.

Study Variables

The primary variable was the survival rate of the dental implants loaded in the posterior region of the maxilla after a graftless maxillary sinus lift, defined as the functioning presence of the implant 6 months after loading. As a secondary variable, bone formation as a result of the

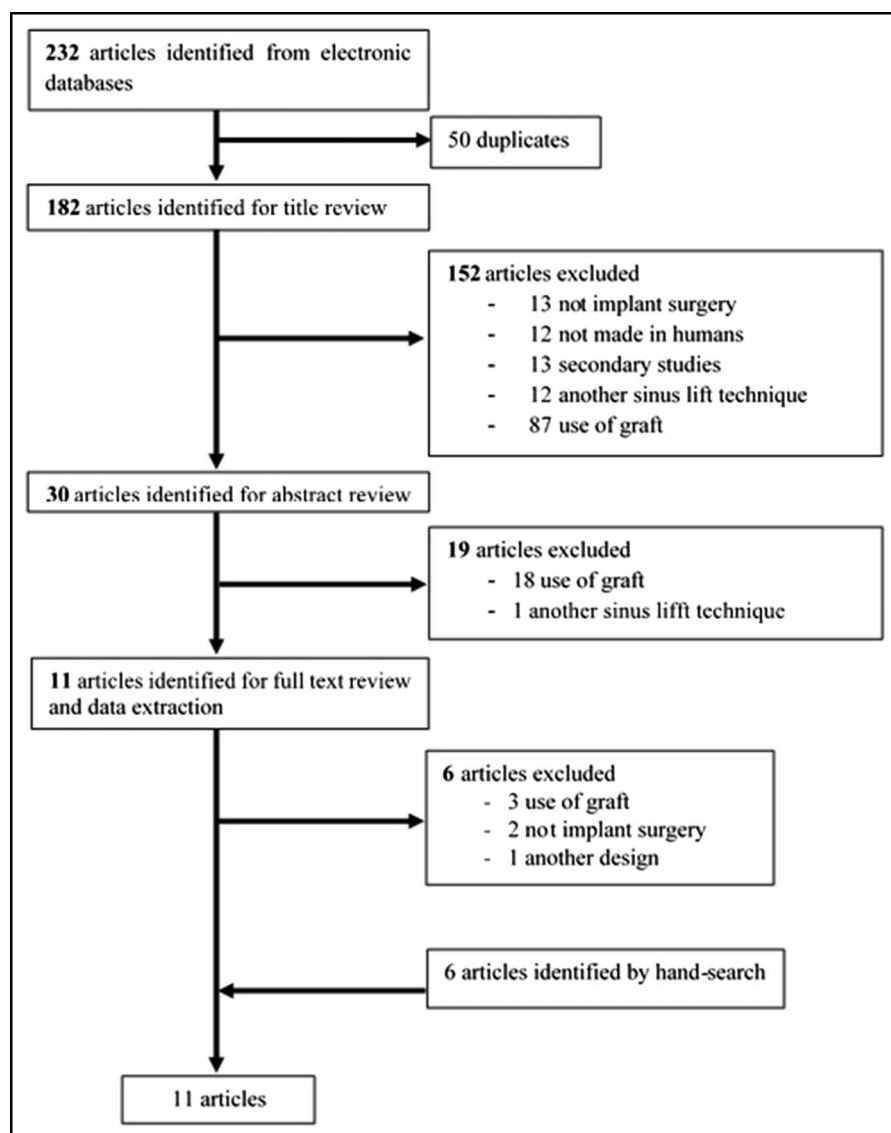


Fig. 1. Flow chart of the systematic review, including 232 articles evaluated initially with their inclusion and exclusion criteria. After exclusion of 50 duplicates articles and evaluations of the other articles, 11 articles were included in this review, coming from the systematic search (6 articles) and the hand search (6 articles).

Table 1. Characteristics of the 11 Studies Included in This Research, Related to Main Characteristics of the Demographical Situation, Design of the Studies, Anatomical Characteristics and Condition for Implant Surgery and Bone Formation

Author	Country	Study Design	No. Patients	No. Men	No. Women	Adjacent Teeth Presence	Immediate Implant	No. of Implants, Brand
Lungdren et al ⁹	Sweden	Prospective	11	2	9	Yes	Yes	19, TiUnite, Nobel Biocare 10–15 and 3.75 mm of diameter
Hatano et al ¹⁹	Japan	Prospective	6	1	5	No	Yes	14, TiUnite, MK III, Nobel Biocare AB
Thor et al ²⁰	Sweden	Prospective	20	9	11	No	Yes	44, Astra tech 4.5–5 mm of diameter
Chen et al ¹⁷	Taiwan	Retrospective	33	23	10	No	Yes	47
Balleri et al ²¹	Italy	Prospective	15	11	4	Yes	Yes	28, Osseospeed, Astra Tech
Moon et al ²²	Korea	Prospective	14	9	5	No	Yes	31, SybronPRO XRT. 13 × 4.1
Cricchio et al ²³	Sweden and Italy	Prospective	84	46	38	No	Yes	239, TiUnite (Nobel Biocare AB)
Lin et al ¹⁶	Taiwan	Prospective	44	26	18	Yes	Yes	80, ITI, Straumann; SwissPlus.
Bassi et al ²⁵	Brazil	Prospective	20	—	—	Yes	Yes	25, Neodent 4.3 × 13
Cara-Fuentes et al ¹⁸	Spain	Retrospective	26	11	15	Yes	Yes	38, Neodent 4.3 × 13
Falah et al ²⁶	Israel	Prospective	18	8	10	Yes	Yes	72

Author	Average No. Implants per Patient	Type of Graft	Loading Time, mo	Follow up, mo	Evaluation Method	Average Bone Formation	Survival Rate
Lungdren et al ⁹	2	Blood clot	6	18	CBCT	Does not measure height	100%
Hatano et al ¹⁹	2	Blood clot	6	12 a 24	Periapical Radiograph	10.0 mm	92%
Thor et al ²⁰	2	Blood clot	6	48	Panoramic and Retroalveolar Radiographs	6.51 mm	98%
Chen et al ¹⁷	1	Blood clot	9	24	Panoramic Radiograph and CBCT	4.5 mm	100%
Balleri et al ²¹	2	Blood clot	6	12	Periapical Radiograph	5.5 mm	100%
Moon et al ²²	2	Blood clot	6 a 8	25	Panoramic Radiograph and CBCT and Histological	7.84 mm	93%
Cricchio et al ²³	3	Blood clot	6	12 a 72	Panoramic Radiograph and CBCT	5.3 mm	99%
Lin et al ¹⁶	2	Blood clot	9	60	Panoramic Radiograph and CBCT	7.44 mm	100%
Bassi et al ²⁵	1	Blood clot	9	3 y 51	CBCT	5.63 mm	96%
Cara-Fuentes et al ¹⁸	1	Blood clot	6	30 a 70	Panoramic and Periapical Radiographs	2.7 mm	97%
Falah et al ²⁶	4	Blood clot	6	18	Panoramic Radiograph and CBCT	6.14 mm	94%

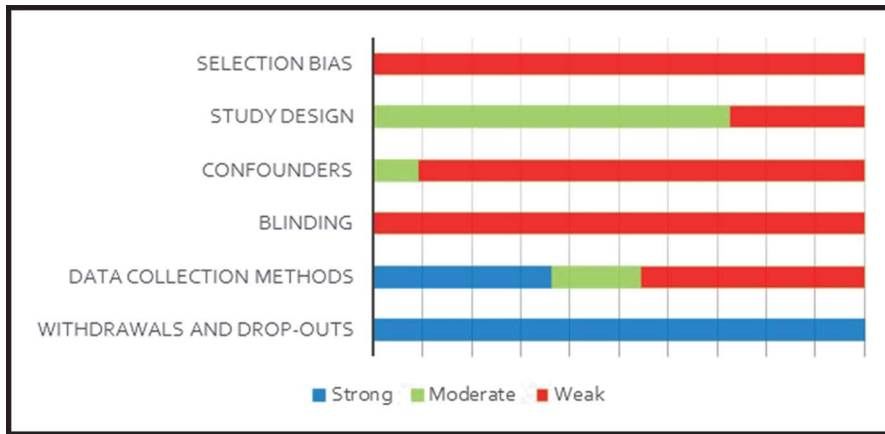


Fig. 2. Risk of bias in the 11 articles included in this research, showing weak, moderate and strong power in different areas of the analysis in each article. The weak power was detected in 4 areas and the strong power was detected in only an area. All the studies obtained at least 2 domains rated as weak, being considered as weak due to the high risk of bias they present.

maxillary sinus lift was established from the study of images captured with x-ray or computed tomography.

The prognostic factors evaluated were: (a) Integrity of the sinus membrane at the time of its lifting, (b) Presence or absence of adjacent teeth, (c) Minimum alveolar rim before the surgery, and (d) Installation time of the implants.

Risk of Bias in the Individual Studies

To assess the risk of bias in the studies, the Effective Public Health Practice Project's Quality Assessment Tool¹¹ was used, which contains 6 domains: selection bias, study design, confounders,

blinding, data collection methods, and withdrawals and dropouts. The overall grading for each study was identified as strong when no component was weak, moderate when only one component was weak, and weak when 2 or more components were described as weak.

RESULTS

Study Selection

The combined search identified 232 references. After excluding 50 duplicates, and based on a review of titles and abstracts, 11 articles were evaluated in

full text, and 5 potentially relevant articles were excluded after reading the full text.^{12–16} After a manual review of the articles, 11 articles were ultimately included. Figure 1 shows the flow chart of the selection of the studies (Fig. 1).

Characteristics of the Studies

Table 1 summarizes the characteristics of the studies included. Two were retrospective^{17,18} and 9 were prospective.^{9,19–26} The dental implants were installed simultaneously with the sinus lift in all the studies included. The mean size of the study samples was 58 implants and ranged from 14 to 239 implants. In 6 studies, there were teeth adjacent to the zone of the maxillary sinus lift and implant installation; in other 5 studies, the procedure was performed in completely edentulous zones.

The waiting time before loading the installed implants was 6 months in 7 articles^{6,18–21,23,26} and 9 months in 4 studies.^{17,22,24,25} With respect to the assessment method, 2 studies only used tomographies, 5 tomographies and panoramic x-rays, 1 only with retroalveolar x-rays, and 4 with panoramic and retroalveolar x-rays. Two studies performed a histological analysis on part of the study sample.

Risk of Bias in the Studies

The evaluation of the risk of bias in the studies included is reported in

Table 2. Characteristics of the Dental Implants Used in the 11 Studies Included in This Research, Showing the Company, Implant Design, and Surface Treatment

Author	Brand	Implant Design	Surface Treatment
Lungdren et al ⁹	Branemark System, TiUnite, Nobel Biocare AB	Conical	Titanium Oxide Layer
Hatano et al ¹⁹	Branemark System, TiUnite, Nobel Biocare AB	Conical, external hexagon connection	Titanium Oxide Layer
Thor et al ²¹	Astra Tech AB	Conical	Titanium Dioxide
Chen et al ²²	ITI; Straumann	Cylindrical	Titanium Sandblast (SLA)
Balleri et al ²¹	Osseospeed, Astra Tech	Conical, internal hexagon connection	Fluoride ions
Moon et al ²²	SybronPRO XRT	Conical	Hydroxyapatite Particles
Cricchio et al ²³	Branemark System, TiUnite, Nobel Biocare AB	Conical	Titanium Oxide Layer
Lin et al ¹⁶	Frialit-2 Friadent	Conical	Sandblast and Acid Etching
Bassi et al ²⁵	Alvim; Neodent	Conical, double thread, morse cone connection	Neopores between 2.5 and 5.0 μm over the entire surface of the implant
Cara-Fuentes et al ¹⁸	Zimmer SPB, SPWB y TSV	Conical	Microtexturized
Falah et al ²⁶	MIS Implants Technologies	Conical	Sandblast and Acid Etching

Figure 2. In relation to selection bias, all the studies were classified as weak for including nonprobability sampling of consecutive cases or for convenience sampling, which is not adequately representative of the participants. This can cause an imbalance in some characteristics relevant to the participants like age, type of bone atrophy or nutritional and general health status, which can influence the results. The study design was rated mainly moderate for being mostly descriptive cohorts without a control group. No study was rated as strong because no controlled clinical trials were identified. With respect to the control of confounders, only 2 studies controlled the confounding factors in the statistical analysis; however, they did not include all the relevant variables. In terms of blinding, as it is not possible to blind the treating professional, it was considered that the patients and the evaluators did not know the research question; however, no study is reported to have done this, and in some cases, the same professional even evaluated the results. Half of the studies reported using validated methods to evaluate the primary result although not all showed evidence that they were reliable. Finally, withdrawals and dropouts were the best evaluated domains, as the dropouts did not exceed 20% of the sample. In the case of the retrospective studies, this domain was not included for the overall assessment. All the studies obtained at least 2 domains rated as weak, so they were rated as weak due to the high risk of bias they present (Fig. 2).

Implant Survival Rate

The survival rate fluctuated between 92% and 100%. Only 3 articles reported a survival below 95% and in 4 studies a survival of 100% was obtained.^{6,17,21,24} The average among the studies was 97% (Table 1). In relation to the type of implants used in the studies, 10 used conical implants, 1 study used cylindrical implants,¹⁷ and all reported some type of surface treatment (Table 2).

With respect to the installation protocol for the implants, the description of the protocols was limited in the publications analyzed. After the sinus

floor lift, Cricchio et al²³ indicated milling depending on the residual height of the alveolar rim using the final drill 2.85 mm in diameter to prepare the bone bed. Lundgren et al,⁶ to place implants 3.75 mm in diameter, also used the 2.85 mm diameter drill as the final drill. Thor et al²⁰ and Falah et al²⁶ used a similar protocol.

With respect to the causes of implant failure reported in the studies, Moon et al²² indicated that the reason for failure in their implants was an inadequate primary stability and appeared in sites with a bone height lower than the sample, which was also reported by Falah et al,²⁶ where of the 4 implants lost, 3 were associated with an inadequate primary stability, and one with deficiencies in osseointegration after loading. Cricchio et al²³ report the loss of two implants, after loading, attributing the loss to an incomplete osseointegration of the implants, without providing detailed reasons. In the studies where no reason was given for the failure, direct communication with the authors made it possible to define the condition, where Hatano et al¹⁹ indicated failure associated with a short healing period in the phase before loading (4 months), whereas Falah et al²⁶ described the failure as being related to deficiencies in primary stability.

Vertical Bone Gain

The average new bone formation associated with the graftless maxillary sinus lift was 6.2 mm, where 1 study¹⁸ presented 2.7 mm, 3 studies^{17,21,23} between 4.5 and 5.5 mm, 3 studies^{20,25,26} between 5.6 and 6.5 mm, 2 studies^{22,24} between 6.6 and 8.0 mm, and one study¹⁹ 10 mm of new bone formation.

With respect to the presence of teeth adjacent to the sinus lift area, the data are not clear in cases where there are teeth adjacent^{18,21,24–26} to the maxillary sinus. An average bone gain of 5.48 mm was observed, and in the sites where there were no adjacent teeth,^{17,19,20,22,23} an average bone gain of 6.83 mm was observed.

Among the analyzed studies, there were 2^{22,26} in which, in addition to evaluating the survival rate and amount of newly formed bone, histological studies

were conducted, being consistent in the results that indicated the presence of abundant new bone formation, osteoid tissue, without presence of inflammatory tissue, formation of trabecular bone, and the presence of active osteoblasts.

DISCUSSION

Traditionally, indications for the immediate installation of implants with a maxillary sinus lift have suggested a minimum height of 5 mm³, considering the use of some material to fill the lifted area with the implant. With these conditions, Lundgren et al⁸ installed 93 dental implants in atrophic maxillae, previously performing maxillary sinus lifts with autografts in one group and with biomaterials in another, finding a survival rate of 98%. Likewise, Beretta et al²⁷ installed 589 implants in 246 sinus lifts with bone graft, reporting a survival rate of 98.3%.

The findings of this review indicate that the survival rate of the implants installed after a graftless maxillary sinus lift is close to 97%, with 100% survival being observed in 4 studies.^{6,17,21,24} However, the articles were classified mainly as weak, which implies doubts about the factors associated with the survival of the treatment. In terms of patient selection, clinical aspects used in the inclusion of subjects were not reported or not included; therefore, despite the success of the treatment, the criteria for the indication of the technique cannot be identified. Similarly, in the case of implants that failed, it was not possible to identify the reasons why it happened, so future investigations must consider these issues.

When analyzing the implant installation protocols, we can see that there was mainly a preparation with the final perforation of lower caliber than the conventionally used protocol. This option has been described in other investigations²⁸ as a strategy for the sites where the bone quality is mainly type III or IV. This option has demonstrated success in terms of improving the contact between implant and bone

and to ensure an adequate primary stability of the implant installed, contributing to osseointegration.²⁹

In relation to the type of implant used, we can see that in all the studies included in this investigation, conical implants were used with surface treatment. Apparently, the surface type is important in this technique because it has been indicated that the surface could have chemotactic effects,³⁰ permitting the establishment of relevant cell structures at the secondary stability or biological stability stage, thus having a positive effect on the osseointegration process.²⁹ The surface, in contact with blood, could affect the new bone formation³⁰ such that the surface treatment could be one of the most important elements in the development of this technique.

Biological factors such as the presence of adjacent teeth,³¹ quality of surrounding bone,³² quality of the sinus membrane,³³ and space available for filling³⁴ can be relevant at the time of the indication and the studies conducted reveal limitations in such descriptions, so it is not possible to confirm the correct indication of the technique on the basis of our results. Thus, previous studies that have shown failures in the graftless maxillary sinus lift⁶ have reported that a large sinus volume could be characterized as a critical defect and the type of implant could be important in the results of the technique; however, based on the existing information, it is not possible to identify the impact of these variables. Despite these doubts, implant survival is high and similar to results observed in alveolar rims that have not been grafted²⁶ and in maxillary sinus sites with filling.⁷

The vertical bone gain in this technique was high in most of the studies, confirming that some intrinsic factors of the maxillary sinus contribute to the stability and integration of the implants.⁵ The existing new bone formation was generally observed at the upper limit of the implant, which demonstrates that the presence of the implant has influence on the intrasinus bone formation, with an average bone gain of 6.2 mm being observed.

The value of the quality of the clot formed directly influences the new bone formation. Gurtner et al¹⁸ indicated that stem cells, anchor elements, and growth factors are essential in the bone regeneration process, so the osteogenic potential of the sinus membrane and the bone next to the implant as an anchor element would seem to be key elements in the success of the technique. In this sense, previous studies where the maxillary sinus lift technique was done without a bone graft in highly atrophic sinuses and without the installation of implants demonstrated limitations in new bone formation, reaching on average only 1.5 mm⁶.

Although all the articles reviewed measured the new bone conditions by analyzing vertical bone gain, not all did so with validated or standardized instruments, which is considered a shortcoming from the methodological point of view. Similarly, success factors that include esthetic results cannot be identified in the studies included.

One recent systematic review published by Duan et al³⁵ indicated that maxillary sinuses subjected to a lift via a transcrestal approach and via a lateral window approach presented a high implant survival with an average bone gain of 3.8 mm. The 2 techniques are completely different, where the lateral window presents a greater biological demand compared to the transcrestal access, which in the opinion of the present authors, are not comparable. The exclusive approach of maxillary sinus lift via lateral window, as proposed in the present study, involves a conceptual and biological analysis on the variables installed in the new intrasinus bone formation, which in the average of the articles in this review is 6.2 mm, double that reported by Duan et al³⁵; the transcrestal access is designed for smaller requirements of a sinus floor lift,³⁶ whereas the access via lateral window is designed for greater requirements so that they are not comparable in either the bone formation or in the stability of the implants.

Limitations of this study are associated with the possibility that not all

the studies available were identified given that not all the existing databases were explored; however, we believe that the systematic nature of the review and the sensitive search strategies used likely identified the great majority of the studies available. The quality of the review is based on the published literature and therefore it is limited by the amount and quality of the published information available. Because the technique is recent, all the identified studies were included that presented a low methodological quality with inadequate designs to evaluate the success of an intervention. On the other hand, it was not possible to meta-analyze the main study variables due to the absence of available data and/or the existing clinical heterogeneity existing between studies included in this review.

CONCLUSION

Based on our results, the value of the variables associated with implant survival and new bone formation in this treatment have not been identified, so that new studies should be oriented to these topics. Despite the high survival observed, it is not possible to identify the correct indication for the technique, although the new bone formation observed opens new possibilities for future analyses in intrasinus bone regeneration.

DISCLOSURE

The authors claim to have no financial interest, either directly or indirectly, in the products or information listed in the article.

APPROVAL

Approval was received by the Ethical Committee in Research, "Universidad de La Frontera," Chile. (Protocol 027/14).

ROLES/CONTRIBUTIONS BY AUTHORS

M. Parra, DDS: Formal analysis, investigation, critical analysis, and writing. C. Atala-Acevedo, DDS:

Formal analysis, investigation, and critical analysis. R. Fariña, DDS, MS: Critical evaluation, review, and editing. Z. Haidar, DDS, MSc, MBA, PhD: Critical evaluation, review, and editing. C. Zaror, DDS, MS: Project administration, design of research, and investigation. S. Olate, DDS, MS, PhD: Conceptualization, investigation, review, and editing.

REFERENCES

- Tatum H Jr. Maxillary and sinus implant reconstruction. *Dent Clin North Am*. 1986;30:207–229.
- Boyne PJ, James RA. Grafting of the maxillary sinus floor with autogenous marrow and bone. *J Oral Surg*. 1980;38:613–616.
- Stern A, Green J. Sinus lift procedures: An overview of current techniques. *Dent Clin North Am*. 2012;56:219–233.
- Xavier SP, Silva ER, Kahn A, et al. Maxillary sinus grafting with autograft versus fresh-frozen allograft: A Split-mouth evaluation of bone volume dynamics. *Int J Oral Maxillofac Implants*. 2015;30:1137–1142.
- Srouji S, Ben-David D, Lotan R, et al. The innate osteogenic potential of the maxillary sinus (Schneiderian) membrane: An ectopic tissue transplant model simulating sinus lifting. *Int J Oral Maxillofac Surg*. 2010;39:793–801.
- De Oliveira GR, Olate S, Cavalieri-Pereira L, et al. Maxillary sinus floor augmentation using blood without graft material. Preliminary results in 10 patients. *J Oral Maxillofac Surg*. 2013;71:1670–1675.
- Santagata M, Tozzi U, Tartaro G, et al. Maxillary sinus augmentation with autologous and heterologous bone graft: A clinical and radiographic report of immediate and delayed implant placement. *J Maxillofac Oral Surg*. 2014;13:401–408.
- Lundgren S, Andersson S, Sennerby L. Spontaneous bone formation in the maxillary sinus after removal of a cyst: Coincidence or consequence? *Clin Implant Dent Relat Res*. 2003;5:78–81.
- Lundgren S, Andersson S, Gualini F, et al. Bone reformation with sinus membrane elevation: A new surgical technique for maxillary sinus floor augmentation. *Clin Implant Dent Relat Res*. 2004;6:165–173.
- Moher D, Liberati A, Tetzlaff J, et al. Preferred reporting items for systematic reviews and meta-analyses: The PRISMA statement. *Ann Intern Med*. 2009;151:264–269.
- Effective Public Health Practice Project. *Quality Assessment Tool for Quantitative Studies*. Hamilton, ON: Effective Public Health Practice Project; 1998. Available at: <http://www.ehphp.ca/index.html>.
- Barone A, Ricci M, Grassi RF, et al. A 6-month histological analysis on maxillary sinus augmentation with and without use of collagen membranes over the osteotomy window: Randomized clinical trial. *Clin Oral Implants Res*. 2013;24:1–6.
- Cakir M, Karaca IR, Firat A, et al. Experimental evaluation of the effects of ankaferd blood stopper and collagenated heterologous bone graft on bone healing in sinus floor augmentation. *J Oral Maxillofac Surg*. 2014;72:63–64.
- Jung YS, Chung SW, Nam W, et al. Spontaneous bone formation on the maxillary sinus floor in association with an extraction socket. *Int J Oral Maxillofac Surg*. 2007;36:656–657.
- Lambert F, Léonard A, Drion P, et al. Influence of space-filling materials in subantral bone augmentation: Blood clot vs. autogenous bone chips vs. bovine hydroxyapatite. *Clin Oral Implants Res*. 2011;22:538–545.
- Srouji S, Gasper R, Gustavo M. Maxillary sinus floor elevation following simultaneous implant installation without graft material. *Int J Oral Maxillofac Surg*. 2013;42:1268.
- Chen TW, Chang HS, Leung KW, et al. Implant placement immediately after the lateral approach of the trap door window procedure to create a maxillary sinus lift without bone grafting: A 2-year retrospective evaluation of 47 implants in 33 patients. *J Oral Maxillofac Surg*. 2007;65:2324–2328.
- Cara-Fuentes M, Machuca-Ariza J, Ruiz-Martos AM, et al. Long-term outcome of dental implants after maxillary augmentation with and without bone grafting. *Med Oral Patol Oral Cir Bucal*. 2016;21:229–235.
- Hatano N, Sennerby L, Lundgren S. Maxillary sinus augmentation using sinus membrane elevation and peripheral venous blood for implant-supported rehabilitation of the atrophic posterior maxilla: Case series. *Clin Implant Dent Relat Res*. 2007;9:150–155.
- Thor A, Sennerby L, Hirsch JM, et al. Bone formation at the maxillary sinus floor following simultaneous elevation of the mucosal lining and implant installation without graft material: An evaluation of 20 patients treated with 44Astra tech implants. *J Oral Maxillofac Surg*. 2007;6:64–72.
- Balleri P, Veltri M, Nuti N, et al. Implant placement in combination with sinus membrane elevation without biomaterials: A 1-year study on 15 patients. *Clin Implant Dent Relat Res*. 2012;14:682–689.
- Moon JW, Sohn DS, Heo JU, et al. New bone formation in the maxillary sinus using peripheral venous blood Alone. *J Oral Maxillofac Surg*. 2011;69:2357–2367.
- Cricchio G, Sennerby L, Lundgren S. Sinus bone formation and implant survival after sinus membrane elevation and implant placement: A 1- to 6-year follow-up study. *Clin Oral Implants Res*. 2011;22:1200–1212.
- Lin IC, Gonzalez AM, Chang HJ, et al. A 5-year followup of 80 implants in 44 patients placed immediately after the lateral trap door window procedure to accomplish maxillary sinus elevation without bone grafting. *Int J Oral Maxillofac Implants*. 2011;26:1079–1086.
- Bassi AP, Pioto R, Faverani LP, et al. Maxillary sinus lift without grafting, and simultaneous implant placement: A prospective clinical study with a 51-month follow-up. *Int J Oral Maxillofac Surg*. 2015;44:902–907.
- Falah M, Sohn DS, Srouji S. Graftless sinus augmentation with simultaneous dental implant placement: Clinical results and biological perspectives. *Int J Oral Maxillofac Surg*. 2016;45:1147–1153.
- Beretta M, Poli PP, Grossi GB, et al. Long-term survival rate of implants placed in conjunction with 246 sinus floor elevation procedures: Results of a 15-year retrospective study. *J Dent*. 2015;43:78–86.
- Anitua E, Murias-Freijo A, Alkhraisat MH. Implant site under-preparation to compensate the remodeling of an autologous bone block graft. *J Craniofac Surg*. 2015;26:374–377.
- Shadid RM, Sadaqah NR, Othman SA. Does the implant surgical technique affect the primary and/or secondary stability of dental implants? A systematic review. *Int J Dent*. 2014;2014:204838.
- Boyan BD, Cheng A, Olivares-Navarrete R, et al. Implant surface design regulates mesenchymal stem cell differentiation and maturation. *Adv Dent Res*. 2016;28:10–17.
- Pradeep AR, Bajaj P, Rao NS, et al. Platelet-rich fibrin combined with a porous hydroxyapatite graft for the treatment of three-wall intrabony defects in chronic periodontitis: A randomized controlled clinical trial. *J Periodontol*. 2012;83:1472–1479.
- Shibayama Y, Nishimoto M, Nakata K. Microvascular events in bone marrow relates to developer of and recovery from bone atrophy in thiotepa-

treated rats. *Exp Toxicol Pathol*. 1993;45:129–133.

33. Nolan PJ, Freeman K, Kraut RA. Correlation between Schneiderian membrane perforation and sinus lift graft outcome: A retrospective evaluation of 359 augmented sinus. *J Oral Maxillofac Surg*. 2014;72:47–52.

34. De Moraes P, Costa VOC, Olate S, et al. Morphometric study of maxillary sinus by computed tomography. Assessment of sinus floor bone reconstruction. *Int J Morphol*. 2009;30:592–598.

35. Duan DH, Fu JH, Qi W, et al. Graft-free maxillary sinus floor elevation: A

systematic review and meta-analysis. *J Periodontol*. 2017;88:550–564.

36. Lundgren S, Cricchio G, Hallman M, et al. Sinus floor elevation procedures to enable implant placement and integration: Techniques, biological aspects and clinical outcomes. *Periodontol*. 2000;2017:103–120.