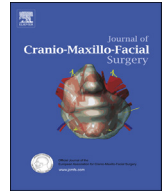



Contents lists available at ScienceDirect

Journal of Cranio-Maxillo-Facial Surgery

journal homepage: www.jcmfs.com

Characterization of the orbital volume in normal population

Patricio Andrades ^{a,b,*}, Pedro Cuevas ^b, Rodrigo Hernández ^a, Stefan Danilla ^b,
Rodrigo Villalobos ^a

^a Division of Maxillofacial Surgery, Hospital del Trabajador, Santiago, Chile

^b Division of Plastic Surgery, Department of Surgery, Hospital Clínico de la Universidad de Chile, Santiago, Chile



ARTICLE INFO

Article history:

Paper received 3 March 2017

Accepted 6 February 2018

Available online 14 February 2018

Keywords:

Orbital volume

Measurement

Orbital fracture

ABSTRACT

Introduction: The aim of the study was to describe the normal orbital volume and its most important relationships with other clinical variables.

Methods: We designed a correlation study and consecutive normal CTs scans were included. Orbital volume and facial anthropometrics were measured and correlated between them. Two independent and blind observers made all the measurements. Uni and multivariate statistical analysis were performed in order to create a predicting model for orbital volume.

Results: A total of 199 consecutive patients were included in the study (398 orbits). The mean Orbital Volume (OV) was 24.5 ± 3.08 cc. Adequate intra and interobserver reliability was observed. There were no differences between the right and left orbit ($p=0.73$). The male average OV was 24.9 ± 3.03 cc, the female OV was 23.9 ± 3.08 cc. Age group analysis demonstrated a slow increase in OV beyond thirty years, but these differences were not significant ($p=0.98$). Only the age, total facial height, facial width and the interorbital distance were significant and were included in the predictive model of OV.

Conclusion: We have characterized the normal orbital volume, variations and associations. In order to further advance in the understanding of the clinical implications the abnormal orbital volume must be fully studied.

© 2018 European Association for Cranio-Maxillo-Facial Surgery. Published by Elsevier Ltd. All rights reserved.

1. Introduction

In cases of maxillofacial trauma, orbital fractures are among the most challenging and complex fractures to treat (Friesenecker et al., 1995; Meyer et al., 1998; Hollier and Thornton, 2002; Manolidis et al., 2002). Ocular dystopia after orbital fracture may be due to an increase in bony orbital volume and/or scarring of the soft tissue surrounding the orbital globe (Hawes and Dortzbach, 1983; Manson et al., 1986a; Waterhouse et al., 1999; Hartstein and Roper-Hall, 2000; Burnstine, 2002; Gellrich et al., 2002). The loss of the structural bone and ligament support, reshaping of orbital soft tissue under the influence of gravity, and the forces of scar contracture remodeling are the main mechanisms for post-traumatic enophthalmia (Manson et al., 1986b; Ramieri et al., 2000). The association between orbital volume (OV) and ocular

dystopia has been previously evaluated (Bite et al., 1985; Charteris et al., 1993; Whitehouse et al., 1994; Schuknecht et al., 1996; Ploder et al., 2002; Neuschwander et al., 2005). Many studies have found a positive correlation between OV and the degree of enophthalmus — for each 1 cc increase in OV there is approximately 1 mm of enophthalmus (Fan et al., 2003). This is the reason why measurement of OV in patients with orbital fractures has been used to predict possible future enophthalmia and thus help in the surgical decision-making process (Raskin et al., 1998; Ahn et al., 2008.).

Currently there is no large-scale population study that describes normal orbital volume, its normal variations, and its relationships with other variables such as age, sex, and cephalic anthropometry. Moreover, there is no evidence about the diagnostic and therapeutic implications of pathological orbital volume. Early detection of patients with risk factors for developing post-traumatic orbital complications is essential for the proper selection of patients who will require surgery. Consequently, the aim of this study was to describe the normal orbital volume and its most important relationships with other clinical variables in order to help us in the surgical decision-making process.

* Corresponding author. Division of Plastic Surgery, Department of Surgery, Hospital Clínico Universidad de Chile, Santos Dumont N° 999, Sector B, Tercer piso, Independencia, Santiago, Chile.

E-mail address: pandrades@uchile.cl (P. Andrades).

2. Material and methods

2.1. Design and patients

We designed a correlation study, and sampling was conducted using the radiology database of the Hospital del Trabajador de Santiago. The sample was stratified by age and sex, according to the population pyramid for Chile. We selected consecutive computed tomographies (CTs) of patients reported as normal by the radiologist. Review board permissions were obtained from our institutions and all the patients signed informed consent forms in order to participate in the study.

2.2. Measurements

The dependent variable was orbital volume measured from CTs of healthy patients. These measurements were made using Extended Brilliance Workspace V 3.0.1 2012 (Phillips Healthcare, Best, The Netherlands), based on a previously described method (Kolk et al., 2007, 2008). The procedure comprises five stages. The first is getting a symmetrical three-dimensional image scan for better alignment and comparison. Second, the cursor is used to measure orbital volume using the software's filling option and multiplanar selection. The upper, lower, lateral, and medial limits are determined by the bony walls of the orbit. The anterior orbital boundary is defined by the orbital rim, including the anterior lachrymal crest. Finally, the posterior boundary is defined by the most anterior portion of the optic canal, being an area that rarely fractures and is easily located in the CTs (Fig. 1).

To better understand orbital anatomy and its implications in orbital trauma and reconstruction, we have identified three areas in the orbital cavity. We believe that these three areas show different behaviors in traumatized orbits and therefore differ in their

importance in the clinical consequences of post-traumatic disorder. The volumes of these areas were measured in each case, and the relationship between the volume of each to the overall volume of the orbit under study was analyzed. The anterior zone extended from the previously defined orbital rim, to the first coronal slice containing the anterior border of the inferior orbital fissure. The central zone was considered from the rear edge of the previous area, to the coronal section that identifies the orbital process of the palatine bone. This area includes the key area described by Hammer (Forbes et al., 1985). The posterior zone extended from the boundary of the previous area to the most anterior portion of the optic canal (Fig. 2).

The relationships of the independent variables with OV were assessed. Demographic variables were age and gender. Variables measured using the CTs were: total facial height (distance between the glabella and menton); midfacial height (distance between the glabella and sub-nasal point); facial width (larger, horizontal, bizygomatic distance); skull base (distance between Sella and nasion); transverse dimension of the skull (larger horizontal bi-temporal distance); external interorbital distance (between the most lateral point of both bony orbits); intercanthal distance (between the inner edges of the internal palpebral fissure); canthal index (intercanthal distance as a percentage of external interorbital distance).

All the measurements were made by two independent and blind observers. Each observer performed two measurements of each variable, separated by 30 days. They had previously undergone a training program in order to improve the learning curve.

2.3. Statistics

The sample size for a correlation study requires approximately 20 observations per independent variable. There were nine independent variables, giving a total of 180 patients (360 orbits).

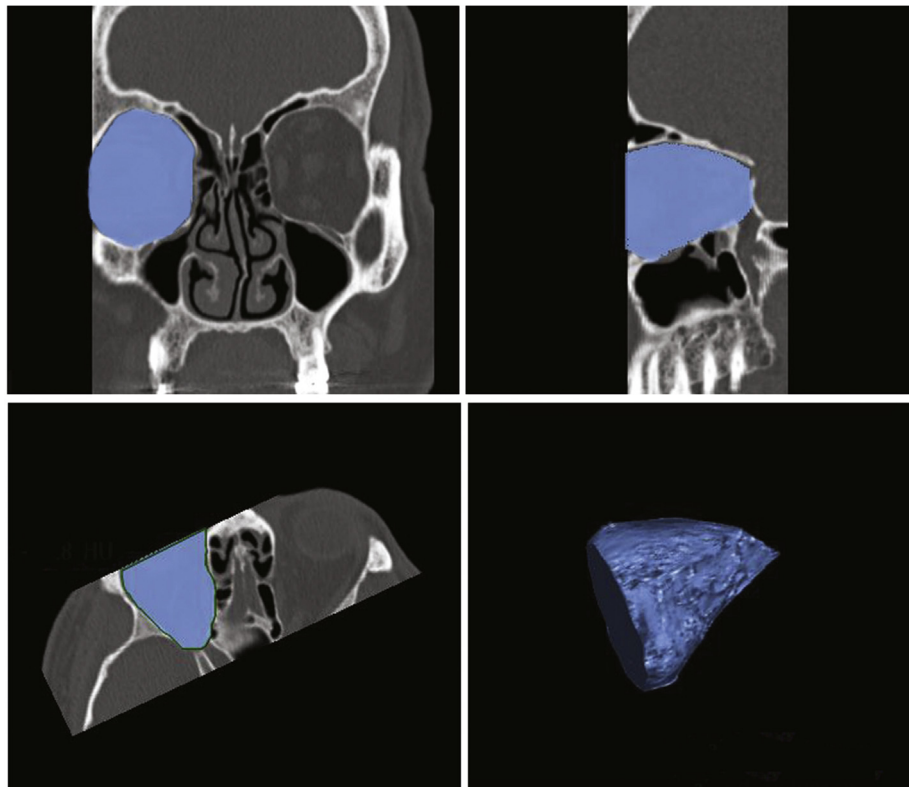


Fig. 1. Limits of the normal orbital volume for CT measurements (see text for details).

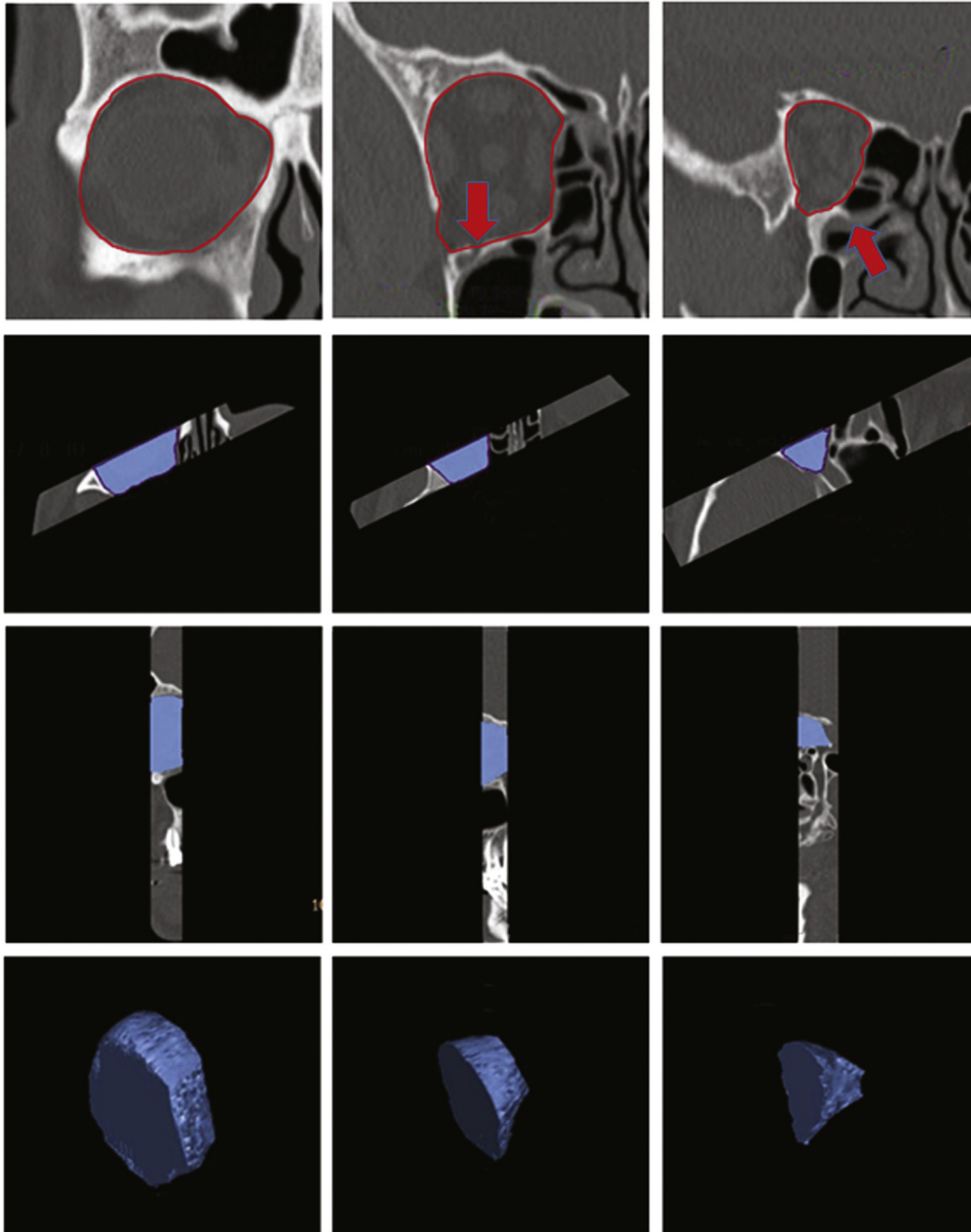


Fig. 2. The orbital volume was divided into three areas based on different behaviors of the fractured orbital floor: anterior, central, and posterior (see text for details).

Descriptive statistics were performed using histograms to illustrate the distribution of the dependent variable. Measurements were summarized by mean and standard deviation. The correlation between continuous variables was measured using the Pearson coefficient. A Student's *t*-test was used to compare means, and a multiple linear regression model was used to assess whether OV was determined by the independent variables and to create a formula that might predict normal OV.

3. Results

A total of 199 consecutive patients were included in the study (Table 1). There were 119 males (59.8%) and 80 females (40.2%), with a mean age of 38.4 ± 14.9 years (range 15–84). All the patients'

CTs underwent a protocol performed by two independent observers. Each observer carried out two OV measurements on the right side and two on the left side, with a total number of 1592 measurements. The right OV intraobserver variability was $r = 0.978$ ($p < 0.0001$) for observer 1 and $r = 0.678$ ($p < 0.0001$) for observer 2. The left OV intraobserver variability was $r = 0.982$ ($p < 0.0001$) for observer 1 and $r = 0.959$ ($p < 0.0001$) for observer 2. Meanwhile, the OV interobserver variability for the right side was $r = 0.869$ ($p < 0.0001$) and for the left side was $r = 0.981$ ($p < 0.0001$).

The OV analysis by side, gender, and age is shown in Table 2. The mean global OV was 24.5 ± 3.08 cc with a range of 16.9–35 cc. The data demonstrated a normal distribution. The mean OV for the right side was 24.45 ± 3.09 cc and for the left side was 24.56 ± 3.29 cc ($p = 0.73$). Average OV was 24.9 ± 3.03 cc for males and

Table 1
Patient characteristics.

Studied population, $n = 199$			
Characteristics	Mean	SD	Range
Age (years)	38.5	14.9	15–84
Gender	n	(%)	
- Female	80	(40.2)	
- Male	119	(59.8)	

23.9 ± 3.08 cc for females ($p = 0.010$). Age group analysis demonstrated a slow increase in OV beyond 30 years ($p = 0.98$). The mean volumes by side for each orbital area (anterior, central, and posterior) are shown in Table 3. The anterior orbital zone global mean volume was 17.30 ± 2.6 cc, the central orbital zone global mean volume was 5.40 ± 1.77 cc, and the posterior orbital zone mean global volume was 2.00 ± 0.64 cc.

Table 4 summarizes the anthropometric face measurements for the studied population and their correlation with the global OV. Mean total facial height was 133.39 ± 10.09 mm ($r = 0.381$, $p < 0.0001$). Mean midfacial height was 64.39 ± 3.55 mm ($r = 0.231$, $p = 0.001$). Mean facial width was 109.77 ± 5.99 mm ($r = 0.520$, $p < 0.0001$). Mean skull base distance was 61.39 ± 4.1 mm ($r = 0.257$, $p = 0.0002$). The mean transversal dimension of the skull was 132.48 ± 7.41 mm ($r = 0.257$, $p = 0.0002$). The mean internal intercanthal distance was 20.24 ± 2.76 mm ($r = 0.503$, $p = 0.480$). Finally, the mean interorbital distance was 99.24 ± 4.17 mm ($r = 0.488$, $p < 0.0001$).

Table 5 shows the multivariate regression model and the formula for predicting OV. Within the studied variables only age, total facial height, facial width, and the interorbital distance were statistically significant, and were included in the predictive model for OV. This formula allowed us to create a smartphone application

named *Orbital-V*, which is available for free in Google Play and App Store.

4. Discussion

Normal anatomy is defined as the morphological characteristics most frequently seen in the population that guarantee an optimal function. In humans there is great variability in this normal anatomy, but these morphological variations almost never compromise function. The statistical and physiological criteria involved in this definition allow us to better understand characteristics that are abnormal, infrequent, and deviated from the standard (Schubert et al., 1990). Characterizing a normal structure is essential in setting limits for average values, to comprehend its function, and to recognize its relationships to other normal structures. A deep understanding of normality makes studying abnormality an easier task. This was the main purpose of our study — to thoroughly describe the normal OV, as well as its different components, relations, and clinical implications.

While the ideal study for determining patterns of normality is the cross-sectional study, it is considered to be inefficient in economic terms. Obtaining a representative random sample of the general population would have been very difficult, and taking a CT scan of all individuals would have resulted in extremely elevated costs. In our study, consecutive normal head and neck CT scans were included and 398 orbits were measured. A standardized CT scan technique considered to be the reference standard for OV calculation was used. In various experimental studies using silicone model skulls and liquid measurements, this technique had an accuracy greater than 95%, with a high correlation (Bentley et al., 2002; Cunningham et al., 2005; Tahernia et al., 2009; Oh et al., 2013). In our study, measurements were made by two independent radiology technicians, completing a total of 1592 measurements with high intra- and interobserver variability. This

Table 2
Global mean orbital volume by side, gender, and age.

	Mean orbital volume (cc)	Standard deviation	Range of maximum volume (cc)	
Global	24.50	3.08	16.90–35.00	
Right side	24.45	3.09	16.70–33.80	$p = 0.73$
Left side	24.56	3.29	17.10–36.30	
Male	24.91	3.03	18.80–35.03	$p = 0.010$
Female	23.89	3.08	16.88–30.91	
Age <20	24.05	3.25	16.90–28.90	$p = 0.980$
Age 20–30	23.58	2.28	20.01–27.66	
Age 30–40	25.11	3.45	20.65–31.53	
Age 40–50	25.48	3.66	19.50–35.04	
Age 50–60	25.64	3.09	19.78–30.65	
Age >60	26.20	2.95	21.00–30.96	

Table 3
Mean volume by orbital zone.

	Mean (cc)	Standard deviation	Range (cc)	Pearson correlation
Anterior zone				
- Global	17.30	2.60	9.40–25.60	$r = 0.823$
- Right volume	17.27	2.63	10.40–25.60	$p = 0.0001$
- Left volume	17.40	2.69	9.40–24.20	
Central zone				
- Global	5.40	1.77	2.20–12.30	$r = 0.750$
- Right volume	5.49	1.77	2.20–11.40	$p = 0.0001$
- Left volume	5.30	1.76	2.20–12.30	
Posterior zone				
- Global	2.00	0.64	0.90–4.40	$r = 0.509$
- Right volume	2.00	0.65	0.90–3.80	$p = 0.0001$
- Left volume	2.01	0.62	0.90–4.40	

Table 4
Anthropometric assessment of the face and correlations with global orbital volume (OV).

	Mean (mm)	Standard deviation	Range (mm)	Pearson correlation with OV
Facial height	133.39	10.09	77.40–155.20	$r = 0.381$ $p < 0.0001$
Mid facial height	64.39	3.55	55.80–74.40	$r = 0.231$ $p = 0.0010$
Facial width	109.77	5.99	96.20–123.40	$r = 0.520$ $p < 0.0001$
Skull base distance	61.39	4.10	50.70–73.20	$r = 0.257$ $p = 0.0002$
Internal intercanthal distance	20.24	2.76	13.15–27.15	$r = 0.503$ $p = 0.480$
Interorbital distance	99.24	4.17	88.20–111.20	$r = 0.488$ $p < 0.0001$
Transversal midventricular distance	132.48	7.41	108.40–157.70	$r = 0.257$ $p = 0.0002$

Table 5
Multivariate regression model and prediction of orbital volume.

Variable	Coef.	Std. error	$p > t$
- Age	0.0395	0.0028	0.046
- Facial height	0.0468	0.0002	0.003
- Facial width	0.158	0.0043	0.017
- Interorbital distance	0.134	0.0149	0.070

Orbital volume = (age \times 0.0395) + (facial height \times 0.0468) + (facial width \times 0.1587) + (interorbital distance \times 0.1347) – 14.

observation validates the method as an accurate and reliable technique for OV measurement.

Our results are similar to those from other small published series, using a variety of measuring methods, that have shown normal OV to be between 16 cc and 30 cc (Wang et al., 2008; Andrades et al., 2009; Acer et al., 2009; Noser et al., 2010). Interestingly, we observed a significant difference between male and female OV in the univariate analysis, but this difference was not statistically significant in the multivariate analysis. This does not mean that volume dissimilarities between males and females must not be taken into consideration from a clinical standpoint. The absence of gender as part of the predicting formula obtained in the multivariate analysis could be explained by the fact that gender differences are reflected in all the anthropometric measurements performed in the study. Age subgroup analysis also showed an interesting relationship with OV. Beyond 30 years, there was a steady increase in OV with age. Enlargement of OV with age is a new observation that may be explained by the bone resorption process that happens with aging. Although these differences were not significant in the univariate analysis, they reached statistical significance in the multivariate linear regression and were an important factor in the OV prediction formula.

We divided the orbit into three zones that have been implicated in different orbital globe dystopias (34). The anterior orbital zone has almost no influence on orbital globe position and represents 70.61% of the global OV. The central zone may cause a drop of the orbital globe or hypophthalmia when compromised, and represents 22.04% of the global OV. The posterior zone is implicated in the generation of enophthalmos and represents just an 8.16% of the global OV. Surprisingly, a modification of less than 30% of the posterior OV may cause orbital globe malposition due to the conical configuration of the orbit.

Almost all of the anthropometric variables studied showed a statistically significant positive correlation with OV. The only exception was intercanthal distance, which showed a low correlation with a non-significant p -value. Age, facial height, facial width, and interorbital distance were statistically significant in the multivariate analysis, and were included in the predictive model for

OV. This formula can allow you predict the normal OV with a ± 2.18 cc error in patients without a normal contralateral orbit to use as a reference. Although knowing the normal OV is important, no volume value is set as an absolute indication for surgery because of the large overlap in the ranges of OV differences. However, more important than a cutting value is the difference between values. For example, if the difference between the normal and fractured orbits is over 2 cc, an ocular dystopia of over 2 mm may be clinically observed, so this would help in deciding on surgery. Also, this difference may help us understand how much surgical correction is required, and also allow easier evaluation of postoperative results. To really incorporate these observations into clinical practice, a detailed understanding of the pathological OV is essential. We are now conducting a similar study of unilateral orbital fractures to better comprehend the abnormal pathological OV and its clinical implications.

5. Conclusion

In this study we have characterized normal OV, its variations, and its associations. Using these data, we have developed a formula that allows OV calculation with high precision, by considering the patients' age, facial height, facial width, and interorbital distance. To further advance understanding of the clinical implications of our study, the abnormal orbital volume must be fully studied.

Disclosure

This study was funded by a grant from the AO foundation. None of the authors had financial interests or commercial associations that posed or created a conflict of interest for this study.

References

- Acer N, Sahin B, Ergur H, Basaloglu H, Ceri CG: Stereological estimation of the orbital volume: a criterion standard study. *J Craniofac Surg* 20: 921–925, 2009
- Ahn HB, Ryu WY, Yoo KW, Park WC, Rho SH, Lee JH, et al: Prediction of enophthalmos by computer-based volume measurement of orbital fractures in a Korean population. *Ophthal Plast Reconstr Surg* 24: 36–39, 2008
- Andrades P, Hernandez D, Falguera MI, Millan JM, Heredero S, Gutierrez R, et al: Degrees of tolerance in post-traumatic orbital volume correction: the role of prefabricated mesh. *J Oral Maxillofac Surg* 67: 2404–2411, 2009
- Bentley RP, Sgouros S, Natarajan K, Dover MS, Hockley AD: Normal changes in orbital volume during childhood. *J Neurosurg* 96: 742–746, 2002
- Bite U, Jackson IT, Forbes GS, Gehring DG: Orbital volume measurements in enophthalmos using three-dimensional CT imaging. *Plast Reconstr Surg* 75: 502–508, 1985
- Burnstine MA: Clinical recommendations for repair of isolated orbital floor fractures: an evidence-based analysis. *Ophthalmology* 109: 1207–1210, 2002
- Cunningham LL, Peterson GP, Haug RH: The relationship between enophthalmos, linear displacement, and volume change in experimentally recreated orbital fractures. *J Oral Maxillofac Surg* 63: 1169–1173, 2005

- Charteris DG, Chan CH, Whitehouse RW, Noble JL: Orbital volume measurement in the management of pure blowout fractures of the orbital floor. *Br J Ophthalmol* 77: 100–102, 1993
- Fan X, Li J, Zhu J, Li H, Zhang D: Computer-assisted orbital volume measurement in the surgical correction of late enophthalmos caused by blowout fractures. *Ophthal Plast Reconstr Surg* 19: 207–211, 2003
- Forbes G, Gehring DG, Gorman CA, Brennan MD, Jackson IT: Volume measurements of normal orbital structures by computed tomographic analysis. *AJR Am J Roentgenol* 145: 149–154, 1985
- Friesenecker J, Dammer R, Moritz M, Niederdelmann HJ: Long-term results after primary restoration of the orbital floor. *J Craniomaxillofac Surg* 23: 31–33, 1995
- Gellrich NC, Schramm A, Hammer B, Rojas S, Cufi D, Lagrèze W, et al: Computer-assisted secondary reconstruction of unilateral posttraumatic orbital deformity. *Plast Reconstr Surg* 110: 1417–1429, 2002
- Hartstein ME, Roper-Hall G: Update on orbital floor fractures: indications and timing for repair. *Facial Plast Surg* 16: 95–106, 2000
- Hawes MJ, Dortzbach RK: Surgery on orbital floor fractures. Influence of time of repair and fracture size. *Ophthalmology* 90: 1066–1070, 1983
- Hollier L, Thornton J: Facial fractures I: upper two thirds. *Select Read Plast Surg* 9: 1–15, 2002
- Kolk A, Pautke C, Schott V, Ventrella E, Wiener E, Ploder O, et al: Secondary post-traumatic enophthalmos: high-resolution magnetic resonance imaging compared with multislice computed tomography in postoperative orbital volume measurement. *J Oral Maxillofac Surg* 65: 1926–1934, 2007
- Kolk A, Pautke C, Wiener E, Schott V, Wolff KD, Horch HH, et al: Isotropic proton-density-weighted high-resolution MRI for volume measurement of reconstructed orbital fractures — a comparison with multislice CT. *Magn Reson Imaging* 26: 1167–1174, 2008
- Manolidis S, Weeks BH, Kirby M, Scarlett M, Hollier L: Classification and surgical management of orbital fractures: experience with 111 orbital reconstructions. *J Craniofac Surg* 13: 726–737, 2002
- Manson PN, Clifford CM, Su CT, Iliff NT, Morgan R: Mechanisms of global support and posttraumatic enophthalmos: I. The anatomy of the ligament sling and its relation to intramuscular cone orbital fat. *Plast Reconstr Surg* 77: 193–202, 1986a
- Manson PN, Grivas A, Rosenbaum A, Vannier M, Zinreich J, Iliff N: Studies on enophthalmos: II. The measurement of orbital injuries and their treatment by quantitative computed tomography. *Plast Reconstr Surg* 77: 203–214, 1986b
- Meyer C, Groos N, Sabatier H, Wilk A: Long-term outcome of surgically treated orbital floor fractures. Apropos of a series of 242 patients. *Rev Stomatol Chir Maxillofac* 99: 149–154, 1998
- Neuschwander TB, Chang EL, Sadun AA: Hertel curve: orbital volume increment and proptosis in a cadaver model. *Ophthal Plast Reconstr Surg* 21: 431–434, 2005
- Noser H, Hammer B, Kamer L: A method for assessing 3D shape variations of fuzzy regions and its application on human bony orbits. *J Digit Imaging* 23: 422–429, 2010
- Oh SA, Aum JH, Kang DH, Gu JH: Change of the orbital volume ratio in pure blow-out fractures depending on fracture location. *J Craniofac Surg* 24: 1083–1087, 2013
- Ploder O, Klug C, Voracek M, Burggasser G, Czerny C: Evaluation of computer-based area and volume measurement from coronal computed tomography scans in isolated blowout fractures of the orbital floor. *J Oral Maxillofac Surg* 60: 1267–1272, 2002
- Ramieri G, Spada MC, Bianchi SD, Berrone S: Dimensions and volumes of the orbit and orbital fat in posttraumatic enophthalmos. *Dentomaxillofac Radiol* 29: 302–311, 2000
- Raskin EM, Millman AL, Lubkin V, della Rocca RC, Lisman RD, Maher EA: Prediction of late enophthalmos by volumetric analysis of orbital fractures. *Ophthal Plast Reconstr Surg* 14: 19–26, 1998
- Schubert W, Quillopa N, Shons AR: A study of orbital anatomy and volume for the correction of enophthalmos. *Surg Forum* 41: 597–601, 1990
- Schuknecht B, Carls F, Valavanis A, Sailer HF: CT assessment of orbital volume in late post-traumatic enophthalmos. *Neuroradiology* 38: 470–475, 1996
- Tahernia A, Erdmann D, Follmar K, Mukundan S, Grimes J, Marcus JR: Clinical implications of orbital volume change in the management of isolated and zygomaticomaxillary complex-associated orbital floor injuries. *Plast Reconstr Surg* 123: 968–975, 2009
- Waterhouse N, Lyne J, Urdang M, Garey L: An investigation into the mechanism of orbital blowout fractures. *Br J Plast Surg* 52: 607–612, 1999
- Wang YX, Tang YS, Shi J, Xu B: Experimental study of orbital volume using computer assisted technology. *Shanghai Kou Qiang Yi Xue* 17: 297–299, 2008
- Whitehouse RW, Batterbury M, Jackson A, Noble JL: Prediction of enophthalmos by computed tomography after 'blow out' orbital fracture. *Br J Ophthalmol* 78: 618–620, 1994