

# Does the Use of a “Walking Bleaching” Technique Increase Bone Resorption Markers?

C Bersezio • P Vildósola • M Sáez • F Sánchez • R Vernal • OB Oliveira Jr • G Jorquera  
J Basualdo • A Loguercio • E Fernández

## Clinical Relevance

Intracoronaral bleaching (nonvital bleaching) using a “walking bleaching” technique generates increased markers related to bone resorption.

## SUMMARY

**Objective:** This randomized clinical trial evaluated the effect of 35% hydrogen peroxide in comparison with 37% carbamide peroxide in a nonvital bleaching technique of “walking bleaching” (four sessions of treatment) on periodontal markers: nuclear factor kappa B-ligand (RANK-L—process of root resorption marker) and interleukin 1 $\beta$  (IL-1 $\beta$ —inflammatory response marker).

Cristian Bersezio, DDS, PhD, Department of Restorative Dentistry, Faculty of Dentistry, Universidad de Chile; PhD Program, Universidad de Estadual Paulista, Araraquara, Brazil and Universidad Andres Bello, Santiago, Chile

Patricio Vildósola, DDS, DS, PhD, Department of Restorative Dentistry, Faculty of Dentistry, Universidad de Chile and Universidad Andres Bello, Santiago, Chile

Mildri Sáez, DDS, Department of Restorative Dentistry, Faculty of Dentistry, Universidad de Chile, Santiago, Chile

Francisca Sánchez, DDS, Department of Restorative Dentistry, Faculty of Dentistry, Universidad de Chile, Santiago, Chile

Rolando Vernal, DDS, MsC, PhD, Department of Conservative Dentistry, Faculty of Dentistry, Universidad de Chile and Instituto de Ciencias Biomédicas, Universidad Autónoma de Chile, Santiago, Chile

Osmir Batista Oliveira Jr, DDS, MsC, PhD, School of Dentistry, Universidad de Estadual Paulista, Araraquara, Brazil

**Methods and Materials:** Fifty volunteers presenting with discoloration of nonvital teeth and endodontic treatment in good condition participated. Fifty teeth were randomly divided into two study groups according to bleaching gel: HP = 35% hydrogen peroxide (n=25) and 37% carbamide peroxide (n=25). Nonvital bleaching was performed with a walking bleaching technique consisting of four sessions of bleach application. Gingival crevicular fluid samples were taken in order to quantify the RANK-L and IL-1 $\beta$  levels by

Gilbert Jorquera, DDS, MS, Department of Prosthodontics, College of Dentistry, Universidad de Los Andes, Santiago, Chile

Javier Basualdo DDS, DSn Post graduate implant program, Faculty of Dentistry, University of Chile – Santiago, Chile

Alessandro Dourado Loguercio, Universidad Estadual de Ponta Grossa, Paraná, Brazil

\*Eduardo Fernández, DDS, DS, PhD, Department of Restorative Dentistry, Dental School, Universidad de Chile, and Instituto de Ciencias Biomédicas, Universidad Auntonoma, Santiago, Chile

\*Corresponding author: Sergio Livingstone Pohlhammer 943, Independencia, Santiago, Chile; e-mail edofdez@yahoo.com

DOI: 10.2341/16-334-C

**enzyme-linked immunosorbent assay. Samples were obtained from six periodontal sites for each bleached tooth: three vestibular and three palatine (mesial, middle, and distal) at seven time periods: baseline, after each of the four sessions of nonvital bleaching, at one week, and at one month after nonvital bleaching. Tooth color variations were analyzed in each session by VITA Bleachedguide 3D-MAS-TER ( $\Delta$ SGU).**

**Results: Significant increments in the RANK-L and IL-1 $\beta$  levels were detected in each evaluated time compared with baseline ( $p < 0.05$ ); however, no differences were detected between hydrogen peroxide and carbamide peroxide on increments of the biomarkers studied. The change of color was effective for both nonvital bleaching therapies ( $p < 0.05$ ).**

**Conclusions: Nonvital bleaching induced a significant increment in the RANK-L and IL-1 $\beta$  levels in periodontal tissues around bleached, nonvital teeth.**

## INTRODUCTION

The intracoronal bleaching technique has traditionally been used to solve esthetic problems of nonvital tooth discoloration since it is a minimally invasive, fast, and effective treatment. In general, gels of sodium perborate, carbamide peroxide, and hydrogen peroxide are used to treat discolored teeth.<sup>1</sup> For all these products, the active agent is hydrogen peroxide, which whitens by means of an oxidation chemical reaction.<sup>2</sup> Bleaching of a discolored tooth positively impacts esthetic self-perception and psychosocial impact,<sup>3,4</sup> as do other vital bleaching systems,<sup>5</sup> and even patient satisfaction and correlation with personality styles.<sup>6,7</sup>

However, one of the adverse effects of intracoronal bleaching that has been reported is external root resorption, which is increasingly rare but still apparent when tooth loss, which occurs quite frequently, is achieved.<sup>1</sup> The incidence mentioned in the literature varies greatly, from 1% to 13%.<sup>8-11</sup> Unfortunately, the etiology of root resorption has yet to be comprehensively explained. It is known that the high oxidative power of hydrogen peroxide can alter the histological and morphological properties of tooth structure.<sup>12-14</sup> Also, hydrogen peroxide has a low molecular weight of H<sub>2</sub>O<sub>2</sub> and is able to diffuse through the tooth structure and stay in periodontal tissues.<sup>15</sup> An extra-root effect produced by free-radical peroxide has produced periodontal cell

cytotoxicity and increased pH in the surface of the root.<sup>16</sup>

Recent studies have shown an increase in the activity of inflammatory cytokines and metalloproteinases when using bleaching techniques.<sup>12,17</sup> These studies suggest that this could also have an effect on the levels of markers of bone destruction, considering that they would have spread to the periodontal tissues. The most important marker of destruction that has been extensively studied is the receptor activator of nuclear factor kappa B-ligand (RANK-L), which is also associated with regulating the process of root resorption.<sup>18,19</sup> Interleukin 1 $\beta$  (IL-1 $\beta$ ) plays a central role in immune and inflammatory responses and the bone remodeling process. It is a cytokine that is present in most of the inflammatory processes, and its increase has been linked to a number of pathological processes, such as periodontitis and marginal bone loss.<sup>20</sup>

There are no reports of associations between increased biomarkers of bone resorption and nonvital whitening using the "walking bleaching" technique. Evidence remains poor, and there are no studies that explain the process by which hydrogen peroxide could act on the processes of tissue destruction surrounding the tooth.

Hydrogen peroxide generates a cytotoxic and tissue-damaging effect. There are reports on the relationship between lower concentrations and less negative effects;<sup>21</sup> therefore, considering that carbamide peroxide degrades to one-third of its concentration being hydrogen peroxide, there may be a lowered effect on periodontal tissue compared with a hydrogen peroxide gel of similar concentration.

Although there is no consensus about the proper amount of hydrogen peroxide to be used with the walking bleaching technique, lower concentrations are typically used since they have a lower potential to alter the histological and morphological properties of the tooth structure.<sup>12-14</sup> However, to our knowledge, no previous published clinical studies have evaluated this issue. Therefore, the aim of this randomized clinical trial was to evaluate the effect of 35% hydrogen peroxide and 37% carbamide peroxide in a nonvital walking bleaching technique (four sessions of treatment) on periodontal markers RANK-L and IL-1 $\beta$ . The first null hypothesis was that the two gels do not have any effect on the induction of IL-1 $\beta$  and RANK-L at different times.

## METHODS AND MATERIALS

Fifty volunteers were selected with one nonvital tooth with discoloration. Prior to the start of the

study, patients signed an informed consent form. They received a prophylaxis brush and a slurry of pumice and water. In addition, oral hygiene instructions were given to standardize the oral conditions of each volunteer and to control for basal periodontal health status.

### Study Design

The trial was a randomized parallel and double-blind (patient and evaluator) clinical trial. Advertising was held to invite participation in the dental school and through social networks such as Facebook and Twitter. This randomized clinical study was approved by the Ethics Committee of the Faculty of Dentistry of the University of Chile (2016/04) and was performed according to the Consolidated Standards of Reporting Trials Statement<sup>22</sup> and the Declaration of Helsinki<sup>23</sup> (1975; revised 2000) (Figure 1).

### Sample Size

To determine the size of the sample, GPower 3.1<sup>24</sup> software was used, considering a significance level of 5% statistical power of 80% and 10% abandoned based on change of color. This study corresponds to a therapeutic equivalence type, where a color variation of  $\Delta$ SGU tones in the range of 7 to 10 or more based on the original color was considered significant. This gives a sample size of 20, and to compensate for a potential dropout rate, we used a sample size of 25 per group. In the absence of previous studies that valued biomarkers using this methodology, it was not possible to make a sample calculation based on the values of biomarkers.

### Inclusion and Exclusion Criteria

Patients included were over 18 years of age with one or more nonvital teeth. Any restoration did not cover the vestibular face of the tooth, and endodontic treatments were required to be in good condition and without apical lesions, with no previous experience of tooth bleaching, and with a tooth shade C2 or greater according to the Vita Classical scale.

Patients were excluded if they were pregnant or lactating, had enamel hypoplasia, had teeth stained by tetracycline or fluorosis, were in orthodontic treatment with fixed appliances, or had periodontal disease. Also, patients with systemic pathologies were excluded, as were those volunteers who presented clinically and radiographically for with

external or internal dental resorption, caries, or periapical lesions. They were informed and referred to specialists for treatment.

### Randomization and Allocation Concealment

The teeth (n=50) were randomly divided into two groups according to the bleaching gel to be applied: 25 patients with 35% hydrogen peroxide (Opalescence Endo, Ultradent, South Jordan, UT, USA) and 25 patients with 37% carbamide peroxide (Whiteness Super-Endo, FGM, Joinville, Brazil). A third person who was not involved in the research protocol performed the randomization procedure by using computer-generated tables. We used simple randomization with an equal allocation ratio ([www.sealedenvelope.com](http://www.sealedenvelope.com)). Opaque, sealed, and consecutively numbered envelopes containing the identification of the groups were opened immediately only before the beginning of the bleaching protocol.

### Study Intervention

The operator was not blinded to the procedure, as both bleaching techniques had different commercial presentations. However, the participants and the examiners who evaluated the color changes were not aware of the allocation of the participants within the study groups. One week before the bleaching therapy commenced, a protective isolating cervical base was applied. For this purpose, the root canal of each tooth was properly isolated with a rubber dam (Rubber Dam Ash, Dentsply, Petropolis, Brazil). Afterward, a final seal with 2 mm of resin-modified glass ionomer cement (Riva Light Cure, SDI, Bayswater, Australia) was placed and light cured for 40 seconds (Cal Radii, SDI). The location 2 mm above the cemento-enamel junction was sealed because of the italic "S" arrangement of the dentinal tubules in this zone; the seal ensured that the cervical crown portions were bleached effectively. The radiographic control was made to corroborate the final seal. In total, three radiographic controls were performed: precontrol, unsealing control, and cervical sealing control.

Bleaching agents were applied according to the manufacturer's instructions in four sessions with an outpatient technique (ie, walking bleaching); each session was separated by one week.<sup>1</sup> In each session, according to the walking bleaching technique, bleach gel was left in the pulp chamber. Subsequently, the cavity was sealed with a temporary cement (Fermin, Detax, Ettlingen, Germany) until the next session. After four weeks of bleaching, the temporary

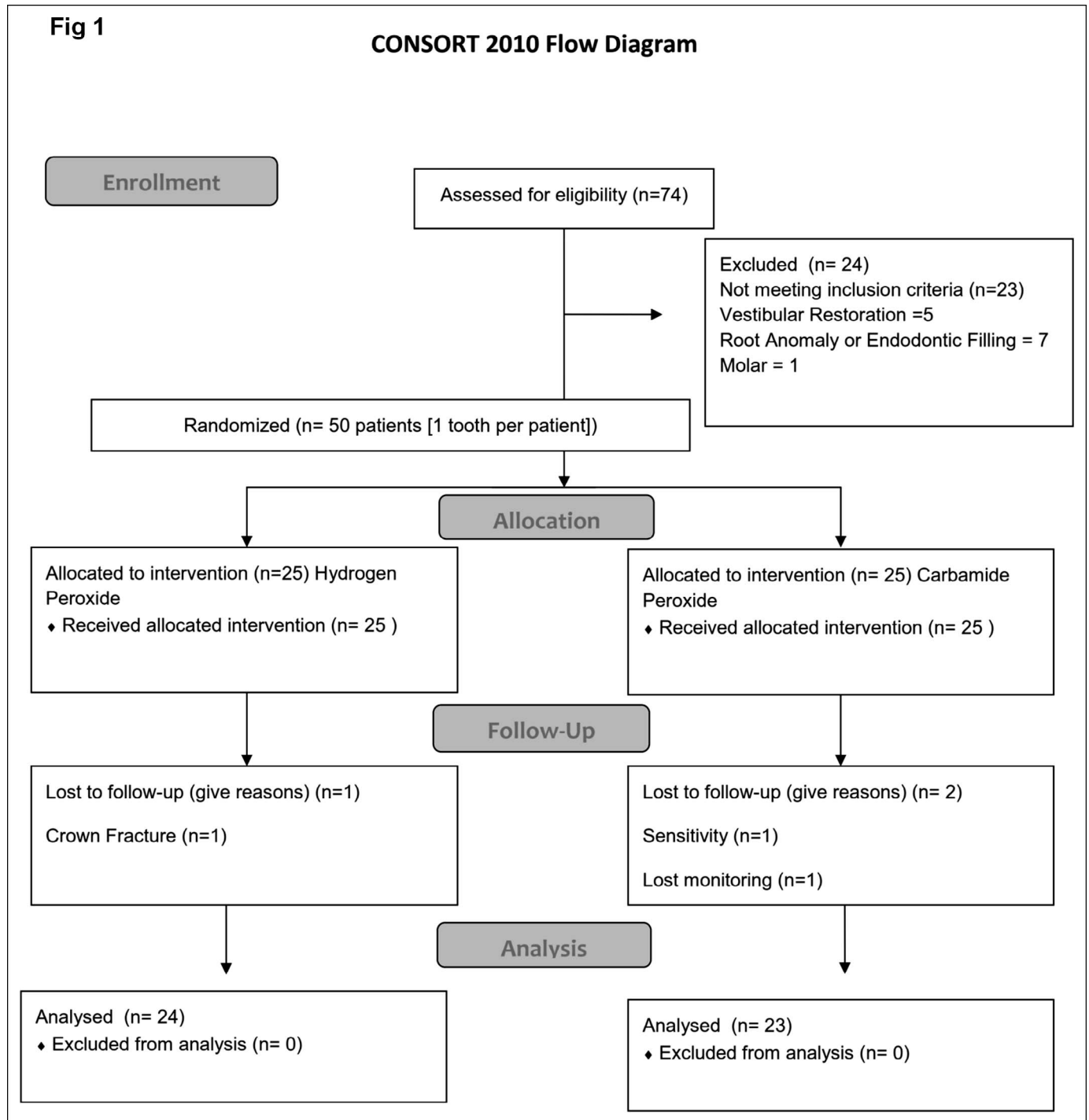


Figure 1. Consort Flow diagram.

material was removed, the pulp chamber was washed with water, and a temporary sealing was left for seven days prior to the completion of the final restoration. Patients were advised not to eat or drink foods that might stain their teeth (e.g., coffee, tea, or red wine) during the study period. They were given

written instructions and contact information if any questions or problems were to arise.

**Color Evaluation**

Two calibrated evaluators with 80% agreement (kappa test) recorded the color of teeth at baseline,

Table 1: *Baseline Features of the Participants*

Baseline Features	Groups	
	Hydrogen Peroxide	Carbamide Peroxide
Age (y; means $\pm$ standard deviation)	30.6 $\pm$ 11.7	30.8 $\pm$ 11.3
Minimum age (y)	19	20
Maximum age (y)	65	65
Male (%)	47.83	39.13
Trauma (%) <sup>a</sup>	56.52	39.13
Caries (%) <sup>a</sup>	43.48	60.87
VITA Bleachedguide 3D-MASTER median (minimum; maximum)	12 (7; 15)	11 (9; 15)

<sup>a</sup> Cause of endodontic treatment.

immediately after each bleaching session, and one week and one month posttreatment. The color evaluation was conducted in the middle third of the labial surface of the tooth bleaching according to the recommendations of the American Dental Association.<sup>25</sup> Patients were examined in the same room with the same lighting, for both examiners independently, using the VITA Bleachedguide 3D-MASTER (Vita Zahnfabrik, Bad Säckingen, Germany). For every “value,” a color is assigned a numerical value in order to calculate the change in unit scale ( $\Delta$ SGU). Color changes were recorded as the difference between the baseline and the different evaluation times, expressed in the number of color guide units ( $\Delta$ SGU). If the results of the two evaluators did not match, the two evaluators then discussed the case until a consensus was reached concerning the color. The color of the counterpart tooth was also recorded subjectively and compared to that of the treated tooth.

### GCF Sample Collection

After isolating the tooth with a cotton roll, supra-gingival plaque was removed with a curette (Gracey 3/4) without touching the marginal gingiva. The crevicular site was then dried gently with an air syringe, and gingival crevicular fluid (GCF) was collected using absorbent paper strips (Periopaper, OraFlow Inc, New York, NY, USA) that were placed into the selected periodontal sulci until mild resistance was felt and left in place for 30 seconds. Strips contaminated by saliva or blood were excluded. GCF samples were obtained from six periodontal locations: three vestibular and three palatal (mesial, middle, and distal) sites from teeth that underwent the bleaching procedures. Samples were taken before the bleaching (baseline) and after each bleaching session as well as one week and one month postbleaching. Following GCF collection,

strips were placed in Eppendorf vials containing 100  $\mu$ L of phosphate-buffered saline with 0.05% Tween-20 (Fluka, Sigma-Aldrich Chemie GmbH, Buchs, Switzerland) and centrifuged at 10,000  $\times$ g for five minutes at 4°C. The elution procedure was repeated twice, and obtained samples were stored at  $-80^{\circ}\text{C}$  until further analysis.

### Quantification of RANK-L and IL-1 $\beta$

Total proteins were quantified using Bradford procedures, and then the RANK-L and IL-1 $\beta$  levels were measured using Quantikine ELISA (R&D Systems Inc, Minneapolis, MN, USA) following the manufacturer’s instructions. The ELISA kits used in this study were the RANKL ELISA (catalog number 04-BI-20462, Alpco, Biomedica Medizinprodukte GmbH & Co, Vienna, Austria) and the IL-1 $\beta$  ELISA (Human CXCL8/IL-8, D8000C, R&D Systems Inc). Absorbance was measured at 492 nm with a wavelength correction of 630 nm using an automatic microplate reader (Synergy HT, Bio-Tek Instrument Inc, Winooski, VT, USA). The concentration of each marker in each sample was calculated by a four-parameter logistic equation.

### Statistical Analysis

Statistical analysis was performed using SPSS 23.0 (SPSS Inc, Chicago, IL, USA) with  $\alpha = 0.05$ . For intragroup analysis, the Wilcoxon test was used; for intergroup analysis, we used the Mann-Whitney test.

## RESULTS

A total of 74 volunteers were examined, and 50 patients met the inclusion criteria. Fifty teeth were selected, one from each patient, of which three did not complete the treatment, and one tooth was excluded from analysis due to problems with the analysis of samples of the gingival fluid. The final

Table 2: Changes of Color by  $\Delta$ SGU (VITA Bleachedguide 3D-MASTER) by Group in Different Time Frames Expressed by Median, Minimum, Maximum, and Statistical Significance (Minimum; Maximum)<sup>a</sup>

Assessment Points	Color Change		Mann-Whitney Between Groups
	Hydrogen Peroxide	Carbamide Peroxide	
Baseline vs 1 wk of bleaching	3 (0; 5) A	1 (0; 4) A	0.410
Baseline vs 2 wk of bleaching	4 (0; 8) A	2 (0; 5) A	0.002
Baseline vs 3 wk of bleaching	5 (0; 9)	4 (1; 5) A	0.007
Baseline vs 4 wk of bleaching	5.5 (0; 9)	4 (2; 8)	0.019
Baseline vs 1 wk after bleaching (before restoration)	5 (0; 9)	4 (2; 7)	0.037
Baseline vs 1 wk after bleaching (after restoration)	5 (0; 9)	4 (2; 7)	0.040
Baseline vs 1 mo after bleaching	5 (0; 9)	4 (2; 7)	0.027

<sup>a</sup> Mann-Whitney test was applied only for pairwise comparison between groups at each time ( $\alpha=0.05$ ). Wilcoxon rank statistical test was applied only for comparison of different times for each group ( $\alpha=0.05$ ). Values with the same letter indicate statistically significant difference with all times in the group ( $p<0.05$ ).

sample consisted of a total of 46 nonvital teeth that were bleached; the distribution of the group can be seen in Table 1.

### Color Evaluation

The color change results are shown in Table 2. Hydrogen peroxide showed a high degree of whitening after the third session of bleaching to the one-month follow-up ( $p<0.05$ ) compared with the carbamide-peroxide group, which achieved a significant difference of color change after the fourth session ( $p<0.05$ ). There was a statistically significant difference ( $p<0.05$ ) in the third and fourth weeks, showing more color change in the hydrogen peroxide group. At one week postbleaching, the color change did not present significant differences. Significant whitening was observed in both study groups after four weeks of treatment ( $p<0.05$ ). The hydrogen peroxide group showed a higher degree of whitening in the second, third, and fourth weeks of bleaching when compared to the carbamide peroxide group ( $p<0.02$ ). There was a difference between the degree of whitening between groups at one month postbleaching ( $p<0.03$ ).

### Quantification of RANK-L

In total, 966 samples were taken from each group for quantification of RANK-L and IL-1 $\beta$ . Figure 2 shows the levels of RANK-L expressed in pg/ $\mu$ L, considering all the sites. All evaluation times were increased with statistically significant differences between them ( $p<0.05$ ). Table 3 shows the RANK-L levels expressed in differences between the baseline and time values (delta). The comparison of delta values between groups showed no statistically significant differences at the times assessed ( $p>0.075$ ).

### Quantification of IL-1 $\beta$

Figure 3 shows the levels of IL-1 $\beta$  expressed in pg/ $\mu$ L, considering all the sites. All evaluation times have statistically significant differences between them ( $p<0.05$ ). Concerning the total values of IL-1 $\beta$ , there was a statistically significant difference at three weeks of bleaching ( $p<0.05$ ) between the groups; however, there was no significant difference for the total values by vestibular or palatal sites at the same time between the groups ( $p>0.1$ ). Table 3 shows the IL-1 $\beta$  levels expressed in differences between the baseline and time values (delta). The comparison of delta values between groups showed no statistical difference at the times assessed ( $p>0.06$ ) except at the three-week session ( $p=0.049$ ).

### DISCUSSION

The results of the present investigation showed that both products showed a significant color change after four weeks of treatment, although hydrogen peroxide exhibited a faster effect. This may be due to the slower chemical decomposition of carbamide peroxide and its lower penetration into dental tissues compared to hydrogen peroxide;<sup>16,26,27</sup> ie, carbamide peroxide has a chemical decomposition rate that is one-third that hydrogen peroxide. Both products showed increased levels of similar markers (Tables 3 and 4). One explanation for this is that the concentration of hydrogen peroxide released from gel carbamide peroxide (16%) may be sufficient to aggravate periodontal tissues.

The most important topic to be presented in this study is whether hydrogen peroxide or carbamide peroxide could be responsible for increasing the levels of RANK-L and IL-1 $\beta$ . The results of the present trial suggest that hydrogen peroxide and carbamide perox-

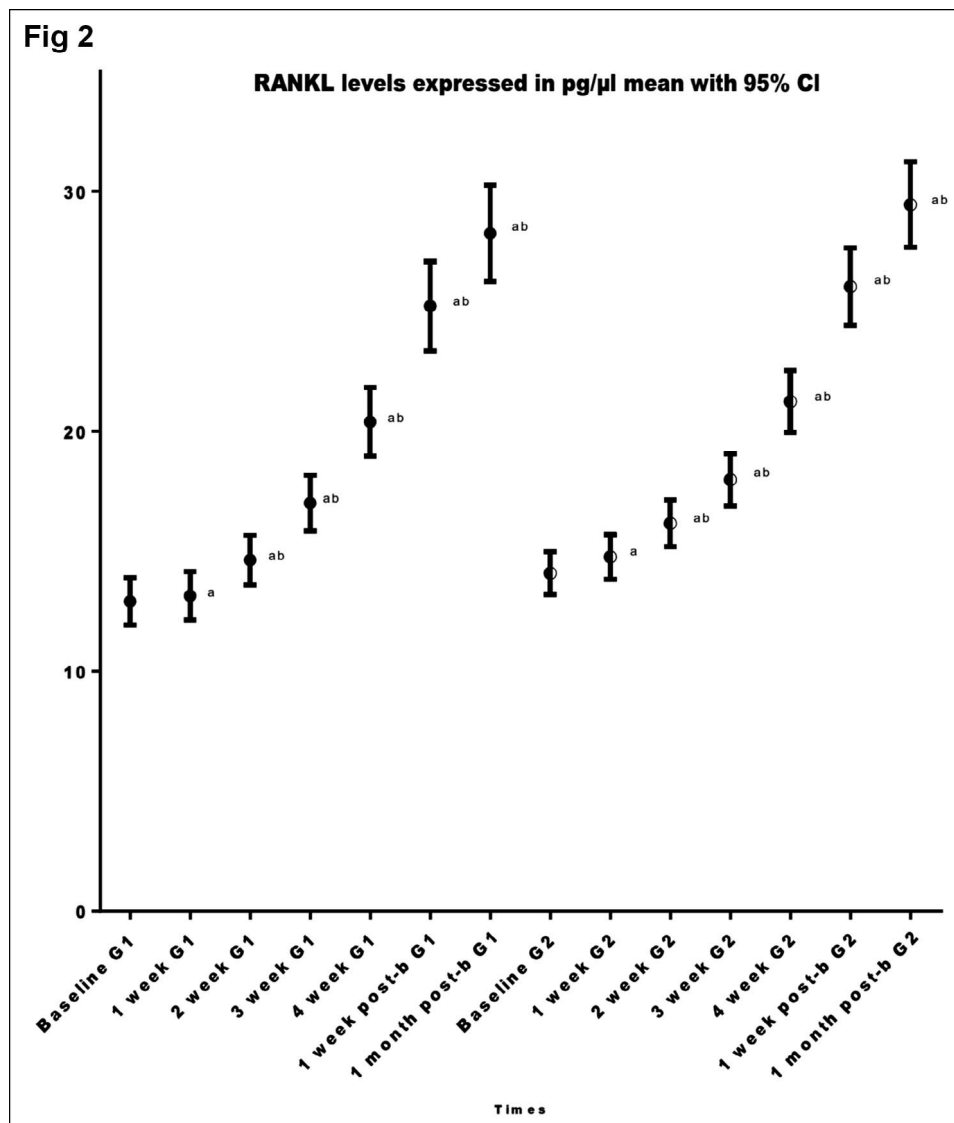


Figure 2. RANK-L levels at times expressed in pg/ $\mu$ L, mean with 95%. a, statistically significant difference with baseline with the Wilcoxon test ( $p < 0.05$ ); b, statistically significant difference with previous time with the Wilcoxon test ( $p < 0.05$ ).

ide influence the RANK-L-RANK-OPG axis by significantly increasing RANK-L and IL-1 $\beta$  from the first session of nonvital bleaching until one month post-bleaching. This study showed a constant increase of biomarkers even one month postbleaching (Tables 3 and 4); therefore, the question remains, When does the increase of biomarkers stop? The answer is that hydrogen peroxide triggers a chronic process into the periodontium and can exhibit a duration over one month postbleach-gel contact.

This indicates that the significant increase of levels of markers of bone destruction (ie, RANK-L and IL-1 $\beta$ ) could be responsible for the phenomenon of external root resorption, a pathology associated with the walking bleaching technique when applied in endodontically treated teeth.<sup>28-30</sup>

IL-1 $\beta$  is a potent osteoclast activity initiator<sup>31</sup> and generally stimulates macrophages, monocytes, or endothelial cells, among others, to produce metalloproteinases, prostaglandins, and other proinflammatory cytokines.<sup>32,33</sup> Also, it stimulates RANK-L production of osteoblasts, causing differentiation and maintenance of osteoclasts.<sup>34</sup> Among the factors that trigger increased IL-1 $\beta$  are nonmicrobial factors, such as tissue injury or the presence of inflammatory molecules, among others;<sup>32</sup> this situation is initiated by the peroxide released from the pulp chamber to the periodontium.

The role of IL-1 $\beta$ , a key cytokine with proinflammatory functions, has not yet been studied in the case of bleaching treatment. Studies have linked increased levels of IL-1 $\beta$  in teeth with apical external resorption associated with orthodontic treatment

Table 3: Delta IL-1 $\beta$  and RANKL Levels Expressed in pg/ $\mu$ L, Median (Minimum; Maximum)<sup>a</sup>

Assessment Points	Delta IL-1 $\beta$		Delta RANK-L	
	$\Delta$ HP	$\Delta$ CP	$\Delta$ PH	$\Delta$ PC
1 wk of bleaching vs baseline	2.77 (-1.69; 17.32)	2.64 (-1.91; 30.03)	0.52 (-2.61; 2.80)	0.54 (-0.88; 4.77)
2 wk of bleaching vs baseline	9.78 A (0.77; 35.36)	8.64 A (0.30; 57.92)	1.92 A (-0.88; 6.57)	1.71 A (-0.70; 9.24)
3 wk of bleaching vs baseline	21.53 A (2.75; 73.01)	18.27 A (0.49; 107.03)	4.17 A (-0.47; 13.81)	3.40 A (0.18; 13.19)
4 wk of bleaching vs baseline	40.38 A (7.86; 147.22)	34.23 A (3.12; 177.58)	8.02 A (0.30; 22.76)	6.62 A (1.72; 18.19)
1 wk after bleaching vs baseline	66.98 A (13.10; 201.01)	62.62 A (9.91; 222.92)	12.17 A (1.91; 37.67)	11.19 A (2.61; 29.83)
1 mo after bleaching vs baseline	81.74 A (21.79; 237.21)	79.37 A (16.47; 254.03)	15.20 A (0.80; 46.45)	14.57 A (4.18; 36.41)

Abbreviations:  $\Delta$ , assessment points vs baseline; HP, hydrogen peroxide; CP, carbamide peroxide.  
<sup>a</sup> Wilcoxon rank statistical test was applied only for comparison of different times for each group ( $\alpha=0.05$ ). Values with the same letter indicate statistically significant difference with previous time with the Wilcoxon test ( $p<0.05$ ).

sequelae.<sup>35</sup> This demonstrates the presence of an inflammatory process,<sup>36</sup> which can explain the unbalanced levels of RANK-L.<sup>37</sup> Royaka and others, in a recent study, explain that extraradicular diffusion during intracoronary bleaching with different bleaching agents.<sup>27</sup>

Also, the imbalance shift of IL-1 $\beta$  and RANK-L levels is a finding that could be explained initially by the sudden drop in pH and, in turn, autocatalyzation to achieve a stabilization of metalloproteinase and cathepsin. This is because, according to a recent report, proteolytic enzymes, cysteine cathepsins, and matrix metalloproteinases are activated in mineralized dentin during degradation from tooth-bleaching treatment with 35% H<sub>2</sub>O<sub>2</sub>.<sup>12</sup>

Although no clinical or radiographic signs of external root resorption were observed in the present study—mainly because this is a chronic process—the findings of the present study may explain to some extent the beginning of this process, mainly because there is an increase in markers responsible for the activation of osteoclasts. This may be a predisposing factor for the marginal bone resorption and an explanation for the phenomenon of external cervical resorption—mediated odontoclasts, which is still not explained in the literature.

It is worth mentioning that the increased levels of RANK-L are not comparable to those achieved by a patient with active periodontal disease since these levels could suggest an activation process of bone resorption in patients with high periodontal risk.<sup>38</sup> However, increasing the levels of IL-1 $\beta$  (about 190 pg/ $\mu$ L) is comparable with active sites of periodontitis,<sup>39</sup> indicating that this damage is relevant, mainly because

after completion of bleaching and up to one month of monitoring, there is a continuous and progressive increase in the levels of IL-1 $\beta$  and RANK-L.

It is important to mention that a high variability of marker levels was found during all phases of the study; also, some significant differences were found for IL-1 $\beta$  when palatal and vestibular sites were compared in the same tooth. This could be explained by several factors. The anatomy of endodontically treated teeth and the thickness of the remaining walls are not uniform, so it is expected that in teeth with less dentin thickness, diffusion of peroxide into the periodontal regions can have a greater effect.<sup>40</sup> In addition, the biological response of each individual is different.<sup>39</sup> Perhaps some cracks and fractures associated with traumatic injuries could be responsible for the faster spread of peroxide. Also, the inflammatory response with high intersubject variability may better explain root resorption mediated by increased levels of IL-1 $\beta$  and RANK-L markers.

The technique evaluated in the present study applied the bleaching products inside the pulp chamber to facilitate contact with dentinal tissue and to maintain that contact for a long period of time (one week)<sup>1,41,42</sup> during which the chemical agent makes prolonged contact with the tooth; this favors the spread of peroxide into the extraradicular space, which would cause an increase in the markers studied. This study coincides with that of Firat,<sup>43</sup> where an in-office bleaching gel was applied in vital teeth without direct contact with the dentinal tissue and showed that an increase in levels of IL-1 $\beta$  was produced by direct contact of three gels with higher concentrations of hydrogen peroxide (>35%) despite the fact that this amount of



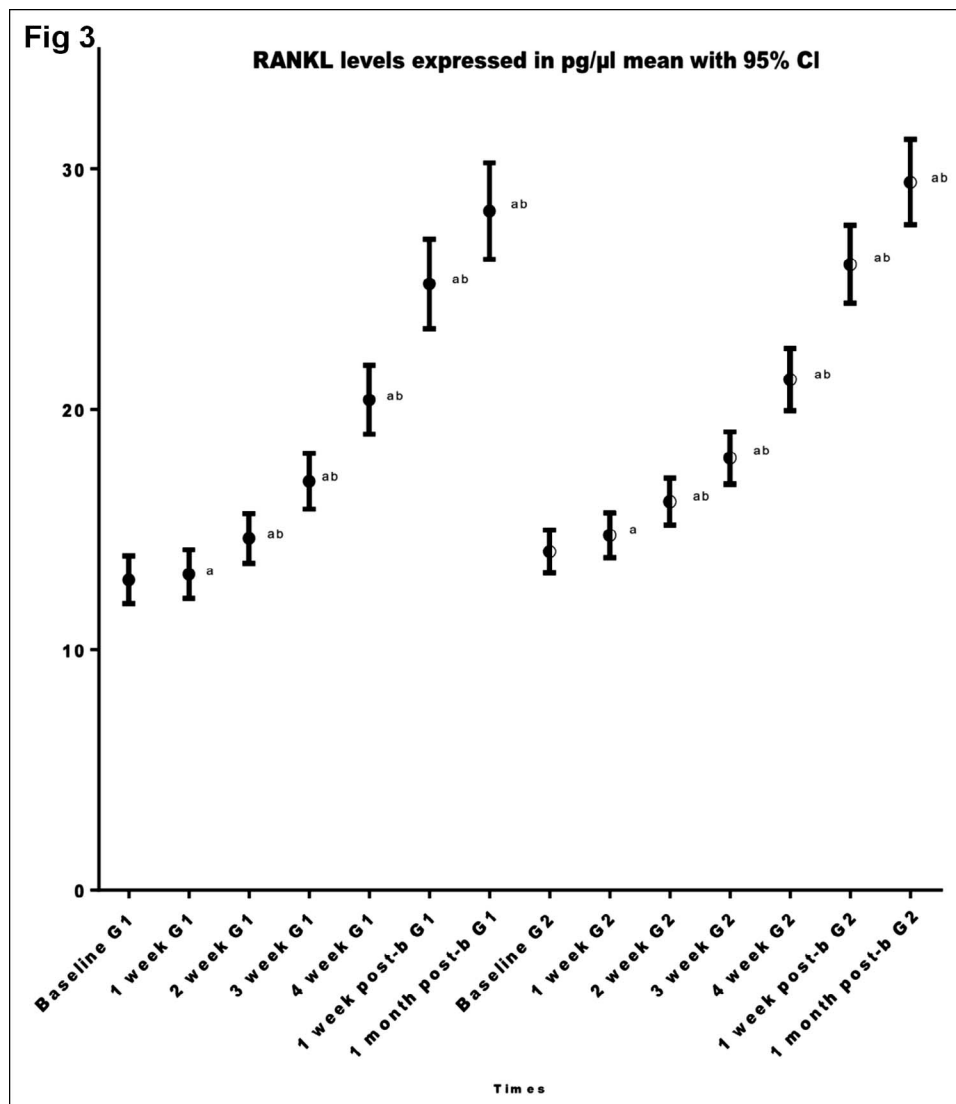


Figure 3. IL-1 $\beta$  levels at times expressed in pg/ $\mu$ L, mean with 95%. a, statistically significant difference with baseline with the Wilcoxon test ( $p < 0.05$ ); b, statistically significant difference with previous time with the Wilcoxon test ( $p < 0.05$ ).

IL-1 $\beta$  is very low ( $< 73$  pg/ $\mu$ L per site) compared with the results of this study (Table 3). This reinforces the importance of remaining hydrogen peroxide in the pulp chamber.

Future studies should use in-office bleaching only on the enamel surface of nonvital teeth to evaluate bone markers, such as RANK-L and IL-1 $\beta$ .

### CONCLUSIONS

The walking bleaching technique with 35% hydrogen peroxide and 37% carbamide peroxide results in constantly increasing levels of RANK-L and IL-1 $\beta$  in the gingival crevicular fluid around the bleached teeth through one month postbleaching; this is associated with a chronic process within the periodontium apparently of unknown behavior—that is, the biomarkers increased until the one-month

follow-up, and we do not know when they will return to normal. The change of color in the hydrogen peroxide group was faster than the carbamide peroxide group when using a walking bleaching technique and when measured subjectively, but both groups showed high effectiveness.

### Acknowledgement

The work was supported by Fondecyt 1140904. The author dedicates this article to her two kids Elisa and Eduardo by their enormous inspiration.

### Regulatory Statement

This study was conducted in accordance with all the provisions of the local human subjects oversight committee guidelines and policies of the Comité Etico-Científico de la Facultad de Odontología de la Universidad de Chile (FOUCH). The approval code for this study is 2016/04.

**Conflict of Interest**

The authors of this article certify that they have no proprietary, financial, or other personal interest of any nature or kind in any product, service, and/or company that is presented in this article.

(Accepted 28 April 2017)

**REFERENCES**

- Plotino G, Buono L, Grande NM, Pameijer CH, & Somma F (2008) Nonvital tooth bleaching: A review of the literature and clinical procedures *Journal of Endodontics* **34(4)** 394-407, 10.1016/j.joen.2007.12.020.
- Joiner A (2006) The bleaching of teeth: A review of the literature *Journal of Dentistry* **34(7)** 412-419, 10.1016/j.jdent.2006.02.002.
- Fernandez E, Bersezio C, Bottner J, Avalos F, Godoy I, Inda D, Vildosola P, Saad J, Oliveira OB Jr, & Martin J (2017) Longevity, esthetic perception, and psychosocial impact of teeth bleaching by low (6%) hydrogen peroxide concentration for in-office treatment: A randomized clinical trial *Operative Dentistry* **42(1)** 41-52, 10.2341/15-335-c.
- Bersezio C, Martín J, Estay J, Peña F, Rubio M, Vernal R, Oliveira O Jr, & Fernández E (2017) Effectiveness and impact of the walking bleach technique on esthetic self-perception and psychosocial factors: A randomized double-blind clinical trial *Operative Dentistry*. In press.
- Martin J, Vildosola P, Bersezio C, Herrera A, Bortolato J, Saad JRC, Oliveira OB, & Fernandez E (2015) Effectiveness of 6% hydrogen peroxide concentration for tooth bleaching—A double-blind, randomized clinical trial *Journal of Dentistry* **43(8)** 965-972, 10.1016/j.jdent.2015.05.011.
- Herrera A, Martin J, Perez F, Bonafe E, Reis A, Dourado AL, & Fernandez E (2016) Is personality relevant in the choice of bleaching? *Clinical Oral Investigations* **20(8)** 2105-2111, 10.1007/s00784-015-1701-3.
- Martin J, Rivas V, Vildosola P, Moncada L, Oliveira Junior OB, Saad JR, Fernandez E, & Moncada G (2016) Personality style in patients looking for tooth bleaching and its correlation with treatment satisfaction *Brazilian Dental Journal* **27(1)** 60-65, 10.1590/0103-6440201600127.
- Harrington GW, & Natkin E (1979) External resorption associated with bleaching of pulpless teeth *Journal of Endodontics* **5(11)** 344-348, 10.1016/s0099-2399(79)80091-6.
- Lado EA, Stanley HR, & Weisman MI (1983) Cervical resorption in bleached teeth *Oral Surgery Oral Medicine Oral Pathology* **55(1)** 78-80.
- Cvek M, & Lindvall AM (1985) External root resorption following bleaching of pulpless teeth with oxygen peroxide *Endodontics and Dental Traumatology* **1(2)** 56-60.
- Latcham NL (1986) Postbleaching cervical resorption *Journal of Endodontics* **12(6)** 262-264, 10.1016/s0099-2399(86)80258-8.
- Sato C, Rodrigues F, Garcia D, Vidal C, Pashley D, Tjäderhane L, Carrilho M, Nascimento F, & Tersariol I (2013) Tooth bleaching increases dentinal protease activity *Journal of Dental Research* **92(2)** 187-192.
- Jiang T, Ma X, Wang Y, Zhu Z, Tong H, & Hu J (2007) Effects of hydrogen peroxide on human dentin structure *Journal of Dental Research* **86(11)** 1040-1045.
- Joiner A (2007) Review of the effects of peroxide on enamel and dentine properties *Journal of Dentistry* **35(12)** 889-896, 10.1016/j.jdent.2007.09.008.
- Palo RM, Bonetti-Filho I, Valera MC, Camargo CH, Camargo S, Moura-Netto C, & Pameijer C (2012) Quantification of peroxide ion passage in dentin, enamel, and cementum after internal bleaching with hydrogen peroxide *Operative Dentistry* **37(6)** 660-664, 10.2341/11-334-l.
- Lee GP, Lee MY, Lum SO, Poh RS, & Lim KC (2004) Extraradicular diffusion of hydrogen peroxide and pH changes associated with intracoronary bleaching of discoloured teeth using different bleaching agents *International Endodontic Journal* **37(7)** 500-506, 10.1111/j.1365-2591.2004.00838.x.
- Toledano M, Yamauti M, Osorio E, & Osorio R (2011) Bleaching agents increase metalloproteinases-mediated collagen degradation in dentin *Journal of Endodontics* **37(12)** 1668-1672, 10.1016/j.joen.2011.08.003.
- Kikuta J, Yamaguchi M, Shimizu M, Yoshino T, & Kasai K (2015) Notch signaling induces root resorption via RANKL and IL-6 from hPDL cells *Journal of Dental Research* **94(1)** 140-147, 10.1177/0022034514555364.
- Nakano Y, Yamaguchi M, Fujita S, Asano M, Saito K, & Kasai K (2011) Expressions of RANKL/RANK and M-CSF/c-fms in root resorption lacunae in rat molar by heavy orthodontic force *European Journal of Orthodontics* **33(4)** 335-343, 10.1093/ejo/cjq068.
- Kornman KS (2006) Interleukin 1 genetics, inflammatory mechanisms, and nutrigenetic opportunities to modulate diseases of aging *American Journal of Clinical Nutrition* **83(2)** 475s-483s.
- Soares DG, Basso FG, Hebling J, & de Souza Costa CA (2014) Concentrations of and application protocols for hydrogen peroxide bleaching gels: Effects on pulp cell viability and whitening efficacy *Journal of Dentistry* **42(2)** 185-198, 10.1016/j.jdent.2013.10.021.
- Lorette G, & Maruani A (2013) [The CONSORT statement (CONsolidated Standards Of Reporting Trials)] *Annales de Dermatologie et de Vénérologie* **140(6-7)** 431-435, 10.1016/j.annder.2013.04.091.
- World Medical Association Declaration of Helsinki (2002) Ethical principles for medical research involving human subjects *Nursing Ethics* **9(1)** 105-109.
- Faul F, Erdfelder E, Lang AG, & Buchner A (2007) G\*Power 3: A flexible statistical power analysis program for the social, behavioral, and biomedical sciences *Behavior Research Methods* **39(2)** 175-191.
- American Dental Association (2012) Tooth whitening products: ADA statement on safety and effectiveness; Retrieved online July 7, 2017 from: <http://www.ada.org/en/about-the-ada/ada-positions-policies-and-statements/tooth-whitening-safety-and-effectiveness>

26. Gokay O, Ziraman F, Cali Asal A, & Saka OM (2008) Radicular peroxide penetration from carbamide peroxide gels during intracoronal bleaching *International Endodontic Journal* **41(7)** 556-560, 10.1111/j.1365-2591.2008.01384.x.
27. Rokaya ME, Beshr K, Hashem Mahram A, Samir Pedir S, & Baroudi K (2015) Evaluation of extraradicular diffusion of hydrogen peroxide during intracoronal bleaching using different bleaching agents *International Journal of Dentistry* **2015** 493795, 10.1155/2015/493795.
28. Patel S, Kanagasingam S, & Pitt Ford T (2009) External cervical resorption: A review *Journal of Endodontics* **35(5)** 616-625, 10.1016/j.joen.2009.01.015.
29. Heithersay GS (1999) Invasive cervical resorption: An analysis of potential predisposing factors *Quintessence International* **30(2)** 83-95.
30. Goldberg M, Grootveld M, & Lynch E (2010) Undesirable and adverse effects of tooth-whitening products: A review *Clinical Oral Investigations* **14(1)** 1-10, 10.1007/s00784-009-0302-4.
31. Tunyogi-Csapo M, Kis-Toth K, Radacs M, Farkas B, Jacobs JJ, Finnegan A, Mikecz K, & Glant TT (2008) Cytokine-controlled RANKL and osteoprotegerin expression by human and mouse synovial fibroblasts: Fibroblast-mediated pathologic bone resorption *Arthritis and Rheumatology* **58(8)** 2397-2408, 10.1002/art.23653.
32. Dinarello CA (1996) Biologic basis for interleukin-1 in disease *Blood* **87(6)** 2095-2147.
33. Garlanda C, Dinarello CA, & Mantovani A (2013) The interleukin-1 family: Back to the future *Immunity* **39(6)** 1003-1018, 10.1016/j.immuni.2013.11.010.
34. Lorenzo J, Horowitz M, & Choi Y (2008) Osteoimmunology: Interactions of the bone and immune system *Endocrine Reviews* **29(4)** 403-440, 10.1210/er.2007-0038.
35. Iglesias-Linares A, Yanez-Vico RM, Ortiz-Ariza E, Ballesta S, Mendoza-Mendoza A, Perea E, & Solano-Reina E (2012) Postorthodontic external root resorption in root-filled teeth is influenced by interleukin-1beta polymorphism *Journal of Endodontics* **38(3)** 283-287, 10.1016/j.joen.2011.12.022.
36. Dinarello CA (2011) Interleukin-1 in the pathogenesis and treatment of inflammatory diseases *Blood* **117(14)** 3720-3732, 10.1182/blood-2010-07-273417.
37. Stein SH, Dean IN, Rawal SY, & Tipton DA (2011) Statins regulate interleukin-1 $\beta$ -induced RANKL and osteoprotegerin production by human gingival fibroblasts *Journal of Periodontal Research* **46(4)** 483-490, 10.1111/j.1600-0765.2011.01364.x.
38. Belibasakis GN, & Bostanci N (2012) The RANKL-OPG system in clinical periodontology *Journal of Clinical Periodontology* **39(3)** 239-248, 10.1111/j.1600-051X.2011.01810.x.
39. Gamonal J, Acevedo A, Bascones A, Jorge O, & Silva A (2000) Levels of interleukin-1 beta, -8, and -10 and RANTES in gingival crevicular fluid and cell populations in adult periodontitis patients and the effect of periodontal treatment *Journal of Periodontology* **71(10)** 1535-1545, 10.1902/jop.2000.71.10.1535.
40. Boutsoukis C, Psimma Z, & van der Sluis LW (2013) Factors affecting irrigant extrusion during root canal irrigation: A systematic review *International Endodontic Journal* **46(7)** 599-618, 10.1111/iej.12038.
41. Bizhang M, Heiden A, Blunck U, Zimmer S, Seemann R, & Roulet JF (2003) Intracoronal bleaching of discolored non-vital teeth *Operative Dentistry* **28(4)** 334-340.
42. Attin T, Paque F, Ajam F, & Lennon AM (2003) Review of the current status of tooth whitening with the walking bleach technique *International Endodontic Journal* **36(5)** 313-329.
43. Firat E, Ercan E, Gurgan S, Yucel OO, Cakir FY, & Berker E (2011) The effect of bleaching systems on the gingiva and the levels of IL-1beta and IL-10 in gingival crevicular fluid *Operative Dentistry* **36(6)** 572-580, 10.2341/10-058-c.