


Journal Pre-proof

Preschool girl with vaginal bleeding due to pinworm endometritis

Andrea von Höveling, MD, Lilian Carrasco, MD, Thomas Weitzel, MD, Gioconda Martinez, MD, Cristina Riquelme, MD, Paula Sepulveda, Hugo Ojeda



PII: S1083-3188(19)30373-0

DOI: <https://doi.org/10.1016/j.jpag.2019.12.004>

Reference: PEDADO 2430

To appear in: *Journal of Pediatric and Adolescent Gynecology*

Received Date: 23 October 2019

Revised Date: 10 December 2019

Accepted Date: 13 December 2019

Please cite this article as: von Höveling A, Carrasco L, Weitzel T, Martinez G, Riquelme C, Sepulveda P, Ojeda H, Preschool girl with vaginal bleeding due to pinworm endometritis, *Journal of Pediatric and Adolescent Gynecology* (2020), doi: <https://doi.org/10.1016/j.jpag.2019.12.004>.

This is a PDF file of an article that has undergone enhancements after acceptance, such as the addition of a cover page and metadata, and formatting for readability, but it is not yet the definitive version of record. This version will undergo additional copyediting, typesetting and review before it is published in its final form, but we are providing this version to give early visibility of the article. Please note that, during the production process, errors may be discovered which could affect the content, and all legal disclaimers that apply to the journal pertain.

© 2019 Published by Elsevier Inc. on behalf of North American Society for Pediatric and Adolescent Gynecology.

Preschool girl with vaginal bleeding due to pinworm endometritis

Andrea von Höveling, MD¹ ; Lilian Carrasco, MD²; Thomas Weitzel, MD³; Gioconda Martinez, MD⁴; Cristina Riquelme, MD⁴; Paula Sepulveda⁵; Hugo Ojeda⁵.

1. Department of Obstetrics and Gynecology Hospital El Carmen, Department of Obstetrics and Gynecology Clínica Santa María, Finis Terrae University; Santiago, Chile
2. Department of Obstetrics and Gynecology Hospital Exequiel González Cortés, Department of Obstetrics and Gynecology Clínica Indisa, Santiago, Chile.
3. Clinical Laboratory, Clinica Alemana, Universidad del Desarrollo, Santiago, Chile
4. Department of Pediatrics Hospital El Carmen, Santiago, Chile
5. Finis Terrae University, Santiago, Chile

Abstract:

Genital tract bleeding in prepubertal girls is a rare clinical condition, which can occur for multiple reasons. It frequently generates anxiety in the family and in health care professionals. A thorough anamnesis and careful genital inspection can give important diagnostic hints; however, there are cases in which the cause remains doubtful and a complete gynecological evaluation (including cultures and vaginoscopy) is necessary. Therefore, the attending physician should always consider less frequent diagnoses in order to perform the necessary studies in a sequential and rational manner.

We present the case of a preschool girl with vaginal bleeding due to pinworm endometritis, which, to our knowledge, has never been reported before as a cause of genital bleeding in prepubertal girls.

Introduction

Genital bleeding in a girl without signs of pubertal development is cause for alarm and poses a diagnostic and prognostic dilemma given its great etiological diversity including infections, tumors, foreign bodies in the vagina, genital trauma and also non gynecological diseases. In addition, because of the low prevalence of this entity, there are limitations for the gynecological examination of prepubertal girls for many doctors, due to the lack of experience and the limited availability of appropriate instruments.

The basic knowledge of all the potential causes is essential, in order to carry out an exhaustive evaluation and / or to be able to call the appropriate specialist if necessary.

Clinical case:

A 3 years and 4 months-old, otherwise healthy female patient attended the Emergency Pediatric Unit due to genital bleeding without other associated symptoms. Physical examination showed breasts and pubic hair at a Tanner I stage. Genital inspection revealed female genitalia without signs of estrogenization and no injuries, annular hymen without notches, and multiple blood clots without bad odor, emerging from the vaginal orifice. The perineal and anal regions were unremarkable. A vaginoscopy was performed under general anesthesia, which showed multiple blood clots and a large number of white, thin worms about 1 cm long, compatible with pinworms (Fig. 1-2). Vaginal mucosa showed no lesions, cervix was found to have inflammatory mucosa and active bleeding coming from external cervical os. Cultures of vaginal secretion and gonococcus were negative; perianal scotch test was positive for *Enterobius vermicularis* eggs. Bladder was filled in order to make a transabdominal gynecological ultrasound, showing ovaries and uterus of prepubertal characteristics (right ovary: 0.04 cc, left ovary 0.11 cc. Uterus: longitudinal diameter 20 mm). Endometrium was hyperechoic and 1.8 mm thick, with images suggesting occupation of the endometrial cavity with moving elements (Fig. 3). Considering the absence of any pubertal development, the negative cultures, the visualization of pinworms in the upper vagina and the positive perianal cellophane test, the bleeding and ultrasound findings were attributed to endometritis due to *Enterobius* infestation.

A single dose of Albendazole 400 mg was given to the patient and her contacts. The bleeding persisted, with hematocrit and hemoglobin declines from 31.5% to 28.2% and 10.7 g/dL to 9.3 g/dL, respectively, over 4 days. Leukocyte counts and platelets as well as coagulation tests remained within normal range. A second dose of albendazole 400 mg was administered and systemic therapy with metronidazole and amikacin was initiated, considering the possibility of secondary bacterial endometritis. The vaginal bleeding stopped after 3 days and the patient was discharged on oral antibiotic treatment with metronidazole and cefadroxil to complete 14 days.

In the following months, she maintained growth according to chronological age, without pubertal signs and without genital bleeding. A subsequent transabdominal gynecological ultrasound showed ovaries and uterus of prepubertal characteristics (right ovary: 0.07 cc, left ovary 0.10 cc. Uterus: longitudinal diameter 32 mm), with no visible endometrium at the uterine fundus. Normal hematocrit and hemoglobin were achieved after 6 weeks of oral iron therapy.

The child's mother authorized the publication of her daughter's case.

Discussion

Prepubertal vaginal bleeding

The large number of diagnostic possibilities makes it essential to make a thorough evaluation of the patient. It is also important to have a rational approach to the child, both to rule out first the most frequent causes and to avoid unnecessary invasive procedures¹.

The general physical examination must evaluate the clinical impact of bleeding, pubertal stage and search for any sign of systemic disease. It is also necessary to rule out extra-gynecological causes such as anal or rectal fissures, urethral prolapse and hemangiomas or other vascular malformations^{1 2}.

If the vaginal origin of the bleeding is confirmed, all possible causes should be kept in mind in order to guide the diagnostic approach. Most etiologies are benign; the most frequent is nonspecific vulvovaginitis (inflammation of vulvar and vaginal mucosa due to environmental factors) followed by vulvovaginitis by specific pathogens. Local lesions such as trauma, irritation due to foreign body or tumors can also be found. If sexual abuse is suspected (either by anamnestic information, an identified sexually transmitted infection or the type of lesion) the girl must be referred for a specialized evaluation, consisting of interviews by trained personnel and additional tests for sexual transmission diseases (STDs). According to local laws, the authorities have to be informed². Uterine causes have less frequently been reported, such as prepubertal menarche (transient endometrial development and desquamation, prior to thelarche), the first manifestation of McCune Albright syndrome (functional ovarian cyst with endometrial development prior to breast development), and endometritis³.

Genital inspection including visualization of the distal vagina frequently allows the identification of the cause of bleeding. Vaginoscopy should be performed in all patients in whom the cause of bleeding is not identified by the initial examination. It enables the observation of lesions at a high vaginal level (or in the uterine cervix), the identification and removal of foreign bodies, and allows the certainty of a uterine bleeding as the symptoms source if bleeding through the cervix is seen. It is fundamental to choose the instruments that expose the small and not estrogenized hymen and vagina to the least possible damage and consider the patient's ability to cooperate; in case this is not achieved, examination under anesthesia could be suggested.

"Prepubertal menarche" is an entity defined as an isolated bleeding without signs of puberty and with no identifiable cause, after a complete evaluation. The diagnosis is made by exclusion and following the evolution in time, as studies are generally unrevealing. It is a benign and self-limiting condition that has no effect on subsequent pubertal development, future fertility or final height³

Pinworms in the pediatric gynecological setting

Oxiuriasis or pinworm infestation is an infectious disease caused by *E. vermicularis*, the most common nematode (roundworm) infection in children⁴. The worms, which only parasitize humans, are tapered and of white color; males measure between 2 and 5 mm and females between 8 and 13 mm. It is transmitted by the ingestion of eggs, which are deposited by the

female at the anal margin, either fecal-orally, by self-infestation, contact with fomites or inhalation. Most frequent clinical manifestations are anal, perineal and vulvar pruritus that is exacerbated during night-time. Diagnosis is made by direct visualization of eggs or adults through perianal scotch tape examination ("cellophane test"), which has a sensitivity of 90%⁴. Antiparasitic treatment should include the patient's close contacts due to the high contagiousity of the parasite⁴.

After the deposition of eggs, female pinworms may erroneously invade the urinary tract, genital region or other organs: within the scope of gynecological disease, enterobius have been found in every site of the genital tract: vagina, uterine cervix, uterine body and fallopian tubes⁵. It has also been described as a cause of postmenopausal uterine bleeding⁶. Although being a very common pathogen in childhood and frequently mentioned as a cause of perianal and vulvar itching, enterobiasis is scarcely described as cause of high gynecological infections in the field of pediatric and adolescent gynecology, with the sole exception of pelvic inflammatory disease in postmenarcheal adolescents. In those cases, coinfection with bacteriae was identified (specifically staphylococci and *Escherichia coli*), and therefore antibiotics were added to the antiparasitic therapy^{7 8}. As mentioned before, we found no reports of pinworms as cause of uterine pathology in premenarchal girls.

Conclusions

Enterobiasis -given its frequency and the diversity of its manifestations- should be included in the differential diagnosis of gynecological diseases at any age, whether the cardinal symptom is genital itching, vaginal discharge or abnormal genital bleeding.

As our report shows, pinworms might invade the uterine cavity of girls. Therefore, in prepubertal girls with abnormal genital bleeding, this infection should be included into the differential diagnosis. If pinworm infestation is confirmed (by the cellophane test), antiparasitic treatment with albendazol or mebendazol should be started, and (because of possible bacterial coinfection) concomitant antibiotic therapy covering bacteria usually found on the perineal and genital area should be initiated.

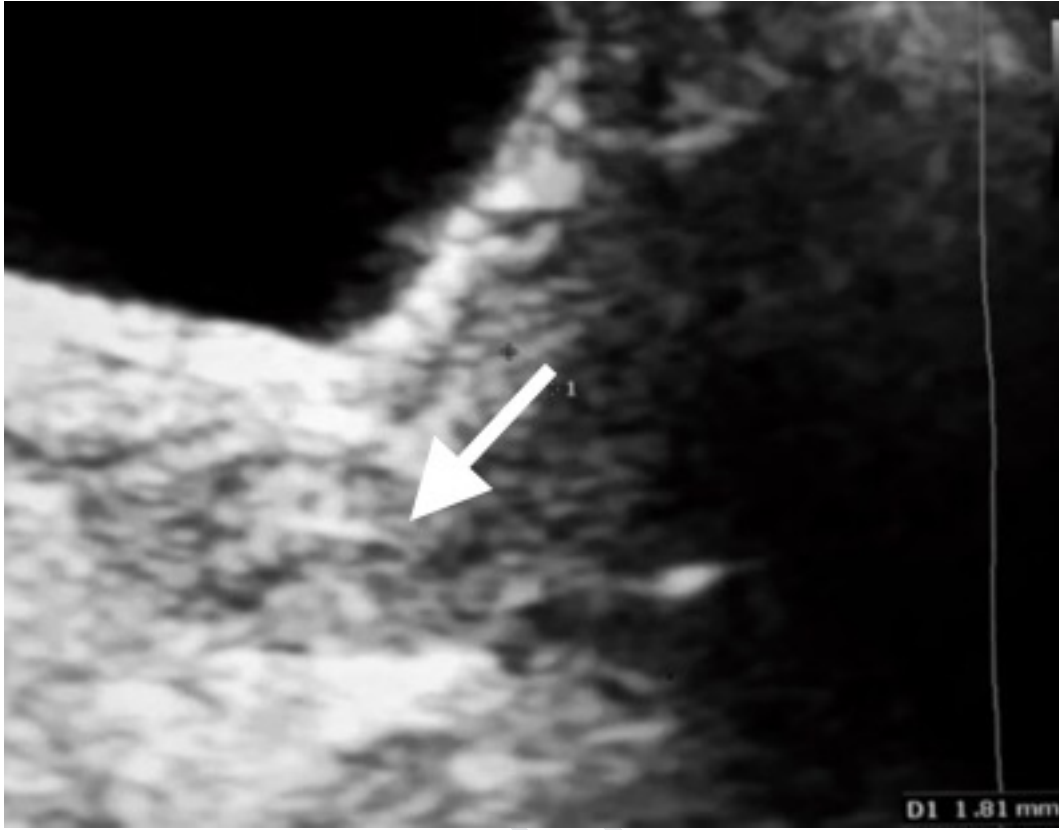DISCLOSURE/CONFLICT OF INTEREST:

The authors report no proprietary or commercial interest in any product mentioned or concept discussed in this article.

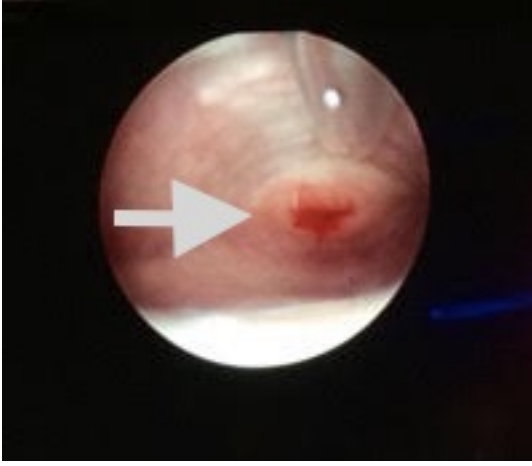Bibliography

1. Martinon Sanchez F, Novoa Gomez G, Gonzalez Gonzalez S MDRM. Hemorragias vaginales prepuberales. Un dilema diagnóstico de etiología múltiple y pronóstico variable. *Rev Española Pediatría*. 2011;67(2):88-98.

2. Mendoza C, Pastene C. Genitorragia En Una Paciente Prepuberal: Reporte De Un Caso Y Su Diagnóstico Diferencial. *Rev la Soc Chil Obstet y Ginecol Infant.* 2015;XXII:11-15.
3. Nella AA, Kaplowitz PB, Ramnitz MS, Nandagopal R. Benign vaginal bleeding in 24 prepubertal patients: clinical, biochemical and imaging features. *J Pediatr Endocrinol Metab.* 2014;27(9-10):821–825. doi:10.1515/jpem-2013-0415
4. Guerrant RL, Walker DH, Weller PF. *Tropical Infectious Diseases.* 3^a. (Guerrant RL, Walker DH, Weller PF, eds.). New York: Elsevier; 2011.
5. López-Olmos J, Gasull J. Enterobius vermicularis (oxiuros) en la práctica ginecológica: clínica y citología. Experiencia de 3 casos. *Clin Invest Ginecol Obstet.* 2011;38(5):197-201. doi:10.1016/j.gine.2010.01.009
6. al-Rufaie HK, Rix GH, Perez Clemente MP, Al-Shawaf T. Pinworms and postmenopausal bleeding. *J Clin Pathol.* 1998;51(5):401-402. doi:10.1136/jcp.51.5.401
7. Mentessidou A, Theocharides C, Patoulis I, Panteli C. Enterobius Vermicularis-Associated Pelvic Inflammatory Disease in a Child. *J Pediatr Adolesc Gynecol.* 2016;29(2):e25-e27. doi:10.1016/j.jpag.2015.10.010
8. Tandan T. Pelvic inflammatory disease associated with Enterobius vermicularis. *Arch Dis Child.* 2002;86(6):439-440. doi:10.1136/adc.86.6.439



Journal Pre-proof



Journal Pre-proof

