

Ultra HD Liposuction: Enhancing Abdominal Etching Using Ultrasound-Guided Rectus Abdominis Fat Transfer (UGRAFT)

Mauricio S. S. Viaro, MD, MSc*
 Stefan Danilla, MD, MSc†
 Alvaro Luiz Cansanção, MD‡
 Paloma Salomone Viaro, MD, MSc*

Background: High-definition (HD) liposuction has allowed surgeons to sculpt the abdomen, enhancing abdominal etching. To create a more athletic abdomen, fat grafting has been used subcutaneously, and rectus abdominis fat grafting has been performed in patients undergoing lipoabdominoplasty. With the objective of increasing muscle volume to obtain a natural-looking abdomen in patients who are not suitable for abdominoplasty, we propose the use of ultrasound-guided rectus abdominis fat grafting (UGRAFT) in association with HD liposuction.

Patients: A prospective study with 10 consecutive patients undergoing UGRAFT was conducted. After HD liposuction, UGRAFT was performed from an incision in the umbilical region, using a blunt 2.5-mm cannula assisted by ultrasound. Fat injection was done closer to the anterior rectus sheath in the lower and middle muscle bellies.

Results: UGRAFT was performed in 10 patients. The mean age was 34.8 years (range, 24–51 years). The mean body mass index was 23.83 kg/m² (range, 20.58–28.39 kg/m²). The mean volume of fat injected per “pack” was 34 cm³ (range, 20–40 cm³). UGRAFT added a mean time of 20 minutes (range, 15–30 minutes) to HD liposuction. Comparing the rectus abdominis muscle thickness pre-UGRAFT and post-UGRAFT, average muscle thickness increase was 5.1 mm (55.7% ± 37%), with $P < 0.0001$.

Conclusion: UGRAFT showed to be helpful for obtaining muscle expansion and a more natural abdominal contour, avoiding that unnatural appearance that HD liposuction may provide in patients who gain weight or have skin laxity. (*Plast Reconstr Surg Glob Open* 2020;8:e2818; doi: 10.1097/GOX.0000000000002818; Published online 26 May 2020.)

BACKGROUND

Liposuction, a leading esthetic procedure worldwide,¹ allows surgeons to improve body contour with few and small scars. One of its variants, named high-definition (HD) liposuction,² has become popular since Hoyos and Millard³ and Hoyos et al⁴ developed a 3-dimensional approach to sculpt not only the abdomen but also other muscle groups,

including chest, legs, arms, and back, and established different outcomes to be achieved in men and women.

To create a more athletic abdomen with a muscular shape, Steinbrech and Sinno⁵ used fat grafting subcutaneously. Danilla⁶ obtained a more natural outcome by performing rectus abdominis fat grafting in patients undergoing lipoabdominoplasty.

With the objective of increasing muscle volume to obtain a natural-looking abdomen in patients who are not suitable for abdominoplasty, we propose the use of ultrasound-guided rectus abdominis fat grafting (UGRAFT) in association with HD liposuction.

PATIENTS AND METHODS

After local ethics committee approval and patient consent were obtained, a prospective study with 10 consecutive

From the *Sa. Vi Medicina, Santa Maria, RS, Brazil; †Department of Plastic and Reconstructive Surgery, University of Chile Clinical Hospital, Santiago, Chile; and ‡Department of Plastic Surgery, Universidade Iguazu (UNIG), Hospital da Plástica, Rio de Janeiro, RJ, Brazil.

Received for publication October 31, 2019; accepted March 17, 2020.

Copyright © 2020 The Authors. Published by Wolters Kluwer Health, Inc. on behalf of The American Society of Plastic Surgeons. This is an open-access article distributed under the terms of the [Creative Commons Attribution-Non Commercial-No Derivatives License 4.0 \(CCBY-NC-ND\)](https://creativecommons.org/licenses/by-nc-nd/4.0/), where it is permissible to download and share the work provided it is properly cited. The work cannot be changed in any way or used commercially without permission from the journal.

DOI: 10.1097/GOX.0000000000002818

Disclosure: The authors have no financial interest to declare in relation to the content of this article.

Related Digital Media are available in the full-text version of the article on www.PRSGlobalOpen.com.

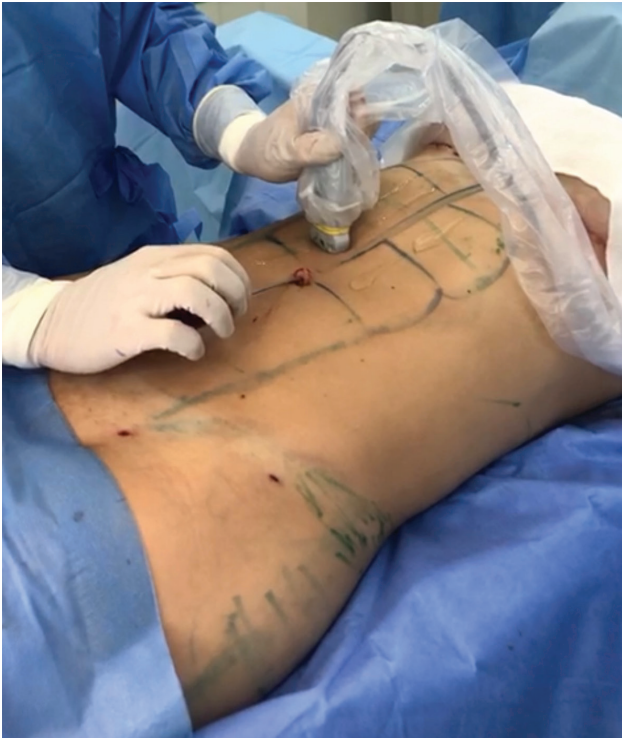

Fig. 1. Surgeon holding an ultrasound probe with the left hand and a cannula with the right hand to perform UGRAFT. The cannula is introduced by an incision in the umbilical region and carefully guided by an ultrasound image until it penetrates the rectus abdominis sheath.

patients undergoing UGRAFT was conducted. Inclusion criteria were Matarasso type 1 patients⁷ without skin laxity, body mass index (BMI) $<26 \text{ kg/m}^2$ for women, and BMI $<28 \text{ kg/m}^2$ for men. Exclusion criteria were presence of skin laxity and age ≤ 18 or ≥ 60 years.

Areas of superficial and deep liposuction (midline, semilunar lines, subcostal triangle, semilunar triangles, suboblique triangles, and tendinous intersections) were marked with assistance of ultrasound image to achieve greater precision in terms of muscular anatomy (see figure, [Supplemental Digital Content 1](http://links.lww.com/PRSGO/B380), which displays marked areas of superficial and deep liposuction in the abdomen, <http://links.lww.com/PRSGO/B380>).

General anesthesia was administered to all patients. Subcutaneous infiltration was performed with a solution of normal saline and epinephrine at 1:1,000,000, according to the super-wet technique. After 15 minutes, suction-assisted liposuction was initiated using a blunt 4-mm Mercedes cannula, limited to 80 cm Hg. Superficial liposuction was used for abdominal sculpting, followed by deep liposuction according to each patient's needs. The aspirated fat was collected in a closed system, processed by decantation for 15 minutes, and then placed in 60-cc Luer-lock syringes for injection.

UGRAFT was the last step in the surgical procedure. From an incision in the umbilical region, perforation of the anterior rectus sheath was performed observing the previously demarcated tendinous intersections, using a blunt

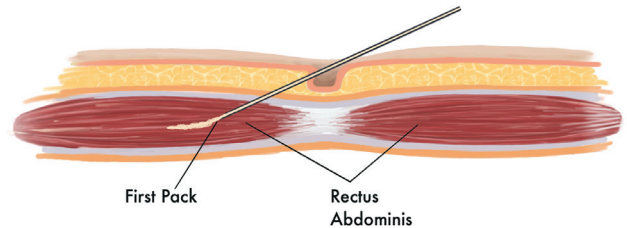


Fig. 2. Schematic figure demonstrating the UGRAFT. A cannula is introduced by an incision in the umbilical region and, under very careful ultrasound-guided movement, penetrates the rectus abdominis anterior sheath. An intramuscular bolus injection was performed closer to the anterior rectus sheath in the lower and middle “packs.”

2.5-mm cannula guided by a L25x 13–6 MHz linear-array transducer (Fujifilm SonoSite Inc., Bothell, Wash.) with transverse view (Fig. 1). An intramuscular bolus fat injection was administered closer to the anterior rectus sheath in the lower and middle muscle bellies (“packs”) (Fig. 2).

Fat was evenly distributed over the muscle fibers, causing anteroposterior muscle expansion. (See Video 1 [online], which displays how UGRAFT is performed. The surgeon holds an ultrasound probe with the left hand and a cannula with the right hand. The cannula is introduced by an incision in the umbilical region and carefully guided by an ultrasound image until it penetrates the rectus abdominis sheath. Fat is then injected intramuscularly, as bolus, and placed just below the muscle sheath. Muscle expansion is clearly observed in the real-time image.) The thickness of each injected pack was measured with ultrasound at the midpoint of each muscular belly, at an equidistant point from each tendon intersection, before and after UGRAFT. A paired *t* test was used for statistical analysis.

RESULTS

UGRAFT was performed in 10 patients (2 men and 8 women) from April to July 2019. The mean age was 34.8 years (range, 24–51 years). The mean BMI was 23.83 kg/m^2 (range, $20.58\text{--}28.39 \text{ kg/m}^2$) (see table, [Supplemental Digital Content 2](http://links.lww.com/PRSGO/B381), which displays patient characteristics, <http://links.lww.com/PRSGO/B381>). Most patients were classified as “6-pack” (90%). The mean volume of fat injected per pack was 34 cm^3 (range, $20\text{--}40 \text{ cm}^3$). UGRAFT added a mean time of 20 minutes (range, 15–30 minutes) to HD liposuction (Fig. 3) [see figure, [Supplemental Digital Content 3](http://links.lww.com/PRSGO/B382), which displays a 36-year-old female patient classified as “4-pack” and Matarasso type 1 (BMI = 25.17 kg/m^2) undergoing HD liposuction with UGRAFT. Twenty milliliters of fat was injected into each of the inferior and middle packs. A, Preoperative view. B, Postoperative view, <http://links.lww.com/PRSGO/B382>] [see figure, [Supplemental Digital Content 4](http://links.lww.com/PRSGO/B383), which displays a 32-year-old female patient classified as 6-pack and Matarasso type 1 (BMI = 20.58 kg/m^2) undergoing HD liposuction with UGRAFT. Thirty milliliters of fat was injected into each of the inferior and middle packs. A, Preoperative view. B, Postoperative view, <http://links.lww.com/PRSGO/B383>].

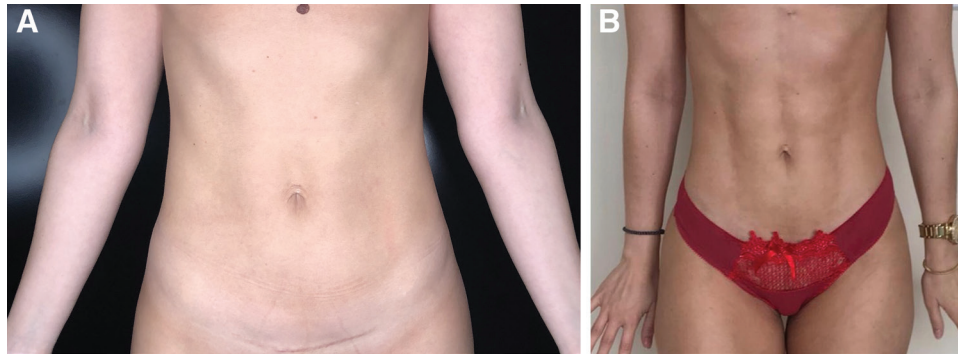


Fig. 3. A 33-year-old female patient classified as “6-pack” and Matarasso type 1 (body mass index = 21.3 kg/m²) undergoing high-definition liposuction with UGRAFT. Thirty milliliter of fat was injected into each of the inferior and middle “packs.” A, Preoperative view. B, Postoperative view.

Comparing the rectus abdominis muscle thickness pre-UGRAFT (mean, 1.15 cm) and post-UGRAFT (mean, 1.70 mm), we observed an average muscle thickness increase of 5.1 mm (55.7% ± 37%), $P < 0.0001$. No complications were observed in this series.

DISCUSSION

HD liposuction has become a reliable procedure providing a more athletic outcome, being a major trend among plastic surgeons and patients. Despite its popularity, this technique has some disadvantages such as delivering an unnatural abdominal shape obtained by a thicker subcutaneous tissue, not by muscle expansion. In cases of skin laxity or weight gain, patients may exhibit an unnatural look.

The rectus abdominis fat grafting technique, in which fat graft is introduced into the rectus abdominis muscle under direct visualization during lipoabdominoplasty, can be used to obtain a more natural abdominal contour.^{6,8} However, it is suitable only for those patients who have skin laxity undergoing abdominoplasty.

The UGRAFT technique has expanded the range of patients who can benefit from rectus abdominis fat grafting, including those without skin laxity. Its advantage over HD liposuction alone is a more natural outcome because it increases muscle thickness and provides a sculpted abdomen even during movements regardless of patient’s position. (See Video 2 [online], which displays 3-month postoperative outcomes of a patient who underwent the UGRAFT technique with 30 mL of fat injected into each of the inferior and middle packs, showing a natural look even during movements.)

To our knowledge, this is the first study to describe ultrasound-guided fat injection into the rectus abdominis muscle. However, ultrasound-guided fat grafting has already been used subcutaneously in the gluteal region⁹ and intramuscularly in the biceps and triceps.¹⁰ Additionally, its safety in fat grafting procedures has already been demonstrated.⁹

The rectus abdominis muscle is a type 3 Mathes–Nahai muscle that receives blood supply from the inferior epigastric artery (dominant pedicle) and the superior epigastric

artery, which run posteriorly to the muscle, close to the posterior rectus sheath. Fat injection was administered below the anterior rectus sheath, avoiding a posterior approach to the muscle. The bolus injection technique was chosen because during fat injection into the rectus abdominis muscle, the ultrasound image becomes blurred by the fat; then, if we keep the cannula in motion, we might introduce it in an unwanted plane, leading to serious complications.

The possibility of fat embolism is currently the greatest fear of surgeons who wish to add UGRAFT to their surgical arsenal due to the recent cases of death from fat embolism in intramuscular gluteal fat grafting. For this reason, it is extremely important to clarify that the gluteal region has specific characteristics that make it more favorable to the occurrence of fat embolism when fat is injected intramuscularly. The gluteus maximus muscle is irrigated by the superior and inferior gluteal vessels, which are large veins that run directly into the internal iliac vein. The inferior gluteal vein is actually almost a continuation of the internal iliac vein, so any fat particle that may penetrate the blood system has a direct path to the heart, facilitating the occurrence of fat embolism. These anatomic characteristics observed in the gluteal region are not present in the rectus abdominis muscle, where the epigastric vessels are thin and long. This long venous path through a thin-caliber vessel makes it difficult for fat lobes to migrate through it to the lung. Therefore we consider that the risk of fat embolism, although unlikely to occur, exists. As there is in fat grafting into any other area, such as face, breast, pectoralis major, deltoid, biceps, triceps, and latissimus dorsi muscles.^{11–13} However, it cannot be compared with the risk of fat embolism in intramuscular gluteal fat grafting. Disadvantages of the UGRAFT technique include the need of an ultrasound device in the operating room and a learning curve for surgeons, who must be familiar with ultrasound-assisted procedures.

Some limitations of the present study are the small number of patients included and the short-term patient follow-up. Nevertheless, long-term fat grafting retention has already been demonstrated in the face,¹⁴ buttocks,¹⁵ and the rectus abdominis muscle.¹⁶

CONCLUSIONS

The UGRAFT technique can be used to obtain muscle expansion and a more natural abdominal contour in patients who desire an athletic look. The technique improves abdominal shape in selected patients, avoiding that unnatural appearance that HD liposuction may provide in patients who gain weight or have skin laxity.

Mauricio S. S. Viaro, MD, MSc
Avenida Presidente Vargas 2084, Sala 1301
97015-510 – Santa Maria, RS, Brazil
E-mail: msviaro@hotmail.com

ACKNOWLEDGMENTS

We acknowledge that Dr. Guillermo Blugerman, plastic surgeon from Argentina, performed the first ultrasound-guided rectus fat transfer. He had the idea in a conversation with Dr. Stefan Danilla. This study was approved by the ethics committee.

REFERENCES

1. International Society of Aesthetic Plastic Surgery. ISAPS international survey on aesthetic/cosmetic procedures performed in 2017. Available at https://www.isaps.org/wp-content/uploads/2018/10/2017-Global-Survey-Press-Release-Demand-for-Cosmetic-Surgery-Procedures-Around-The-World-Continues-To-Skyrocket_2_RW.pdf. Accessed September 15, 2019
2. Mentz HA III, Gilliland MD, Patronella CK. Abdominal etching: differential liposuction to detail abdominal musculature. *Aesthetic Plast Surg*. 1993;17:287–290.
3. Hoyos AE, Millard JA. VASER-assisted high-definition liposculpture. *Aesthet Surg J*. 2007;27:594–604.
4. Hoyos AE, Perez ME, Castillo L. Dynamic definition mini-lipoabdominoplasty combining multilayer liposculpture, fat grafting, and muscular plication. *Aesthet Surg J*. 2013;33:545–560.
5. Steinbrech DS, Sinno S. Utilizing the power of fat grafting to obtain a naturally-appearing muscular “6-pack” abdomen. *Aesthet Surg J*. 2016;36:1085–1088.
6. Danilla S. Rectus Abdominis Fat Transfer (RAFT) in lipoabdominoplasty: a new technique to achieve fitness body contour in patients that require tummy tuck. *Aesthetic Plast Surg*. 2017;41:1389–1399.
7. Matarasso A, Matarasso DM, Matarasso EJ. Abdominoplasty: classic principles and technique. *Clin Plast Surg*. 2014;41:655–672.
8. Danilla-Enei S, Domínguez-Contreras C, Cueno-Barbosa N, et al. Variation in the number of metamers of rectus abdominis muscle. A high definition lipoesculture guide. *Cir Plást Iberolatinoam*. 2018;44:13–17.
9. Cansancao AL, Condé-Green A, Vidigal RA, et al. Real-time ultrasound-assisted gluteal fat grafting. *Plast Reconstr Surg*. 2018;142:372–376.
10. Matlock D, Simopoulos A. Sonographic evaluation of autologous fat transfer to the biceps and triceps. *Surg Technol Int*. 2014;25:289–295.
11. Streit L, Dražan L, Schneiderová M, et al. Intraoperative fat grafting into the pectoralis and latissimus dorsi muscles—novel modification of autologous breast reconstruction with extended latissimus dorsi flap. *Acta Chir Plast*. 2017;59:72–81.
12. Hoyos A, Perez M. Arm dynamic definition by liposculpture and fat grafting. *Aesthet Surg J*. 2012;32:974–987.
13. Hoyos A, Perez M. Dynamic-definition male pectoral reshaping and enhancement in slim, athletic, obese, and gynecomastic patients through selective fat removal and grafting. *Aesthetic Plast Surg*. 2012;36:1066–1077.
14. Fontdevila J, Guisantes E, Martínez E, et al. Double-blind clinical trial to compare autologous fat grafts versus autologous fat grafts with PDGF: no effect of PDGF. *Plast Reconstr Surg*. 2014;134:219e–230e.
15. Cansancao AL, Condé-Green A, David JA, et al. Subcutaneous-only gluteal fat grafting: a prospective study of the long-term results with ultrasound analysis. *Plast Reconstr Surg*. 2019;143:447–451.
16. Danilla S. RAFT “Stepwise Approach for High End Body Contouring.” Oral communication presented at: 39th Jornada Paulista de Cirurgia Plástica. São Paulo, Brazil; June 21, 2019.